

2013

Characterization, prevalence, and risk factors of spontaneous and experimental atherosclerosis and vascular imaging in psittaciformes

Hugues Beaufrère

Louisiana State University and Agricultural and Mechanical College

Follow this and additional works at: https://digitalcommons.lsu.edu/gradschool_dissertations



Part of the [Veterinary Medicine Commons](#)

Recommended Citation

Beaufrère, Hugues, "Characterization, prevalence, and risk factors of spontaneous and experimental atherosclerosis and vascular imaging in psittaciformes" (2013). *LSU Doctoral Dissertations*. 1598.
https://digitalcommons.lsu.edu/gradschool_dissertations/1598

This Dissertation is brought to you for free and open access by the Graduate School at LSU Digital Commons. It has been accepted for inclusion in LSU Doctoral Dissertations by an authorized graduate school editor of LSU Digital Commons. For more information, please contact gradetd@lsu.edu.

CHARACTERIZATION, PREVALENCE, AND RISK FACTORS OF SPONTANEOUS
AND EXPERIMENTAL ATHEROSCLEROSIS AND VASCULAR IMAGING IN
PSITTACIFORMES

A Dissertation

Submitted to the Graduate Faculty of the
Louisiana State University and
Agricultural and Mechanical College
in partial fulfillment of the
requirements for the degree of
Doctor of Philosophy

in

The Department of Veterinary Clinical Sciences

by
Hugues Beaufrère
Dr.Med.Vet., University of Lyon, France, 2006
Diplomate ABVP – Avian Practice, 2012
Diplomate ECZM (Avian), 2012
May 2013

A Mélanie, qui élève mon cœur.

ACKNOWLEDGEMENTS

First and foremost, I would like to express my thanks to my mentors, Drs. Thomas Tully and Javier Nevarez. Their help, guidance, and trust were instrumental in the completion of my program and these research projects. They promoted unique opportunities at LSU that were far beyond what was just required to succeed in this program. My time within the Zoological Medicine Service will always be remembered as a pivotal point in all my accomplishments.

I would like to express my deepest gratitude to Dr. Tully who believed in me from early on when I was just a veterinary student. Dr. Tully consistently demonstrated that science was about sharing and collaborating and this, in combination with his continuous support and mentorship, shaped my vision of learning and teaching avian medicine.

I would like to recognize Dr. Nevarez for his constant assistance and for putting me back on the right track when I was “slightly” diverging from initial plans. He managed somehow to insufflate the rigor and meticulousness necessary to all scientific work into my innate sense of chaos.

My sincere appreciations also go to the other members of my committee. Dr. Romain Pariaut who was always ready for a new avian cardiologic adventure and whom I consider not only as the transesophageal ultrasound probe bearer, but also as a friend. We are grateful to Dr. Nobuko Wakamatsu who assisted in histopathological interpretation and who was always available when needed. It was a pleasure to work with her. I would like to thank Dr. Heatley for sharing research resources and findings with me and participating in this committee. I would also like to acknowledge the help and teaching of Dr. Brian Marx who contributed to anchoring in me a strong interest in applied biostatistics, a valuable skill that served me well during my studies even if I could never be confident to be right 95% of the time.

Furthermore, I would like to acknowledge the help of all my other co-authors, Dr. Daniel Rodriguez for having performed close to 1700 imaging measurements for my studies, Dr. Lorrie Gaschen for her trust in my CT project and for her assistance, Dr. Drury Reavill for having sent me a countless number of pathology slides in a timely fashion, Dr. Michael Garner for having received me in his house and given me access to his histopathology slides database, Dr. Carolyn Cray for having provided clinical pathology support, Dr. Susan Clubb for having supplied the Quaker parrots, Dr. Kali Holder for her assistance in the atherosclerosis classification study, and Dr. Mélanie Ammersbach, my wife, who managed somehow to squeeze her name in one of my PhD publications and actually gave me the idea for my epidemiological study.

In addition, I would like to thank our funding sources without which none of this research would have been possible. The Department of Veterinary Clinical Sciences funded the largest part of these studies and we are thankful to all its members for supporting psittacine cardiovascular research and graduate students at LSU. We are also extremely grateful to the Kaytee Avian Foundation, Mr. Rich Bonkowski, and Dr. Randal Brue for their invaluable help with the dietary aspect of our atherosclerosis model study and for supporting the LSU Hispaniolan Amazon parrot colony. We recognize the financial support of the South Alabama Bird Club that provided funds necessary to the completion of our CT study.

Finally, I would like to thank my family and particularly my parents who supported me unconditionally throughout my veterinary studies and post-graduate training. Without them, I would be like a bird without wings.

TABLE OF CONTENTS

ACKNOWLEDGEMENTS	iii
ABSTRACT	vii
INTRODUCTION	1
LITERATURE REVIEW	3
I. Avian cardiology	3
A. Anatomy and physiology of the avian cardiovascular system	3
B. Diagnostic techniques	7
C. Cardiovascular diseases of birds (other than atherosclerosis)	22
II. Atherosclerosis in mammals	38
A. Pathogenesis	38
B. Atherosclerotic lesions	44
C. Risk factors for atherosclerotic vascular disease	47
D. Diagnostic techniques	51
E. Medical management and treatment	53
F. Mammal models of atherosclerosis	56
III. Avian atherosclerosis	60
A. Peculiarities of avian lipoprotein metabolism	60
B. Avian models of atherosclerosis	61
C. Psittacine atherosclerosis	63
D. Atherosclerosis in non-domestic avian species	73
CHAPTER I: CHARACTERIZATION AND CLASSIFICATION OF PSITTACINE ATHEROSCLEROTIC LESIONS BY HISTOPATHOLOGY, DIGITAL IMAGE ANALYSIS, TRANSMISSION AND SCANNING ELECTRON MICROSCOPY	76
I. Introduction	76
II. Materials and methods	78
A. Sample collection	78
B. Histopathology	78
C. Digital image analysis	79
D. Transmission and scanning electron microscopy	80
E. Classification of atherosclerotic lesions	81
F. Statistical analysis	81
III. Results	81
A. The normal intima and arterial wall	85
B. Type I lesions	86
C. Type II lesions	86
D. Type III lesions	87
E. Advanced lesions: type IV and type V lesions	87
F. Complicated lesions: type VI lesions	88

G. Type VII lesions.....	88
IV. Discussion	95
CHAPTER II: PREVALENCE AND RISK FACTORS IN PSITTACINE ATHEROSCLEROSIS: A MULTICENTER CASE-CONTROL STUDY.....	99
I. Introduction	99
II. Materials and methods	101
A. Study design and case-control selection	101
B. Statistical analysis	101
III. Results	103
IV. Discussion	109
CHAPTER III: EXPERIMENTAL DIET-INDUCED ATHEROSCLEROSIS IN QUAKER PARROTS (<i>MYIOPSITTA MONACHUS</i>)	113
I. Introduction	113
II. Materials and methods	114
A. Experimental design	114
B. Sample collection and analysis	115
C. Statistical analysis	116
III. Results	117
IV. Discussion	124
CHAPTER IV: ESTIMATION OF INTRATHORACIC ARTERIAL DIAMETER BY MEANS OF COMPUTED TOMOGRAPHY ANGIOGRAPHY IN HISPANIOLAN AMAZON PARROTS (<i>AMAZONA VENTRALIS</i>)	128
I. Introduction	128
II. Materials and methods	129
A. Animals.....	129
B. Cardiological evaluation	129
C. CTA procedures	129
D. ROI measurements.....	130
E. Statistical analysis	131
III. Results	132
A. Cardiological evaluation.....	132
B. CTA.....	133
C. ROI measurements	133
IV. Discussion	137
CONCLUSION	140
REFERENCES.....	142
APPENDIX 1: LETTER OF PERMISSION FROM AVIAN PATHOLOGY	177

APPENDIX 2: LETTER OF PERMISSION FROM THE AMERICAN VETERINARY MEDICAL ASSOCIATION	178
APPENDIX 3: LETTER OF PERMISSION FROM VETERINARY PATHOLOGY	179
VITA	180

ABSTRACT

Atherosclerosis is a degenerative and inflammatory vascular disease characterized by the accumulation of inflammatory cells, lipids, calcium, and formation of large fibrofatty lesions within the intima of arteries resulting in the disorganization of the arterial wall and stenosis of the lumen. Despite the importance of atherosclerosis in psittacine cardiology, there are few pathologic, clinical, and experimental investigations in psittaciformes.

In order to expand the knowledge on psittacine atherosclerosis and provide fundamental observational information for future research, a series of studies was conducted on psittaciformes: 1) psittacine atherosclerotic lesions were characterized and categorized based on histopathology, histochemistry, transmission (TEM), and scanning electron microscopy (SEM) of 63 arterial samples, 2) the prevalence of clinically significant atherosclerotic lesions and the influence of several epidemiological variables were investigated in a multi-center case-control study on 7683 psittaciformes, 3) a diet-induced experimental model of atherosclerosis was developed and characterized in Quaker parrots (*Myiopsitta monachus*), and 4) a computed-tomography angiographic (CTA) protocol was developed and standardized to image the arterial lumen in Hispaniolan Amazon parrots (*Amazona ventralis*).

Seven lesion types could be described in psittaciformes, which were similar to the human classification system. Digital image analysis, TEM, and SEM helped to further describe the lesions and refine the classification system. Atherosclerosis prevalence significantly increased with age, female sex, and the genera *Psittacus*, *Amazona*, and *Nymphicus*. Mild associations with reproductive, hepatic diseases, and myocardial fibrosis were also evidenced. Experimental induction of atherosclerosis with dietary 1% cholesterol lead to significant lesions within 2 months in Quaker parrots. An increase in arterial and plasma cholesterol and LDL was also documented. Reference limits for arterial luminal diameter of Hispaniolan Amazon parrots were determined by CTA and measurements revealed high intraobserver and interobserver agreement.

In conclusion, psittacine atherosclerotic lesions displayed distinctive features that allowed the development of an effective classification system. The prevalence of advanced lesions (type IV-VI) was associated with several risk factors: age, female sex, and three psittacine genera. The Quaker parrot was found to be a suitable experimental model for psittacine atherosclerosis and dyslipidemia. Finally CTA was determined to be safe, reliable, and of potential diagnostic value in parrots for diagnosing stenotic atherosclerotic lesions.

INTRODUCTION

Atherosclerosis is the leading cause of human deaths in the world and its clinical manifestations include coronary heart disease, ischemic stroke, and peripheral arterial disease.(WHO 2012; WHO 2011) Likewise, atherosclerosis appears to be common in psittaciformes maintained in captivity, leads to clinical signs, and appears to be a significant cause of mortality in older birds.(Bavelaar, 2004a)

According to the American Veterinary Medical Association (AVMA), 10.1 million birds are kept as pets in the United States and generate 2 million veterinary visits per year.(AVMA 2002) Numerous parrots are also displayed in zoological collections because of their bright colors and playful behavior. The International Union for Conservation of Nature (IUCN) reports that psittaciformes are one of the most endangered groups of birds in the world with 28% of the species considered threatened with extinction in their native environment.(Snyder et al. 2000) In addition, research on African grey parrots (*Psittacus erithacus*) has demonstrated that parrots are among the animals with the greatest cognitive abilities.(Pepperberg 2002) For all these reasons, humans have a responsibility to ensure that captive parrots are provided living conditions promoting healthy habits, long lifespans and preventing chronic medical conditions associated with captivity. Atherosclerosis is connected to a sedentary lifestyle and improper dietary habits in humans. Psittacine atherosclerosis is likely to share these factors, which are also commonly encountered in captive animals.

Atherosclerotic lesions develop slowly over decades and psittaciformes have long lifespans and varied nutrition. Despite the impact of atherosclerosis on psittaciformes health and the fact that it appears to be one of the most prevalent diseases of aging birds, research investigations have been scarce and only basic information is known about the disease in these species. There is an urgent need for research to provide epidemiological and pathophysiological basis for implementing more effective diagnostic, therapeutic, and preventative measures in avian species. Furthermore, considering the importance of the disease in humans, research investigations on psittacine atherosclerosis may lead to useful comparative pathologic findings.

The current knowledge of psittacine atherosclerosis is restricted to pathologic surveys, rough prevalence estimations, and case reports. There is no standardization or homogeneity of techniques on lesion grading that could help foster further research. The available information is confounded by lack of consistent methodology and conflicting data: the reported prevalence varies between 1.9 and 91.8%, authors do not agree on risk factors alternatively citing each gender as predisposed, studies do not control for confounding factors, and much knowledge is extrapolated from distant species with a significant taxonomy and ecological gap such as humans. There are no diagnostic methods or screening markers that have been established as useful and much diagnostic information is speculative. Experimental research is impaired by this inconsistency and by the lack of animal models to test psittaciformes-specific research hypothesis.

The goal of our work was to fill this gap of knowledge in psittacine atherosclerosis research, so that the elementary characteristics of the disease in psittaciformes could be understood better. We also wanted to stimulate research in this area by providing fundamental observational information and developing an animal model. The first step in fulfilling these goals was to thoroughly describe the psittacine atherosclerotic lesions and derive a classification system based on pathologic and ultrastructural criteria. This classification scheme was then used to determine the prevalence and risk factors of clinically significant atherosclerotic lesions, as surrogates of

atherosclerotic diseases, in one of the largest retrospective studies ever conducted on psittaciformes. An experimental model of diet-induced atherosclerosis was then established and characterized in Quaker parrots (*Myiopsitta monachus*) and the induced lesions were compared with the spontaneous disease using the same classification system. Finally, since arterial luminal narrowing consecutive to atherosclerosis was found to be the primary cause of clinical signs in psittacine birds, we undertook a diagnostic imaging study in which a computed-tomography angiographic protocol was described and standardized for use in psittacines.

Our research was driven by the following hypotheses:

- Atherosclerotic lesions have similar pathologic organization in psittacines than humans and the classification system endorsed by the American Heart Association applies to psittacine lesions.

- The prevalence of atherosclerosis increases with age and some psittacine species show increased susceptibility.

- Myocardial, hepatic, and reproductive diseases are significantly associated with the presence of advanced atherosclerotic lesions.

- Advanced atherosclerosis and dyslipidemia can be induced using dietary cholesterol in Quaker parrots and mirror spontaneous disease in the same species.

- A CT angiographic protocol can be standardized and shows good reliability in measurements of arterial luminal diameter, which could be used to evaluate clinical cases of atherosclerosis.

LITERATURE REVIEW

I. Avian Cardiology

A. Anatomy and physiology of the avian cardiovascular system

i. Heart

All birds have a four-chambered heart with complete separation of the pulmonary and systemic circulation. The major anatomical differences of the avian cardiovascular system from its mammalian counterparts are summarized in Table 1.

Table 1: Some avian cardiovascular anatomical and physiological peculiarities which differ from mammals. AV: atrioventricular.(Smith et al. 2000; Lumeij & Ritchie 1994; Fletcher & Abdul-Aziz 2008; Baumel 1993; King & McLelland 1984)

Avian cardiovascular system peculiarities
Muscular unicuspid right AV valve
No chordae tendineae in the right AV valve
Tricuspid (poorly defined) left AV valve
Muscular ring around aortic valve
Negative cardiac mean electrical axis (except broilers, Pekin ducks)
Ring of Purkinje fibers around aorta and right AV valve
Depolarization of epicardium precedes endocardium
Higher stroke volume, arterial blood pressure, cardiac output, lower total peripheral resistance
Larger heart proportionally
Smaller cardiac muscle fibers
Absence of T-tubules in cardiac myocytes
Absence of M-bands connecting myosin filaments
Ascending aorta on the right
Two cranial vena cava
Brachiocephalic arteries larger than aorta
Cartilage/ossification at base of aorta
Most of myocardium vascularization derived from deep arteries
No cerebral arterial circle of Willis
Renal portal system

Birds have a much larger heart than mammals that scales to the body mass as $M_{\text{heart}} = 0.014 \times M_{\text{bird}}^{0.91}$. They also have proportionally a higher stroke volume, mean arterial blood pressure, and cardiac output than mammals to enable them to meet their higher metabolic requirements. Birds have the fastest heart rate of any animals but it can actually be lower than mammals of similar body weight. The heart rate can increase 2 to 4 times during flight.(Smith et al. 2000; Maina 1996) It is located in the cranial thorax and lies ventrally in a concave indentation of the keel bone, the *fascies visceralis sterni pars cardiac*.(Baumel 1993) The heart is partially enclosed laterally and dorsally by the cranial part of the liver, not the lungs as in mammals, which are

located dorsally in birds.(Smith et al. 2000; King & McLelland 1984) The heart rests dorsally against the bifurcation of the trachea (syrinx), the esophagus, and the horizontal septum on each side. It is surrounded by the cervical airsacs and interclavicular airsac cranially (and ventrally through a diverticulum that raises the pericardium in some species) and the cranial thoracic airsacs laterally.(Nickel et al. 1977)

The heart is located in the pericardial cavity, which is delimited by the pericardium and contains a small volume of serous fluid that acts as a lubricant during the cardiac cycle. The pericardial cavity protrudes into the hepatoperitoneal cavities. The pericardial sac is attached to the sternum ventrally and laterally, to the hilus of the lungs and the horizontal septum dorsally to which it is fused, to the oblique septum laterally, and to the liver caudally by the hepatopericardial ligament.(McLelland 1993; Smith et al. 2000; Duncker 1979) The hepatopericardial ligament is a doubled layer sheet that is continuous to the ventral mesentery caudally.(McLelland 1993) The fibrous layer of the pericardium is also continuous to the adventitia of the large blood vessels cranially.(Smith et al. 2000; Nickel et al. 1977) The pericardial sac is noncompliant.

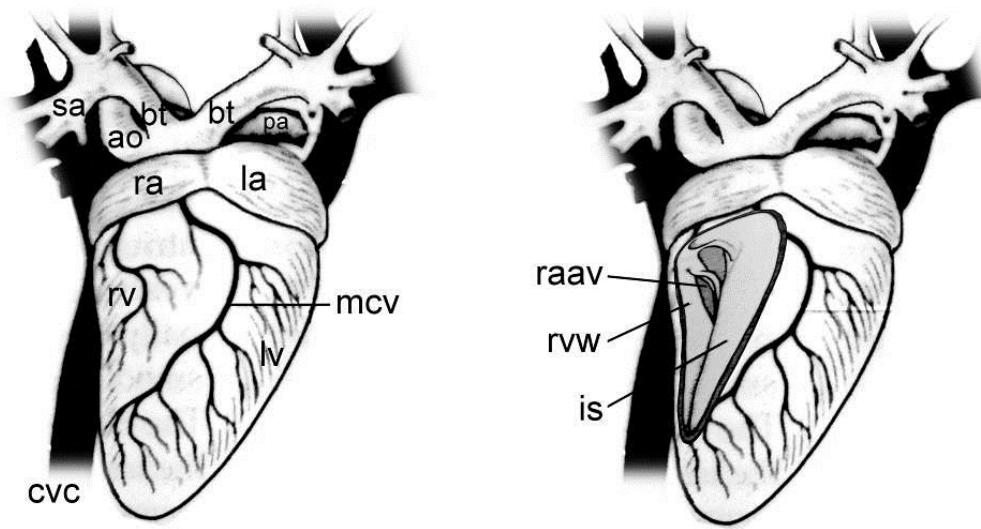


Figure 1: Anatomical drawing of the avian heart. Right, the right ventricle is open. Sa, subclavian artery; bt, brachiocephalic trunks; pa, pulmonary arteries; ao, aorta; ra, right atrium; la, left atrium; rv, right ventricle; lv, left ventricle; mcv, middle cardiac vein; cvc, caudal vena cava; raav, right atrioventricular valve; rvw, right ventricular wall; is, interventricular septum.

The avian cardiac chambers are functionally equivalent to their mammalian counterparts with two atria and two ventricles composed of the endocardium, myocardium, and epicardium. In some species (e.g. chickens, crows, ostriches, kiwis), a *sinus venosus* is present prior to the right atrium and not fully incorporated into its wall and presents a thin sinoatrial valve composed of two valvules. It received blood from the caudal *vena cava* and the right cranial *vena cava* and is separated from the opening of the left cranial *vena cava* by the *septum sinus venosi*.(Baumel 1993; King & McLelland 1984) The right atrium is generally larger than the left and possesses a tubular recess (*recessus sinister atrii dextri*) which extends to the left dorsally to the aortic root.(Baumel 1993; West et al. 1981) The left and right pulmonary veins open into the left atrium either separately or combined in a common pulmonary vein outside the heart. In the left atrium,

the veins coalesce in a single vessel whose opening protrudes into the left atrium (pulmonary chamber) and is guarded by the valve of the pulmonary vein.(Baumel 1993; King & McLelland 1984) The atrial muscle is composed of muscular bundles. The atria are separated from the ventricles externally by the coronary groove filled with fat and the main coronary arteries. They are separated internally by fibrous rings which are well developed at the origin of the aorta, pulmonary artery, and right atrioventricular orifice.(Nickel et al. 1977) A cardiac cartilage, sometimes mineralized, is present in the fibrous rings around the aorta and the pulmonary arteries.(Nickel et al. 1977) The cone-shaped left ventricle extends to the apex of the heart and its right wall forms the interventricular septum. The right ventricle wraps around the left ventricle (at least one half of it) forming a crescent-shaped cavity and does not reach the apex (Figure 1). The wall of the left ventricle is about 2-3 times thicker and is able to generate 4-5 times higher systolic pressure than the right.(Smith et al. 2000; King & McLelland 1984) The right atrioventricular valve is unique to birds and is a triangular muscular flap formed of both atrial and ventricular musculature (Figure 1). This valve is also connected to the roof of the right ventricle by a muscle bundle and to the interventricular septum by a small and narrow membrane.(Baumel 1993; Nickel et al. 1977) The mechanisms of the avian right atrioventricular valve closure are poorly understood and is probably partially active.(Smith et al. 2000) The left atrioventricular valve is a tricuspid valve with poorly defined cusps attached by *chordae tendinae* to the three left ventricular papillary muscles.(Nickel et al. 1977; Smith et al. 2000) The aortic valve located at the root of the ascending aorta also has three cusps and is apparent externally by the *bulbus aortae* where, in contrast with mammals, a complete sphincter-like ring of muscular tissue is present that may regulate outflow by contraction.(Baumel 1993; Smith et al. 2000) The pulmonary valve is tricuspid. Avian cardiomyocytes are smaller than their mammalian counterparts, lack the T-tubules which are invaginations of the sarcolemma, and lack M-band that connects myosin filaments.(Smith et al. 2000) The physiological significance of these differences on the conduction velocity or the contractile properties of the avian cardiomyocytes is poorly understood.

Two coronary arteries, the left and right, provide the arterial supply to the heart. Each branch into 2 vessels (superficial and deep) near their origin. The superficial vessel is located in the coronary groove. Most of the avian cardiac coronary vascularization is provided through the deep rather than the superficial arteries.(Baumel 1993; Nickel et al. 1977; Smith et al. 2000; King & McLelland 1984) The right coronary artery is the largest in most avian species and the coronary arteries anastomose frequently.(Smith et al. 2000) Blood is returned to the right ventricle through several cardiac veins for which the middle cardiac vein and the left circumflex cardiac vein are the largest.

The avian cardiac conduction system is, similar to mammals, composed of a sinoatrial node, atrioventricular node, right atrioventricular ring (specific to birds), and Purkinje fibers (bundle of His, bundle branches). The role of the electrical system of the heart is to maintain an adequate heart rate and coordinate contraction of each cardiac chamber. The sinoatrial node, the pacemaker, is located between the right cranial *vena cava* and the caudal *vena cava* openings into the right atrium.(Lumeij & Ritchie 1994; Smith et al. 2000) The atrioventricular node seems to be located at the base of the interatrial septum and serves to transmit electrical activity from the atria to the ventricles and delay ventricular contraction. Right and left ventricular bundle branches composed of Purkinje fibers run the length of the interventricular septum in the subendocardium and penetrate the myocardium along the coronary arteries. In birds, an atrioventricular ring of Purkinje fibers is present around the right atrioventricular valve and

around the aorta in a figure eight and connected to the atrioventricular node.(Smith et al. 2000) The heart is innervated by both the sympathetic and parasympathetic autonomic system through the cardiac sympathetic nerve and the vagal nerve, respectively and is controlled by catecholamine release. (see section on electrocardiogram for additional information on electrophysiology)

ii. Vessels

In birds, the aorta curves to the right and derives from the right fourth aortic arch as opposed to mammals where it comes from the left. The coronary arteries are the first to branch from the aorta followed by the brachiocephalic trunks. These trunks supply the large flight muscles through the subclavian arteries, therefore are larger than the ascending aorta which supplies the rest of the body.(Smith et al. 2000; Baumel 1993; West et al. 1981) The common carotid arteries branch from the brachiocephalic trunks as they curve to each side and supply the neck and head. The carotid arteries do not empty distally into a cerebral arterial circle of Willis as in mammals but have numerous intercarotid anastomosis that include the vertebral arteries.(Smith et al. 2000) The ascending aorta supplies the trunk, visceral organs, and pelvic limbs through its successive branches namely the coeliac, cranial renal, external iliac (also known as femoral), ischiatic, caudal mesenteric, and internal iliac arteries for its major arterial trunks.(Baumel 1993) The pulmonary trunk emerges from the right ventricle and divides into the left and right pulmonary arteries.(Baumel 1993)

Structurally the arteries can be classified into the elastic arteries composed of the aortic arch, thoracic aorta up to the coeliac artery, brachiocephalic trunks, and extrapulmonary portions of the pulmonary arteries, and the muscular arteries comprising the remainder of the arterial system.(West et al. 1981; Smith et al. 2000) The elastic arteries act as pressure reservoir redistributing the pulsatile input over time by expansion and recoil.(Smith et al. 2000) These arteries expand smoothly over a range of pressure allowed by the compliance of elastin and the stiffness of collagen. The resilience of avian elastic arteries (ratio energy recovered/energy needed to expand the vessel) is superior to that of mammals.(Smith et al. 2000) The arterial wall of the elastic arteries are composed of three layers, the tunica intima which is a single-cell layer of endothelial cells adjacent to the arterial lumen, the tunica media which is composed of concentric layers of collagen and elastic fibers composed of smooth muscle cells and elastin, and the tunica adventitia which is an outer layer of collagen fibers and connective tissue (Figure 2).(Smith et al. 2000; Fletcher & Abdul-Aziz 2008) The intima is separated from the media by a poorly defined internal elastic lamina which is itself separated from the adventitia by the external elastic lamina. Lamellar units do not entirely circumscribe the arteries.(Fletcher & Abdul-Aziz 2008; West et al. 1981) Muscular arteries have the 3 same tunica but the media is only composed of smooth muscle cells and elastin and the adventitia is much thicker and has less compliance.

The venous system presents some peculiarities in birds with notably two cranial *vena cavae* and a renal portal system. The cranial *vena cava* receive blood from the jugular veins and the subclavian veins. The jugular veins anastomose at the base of the head.(Smith et al. 2000) The renal portal system constitutes a ring ventral to the kidney with blood supplied from the gut and pelvic region through the vertebral sinus, external iliac vein, ischiatic vein, internal iliac vein, and caudal mesenteric vein. A valve, the renal portal valve, is present in the common iliac vein that is open under sympathetic stimulation with blood diverting to the caudal *vena cava* which increases blood return directly to the heart. The venous flow can be diverted to the hepatic portal

system through the caudal mesenteric vein where flow at this location can be bidirectional.(West et al. 1981)

Venous walls have the same organization than arterial walls with a tunica intima, media, and adventitia. However, the venous walls are thinner, have less muscle tissue in the media and more connective tissue in the adventitia. Veins are capacitance vessels and contain about 60-80% of the total blood volume.(Smith et al. 2000)

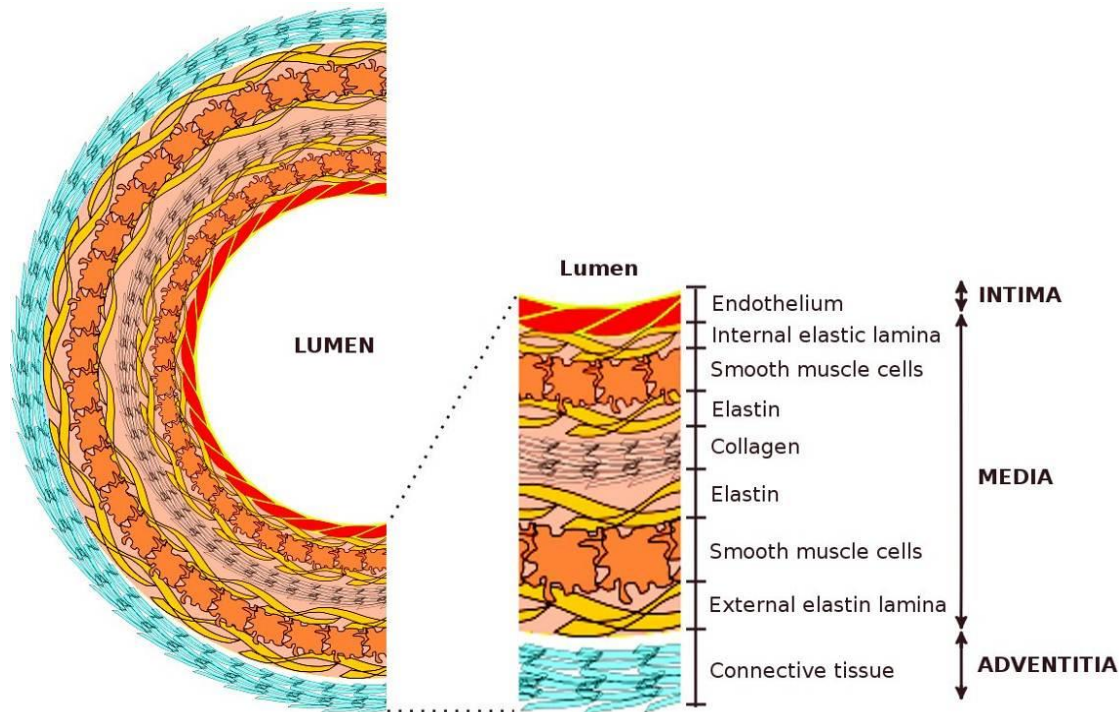


Figure 2: Schematic representation of the microanatomy of an avian elastic artery. The media is composed of alternate layers of elastic laminae (smooth muscle cells between 2 sheets of elastin fibers) and collagen fibers.

The control of peripheral blood flow is achieved by contraction of the muscular fibers modulated by a combination of autoregulatory mechanisms, action of humoral factors, and neural control.(Smith et al. 2000)

B. Diagnostic techniques

i. Physical examination

A complete history and thorough physical examination should be performed as for any clinical presentation. Species, age, gender, captive lifestyle and diet are thought to predispose individuals to cardiovascular diseases. Parrots are most often diagnosed with congestive heart failure and atherosclerosis whereas commercial poultry (e.g. broilers, turkeys) suffer from a high rate of cardiac diseases related to selection for production (Table 10). Clinical presentation of cardiac diseases may include dyspnea, exercise intolerance, falling off the perch, hind limb ataxia, altered mentation, neurological signs, syncope, collapse, and sudden death. Non-specific signs of disease are also frequently present such as lethargy, weight loss, and anorexia. Coughing does not usually occur in birds due to an enlarged heart because the aorta curves to the right and a cardiac enlargement does not cause bronchial compression.(Rosenthal & Miller 1997) Upon

physical examination, findings often present with cardiovascular disease include ascites, cyanosis or hypoperfusion [bluish or pale comb in chicken, bluish periorbital skins in some parrot species (e.g. African grey parrots, macaws), and increased ulnar vein refilling time], and increased dyspnea when restrained. Ascites is frequently present in cases of congestive heart failure but is also commonly associated with other disease conditions (Table 2). Hepatomegaly induced by liver congestion may be visible under the skin caudal to the keel in some patients. Preoxygenation may be necessary to conduct a physical examination in severely distressed patients.

Birds must be handled upright to prevent circulatory collapse.(Pees, Krautwald-Junghanns, et al. 2006) The arterial pulse is difficult to palpate in birds and not practical without anesthesia, it is typically obtained from the ulnar superficial artery at the level of the proximal inner aspect of the wing. Cardiac auscultation, while not sensitive in birds due to their fast heart rate, can be obtained by placing a pediatric or neonatal stethoscope over the cranial keel bone. The use of pediatric digital stethoscope may allow the amplification and the recording of the heart sounds, which can then be played at a slower speed for more accurate interpretation. In at least one case, a phonocardiogram was used to characterize a cardiac murmur in a bird.(Vink-Nooteboom et al. 1998)

Table 2: Common differential diagnoses for peritoneal fluid in birds

Differential diagnoses for peritoneal fluid in birds
-Congestive heart failure
-Portal hypertension
-Advanced hepatic disease (fibrosis, amyloidosis, iron storage disease)
-Reproductive-associated ascites (egg yolk coelomitis, ovarian cysts, cystic right oviduct, ectopic egg)
-Blockage of lymphatic drainage
-Hypoproteinemia
-Neoplastic ascites (e.g. biliary cystadenoma, ovarian)
-Viral ascites (avian viral serositis, polyomavirus, eastern equine encephalitis)
-Septic coelomitis (foreign body, ruptured intestine)
-Pancreatitis
-Coelomic hemorrhage

Murmurs and arrhythmias may be detected but are difficult to characterize, and the patients may be reexamined under anesthesia. However, systolic murmurs were detected in multiple cardiologic cases in birds.(Vink-Nooteboom et al. 1998; Mitchell et al. 2008; Evans et al. 2001; Beehler et al. 1980; Oglesbee & Lehmkuhl 2001; Pees et al. 2001; Isaza et al. 1992) Muffled heart sounds may indicate pericardial effusion, accumulation of fluid in the ventral hepato-peritoneal cavities, or hepatomegaly surrounding the heart. In some species (e.g. pelecaniformes), the presence of air from the interclavicular airsac between the heart and the keel may also muffle the heart sounds. The normal heart rate of birds is high, scales negatively with body weight, can increase up to 4 times the resting heart rate during flight and is expected to increase similarly during restraint (Table 3). As such, the avian normal heart rate can vary

tremendously within an individual. Pulmonary auscultation is usually of low value to detect pleural effusion or pulmonary edema in birds.

Table 3: Normal heart rates of birds (bpm) as a function of weight using the following formula: resting, $HR=744 \times W^{-0.209}$; flight, $HR=1506 \times W^{-0.157}$. Average values are likely to reflect the approximate range (resting-flight/restraint) of heart rates to be expected in most avian species.(West et al. 1981)

Weight (g)	Heart rate (resting)	Heart rate (flight/restraint)	Factor increase
25	380	909	2.4
50	329	815	2.5
100	284	731	2.6
200	245	655	2.7
300	226	615	2.7
400	213	588	2.8
500	203	568	2.8
1000	175	509	2.9
2000	152	457	3.0

ii. Blood pressure measurement

Arterial blood pressure is higher in birds than in mammals. Direct arterial blood pressure is typically obtained by placing an arterial catheter either in the superficial ulnar artery in the proximal inner aspect of the wing or in the deep radial artery in the distal wing. The external carotid artery has also been used. It is then connected to a pressure transducer and measured by an anesthetic monitor (Table 4).

Indirect blood pressure can be obtained using a Doppler transducer and a sphygmomanometer usually placed on the wing or leg with a cuff measured at 30-40% of the limb circumference. However it has been consistently demonstrated that values obtained with this method do not agree with direct systolic blood pressure measurements and may therefore be of low clinical values as a diagnostic tool.(Acierno et al. 2008; Johnston et al. 2011; Zehnder et al. 2009) Limits of agreement were wide in a study in Hispaniolan Amazon parrots (*Amazona ventralis*) at -37 to 85 mmHg and -14 to 42 mmHg for wing and leg measurements, respectively. In a study on various species of psittacines, large variation was seen in repeated indirect blood pressure measurements with most variability attributable to individual variation and cuff placement.(Johnston et al. 2011) However, this suggested that monitoring trends in indirect blood pressure measurement may be useful in the same bird during a single cuff placement such as occurring during an anesthetic event. In an experiment in red-tailed hawks (*Buteo jamaicensis*), indirect blood pressure measurements were found to be in disagreement with direct systolic blood pressure but with acceptable agreement with mean blood pressure with limits of agreement of -9 to 13.(Zehnder et al. 2009) This suggests that accuracy of indirect techniques may be higher in large birds. The oscillometric method of indirect blood pressure measurements has been found unreliable in all studied birds.(Acierno et al. 2008; Zehnder et al. 2009)

Table 4: Direct arterial blood pressure [mean, (mean \pm 2SD reference interval) mmHg] in selected species of birds

Species	SAP	MAP	DAP	Ref
Amazon parrot (isoflurane, n=8)	133 (88-177)	117 (76-158)	102 (58-146)	(Schnellbacher et al. 2012)
Amazon parrot (isoflurane, n=16)	163 (127-199)	155 (119-191)	148 (112-184)	(Acierno et al. 2008)
Pigeon (isoflurane, n=15)	93 (73-113)	82 (54-110)	72 (46-98)	(Touzot-Jourde et al. 2005)
Red-tailed hawk (conscious, n=8)	220 (119-331)	187 (104-271)	160 (70-2500)	(Hawkins et al. 2003)
Red-tailed hawk (sevoflurane, n=6)	178 (124-232)	159 (109-209)	143 (95-191)	(Zehnder et al. 2009)
Great horned owl (conscious, n=6)	231.5 (157-306)	203 (146-260)	178 (128-228)	(Hawkins et al. 2003)
Bald eagle (isoflurane, n=17)	195 (165-225)	171 (142-200)	148 (120-176)	(Joyner et al. 2008)
Bald eagle (sevoflurane, n=17)	144 (116-172)	139 (111-167)	134.5 (106-163)	(Joyner et al. 2008)
Chicken (anesthetized, n=40)	141 (118-163)	136 (114-158)	131 (109-153)	(Koch et al. 1983)
Turkey (conscious, n=20)	302 (289-315)	253 (242-264)	204 (194-214)	(Speckmann et al 2011)
Pekin duck (anesthetized, n=72)	165 (138-192)	143 (111-174)	121 (85-157)	(Langille et al 1975)

In general, hypotension is defined as a systolic blood pressure lower than 90 mmHg and mean lower than 60 mmHg.(Lichtenberger & Ko 2007) On the other hand, values for hypertension in birds have been poorly defined and are expected to be higher than in mammals owing to their greater blood pressure. Systolic values over 200 mmHg have been proposed as hypertensive.(Lichtenberger & Ko 2007)

iii. Clinical pathology

Apart from assessing the general health of the avian patient, clinical pathology tests may reveal specific changes associated with cardiovascular diseases but are of low sensitivity. Erythrocytosis may be caused by chronic hypoxia due to persistent ventilatory-perfusion mismatching and increased oxygen demands. Leukocytosis may occur in avian bacterial myocarditis and valvular endocarditis cases. Cardiovascular microfilariae may be observed on the blood smear. Blood samples from patients with severe microfilarial infestation may be positive on canine heartworm antigenic test.(Echols et al. 2000) Arterial blood samples and blood gas analyses may help pinpoint an oxygenation problem. Myocardial damage can lead to a rise in CK (and cardiac CK isoenzyme) and cardiac troponin T (only 68% sequence homology between chicken and humans which may affect diagnostic tests accuracy, BLAST analysis, 2012) or I.(Shrubsole-Cockwill et al. 2008) Electrolyte disorders (Ca, Mg, K, Na), hypoproteinemia, and hyperuricemia can also cause arrhythmia and cardiac diseases. Bile acids

are frequently elevated with hepatic congestion secondary to congestive heart failure. Thyroid imbalance may contribute to heart disease but is rare in pet birds. Lipoprotein abnormalities may also be diagnosed in conjunction with some degenerative lesions but have to be interpreted in the context of the egg-laying cycle and pathologic elevations have been poorly characterized. Finally, ascitic, pericardial, and effusion fluid should always be analyzed and can provide useful information. Cardiac-induced ascitic fluid is a pure or modified transudate, with low protein and cellular content and specific gravity. Fluid should also be submitted for culture. Blood culture may be valuable to isolate causative agents responsible for cardiac bacterial infections and can be performed with only 0.1-2 mL.

iv. Electrocardiography

An ECG records the cardiac electrical activity and is invaluable to investigate conduction disorders and arrhythmias. Most avian cardiovascular diseases are accompanied by changes on the ECG which may also provide clues about chamber enlargement. (Lumeij & Ritchie 1994) However, cardiopathy can occur without electrocardiographic changes. The avian ECG is typically obtained in the frontal plane by placing two front electrodes on the proptagia and one (left) or two (earth on right) back electrodes on the knee webs using needle electrodes or flat clips. Each lead evaluates the cardiac electrical activity on a different direction and a standard examination classically includes 3 bipolar leads (I, II, and III) and 3 augmented unipolar leads (aVR, aVL, aVF) (Figure 3).

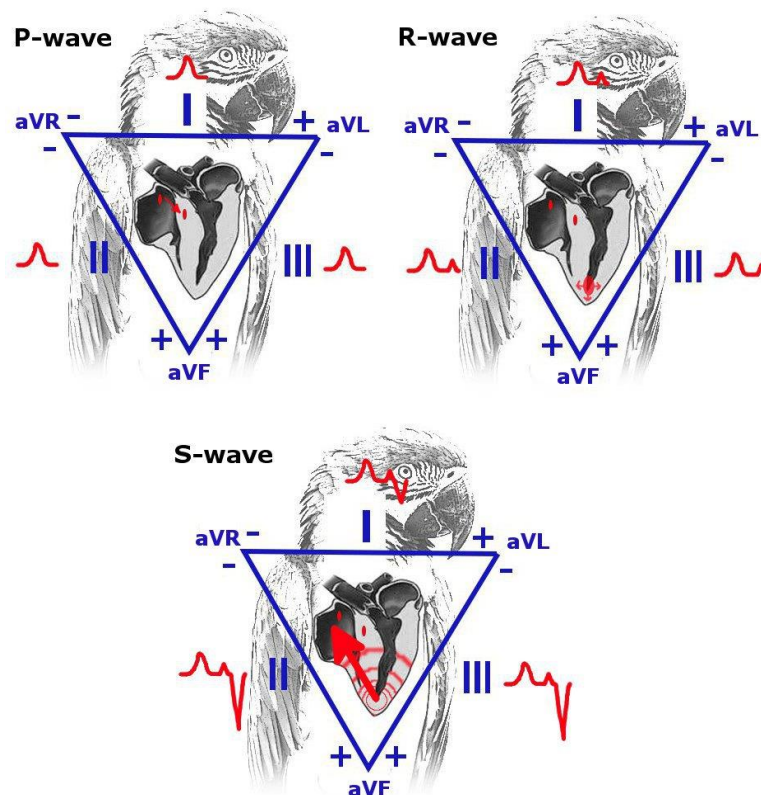


Figure 3: Schematic representation of the electrical activity of the heart with depiction of lead recordings (Einthoven's triangle). Lead I, II, and III are bipolar leads and lead aVR, aVL, aVF are augmented unipolar leads. Tracings represent the vectorial projection of the summation of the electrical activity. P wave, atrial depolarization from the SA to the AV node; R wave, depolarization at the apex of the left ventricle; S wave, ventricular depolarization.

A proper ECG recording is easier to obtain on anesthetized birds as few will tolerate the procedure awake or movement and muscle tremors may impair the recordings.(Oglesbee et al. 2001) However, ECG tracings on awake birds can still be obtained on pigeons, some raptors, and lethargic birds. Recordings need to be performed at a speed of 50-100 mm/s with 100 mm/s being optimal to better assess QRS complexes morphology. Electrocardiographic measurements are typically performed on lead II tracings. Electrical current from heating devices and anesthetic equipment can interfere with ECG tracings and electrical filters from ECG machines may be used. The significance of the different parts of an ECG complex during the cardiac cycle is explained on Table 5 and Figure 3.

The normal avian ECG is usually composed of P, S, T, and a small R wave. The Q wave is usually missing and a Ta wave is present in certain birds. The QRS complexes are mainly of the (Q)rS types on lead II meaning the S wave is the most prominent. This contrasts with mammals where the QRS complexes are most often of the qRs type. Interpretation of the ECG obeys to the same rules as in mammals, should be methodical, and include determination of the heart rate, heart rhythm, mean electrical axis (MEA), and measurements.(Lumeij & Ritchie 1994)

Table 5: Significance of the different sections of an ECG during one cardiac cycle, sections are in order of appearance.

ECG segment	Electrophysiologic meaning
P wave	Depolarization of atria, conduction from SA to AV nodes
F waves	Absent in normal birds
	Baseline undulations occurring in atrial fibrillation
Ta wave	Present in pigeons, some poultry species
	Repolarization of atria
PR interval	P wave + delayed conduction at AV node
QRS complex	Ventricular depolarization
	Q wave absent in most birds. Most birds have (Q)rS complexes on lead II
R' wave	Absent in normal birds
	Observed in bundle branch block
QT interval	Corresponds to length of ventricular contraction
ST segment	Period between end of ventricular depolarization and beginning of ventricular repolarization
T wave	Repolarization of the ventricles
U wave	Absent in normal birds
	Repolarization of papillary muscles or repolarization of conducting system

In contrast to mammals, the cardiac mean electrical axis is negative in birds with a prominent S wave, which gives negative QRS complexes on lead II. This is caused by transmission of the depolarization from subepicardial to endocardial.(Lumeij & Ritchie 1994) However, some poultry breeds have a positive MEA and QRS complexes such as broilers and Pekin ducks. The MEA is affected by changes in heart position and relative dilation of cardiac chambers. The MEA can be calculated using the vector method, the isoelectric method, or the largest net deflection method. The isoelectric method is the most practical and consists of identifying the

lead closest to isoelectricity (summation of waves without P and T=0 mmV), the MEA lies along and has the polarity of the perpendicular lead (Figure 4). Changes in ventricular MEA are due to changes in cardiac shape and position and are typically associated with right ventricular enlargement and left ventricular hypertrophy.(Lumeij & Ritchie 1994)

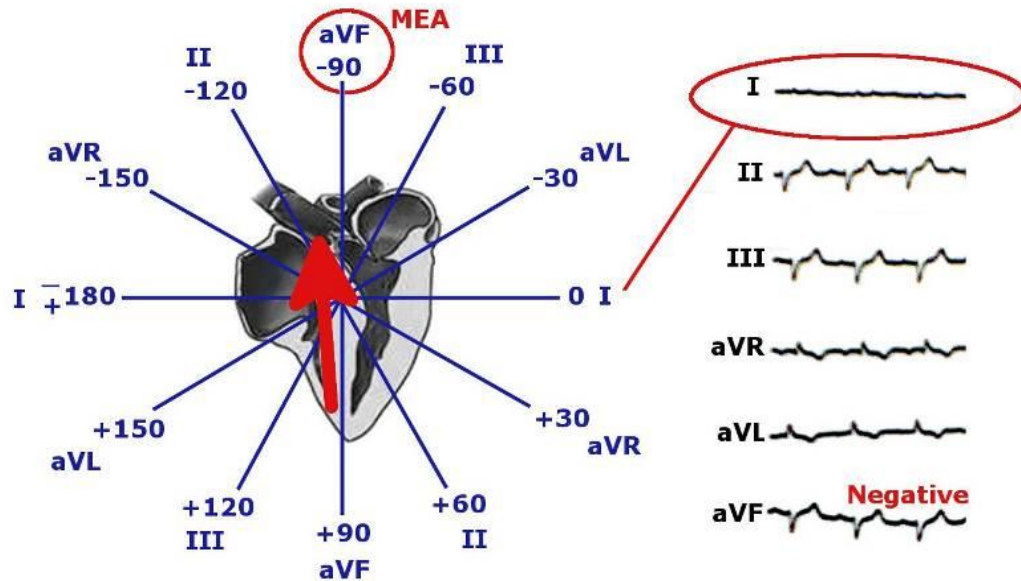


Figure 4: Determination of the ventricular mean electrical axis using the isoelectric method and the Bailey's hexaxial system. Example on a tracing where the ventricular depolarization is isoelectric in lead I and negative in the orthogonal aVF lead resulting in a MEA of -90°.

Usually, measurements include P amplitude and duration, PR interval, S amplitude, QRS duration, ST segment, T amplitude, QT interval, and MEA (Figure 5). The shape of the P wave may indicate left atrial hypertrophy (wide), right atrial hypertrophy (tall), or biatrial (wide and tall). However, the sensitivity and specificity of these ECG criteria are low. Each P wave should precede and be related to a QRS complex. Increase in the PR interval indicates an increased delay in electrical conduction at the AV node (AV block). Morphologic alteration of the QRS complexes may indicate left ventricular hypertrophy (increased S amplitude or QRS complex duration) or right ventricular hypertrophy (prominent R wave). The T wave is usually positive in birds in lead II and a change in polarity indicates myocardial hypoxia.(Lumeij & Ritchie 1994) In high heart rates, generally over 300-500 bpm, P and T waves may be fused (atria depolarized before ventricles are completely repolarized) and the P wave not discernible.(Sturkie 1976; Zandvliet 2005) This P on T phenomenon also seems to be a normal finding in Amazon and African grey parrots.(Zandvliet 2005; Nap et al. 1992) ST segment elevation is common in healthy birds and does not indicate cardiac diseases as in mammals.(Lumeij & Ritchie 1994; Oglesbee et al. 2001) ST slurring is common, in which the ST segment is short or absent or the S wave is merged with the T wave.(Lumeij & Ritchie 1994; Zandvliet 2005) Accounting for these electrophysiologic specificities of birds, the interpretation of the avian ECG is similar to that of mammals.

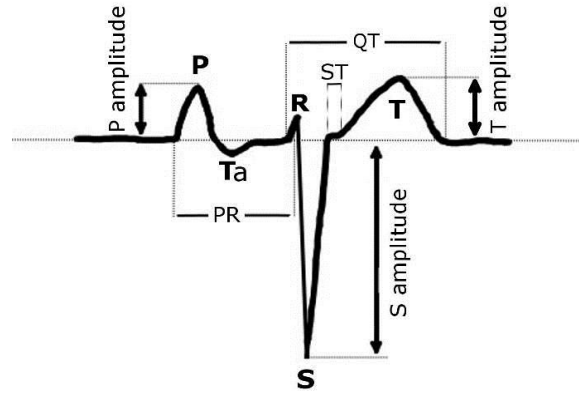


Figure 5: Typical avian ECG complex with depiction of the different measurement landmarks.

Reference intervals have been published for several species (Table 6). Anesthesia is suspected to affect only the ECG measurements of heart rate, QT interval, and the frequency of arrhythmias (AV blocks).(Nap et al. 1992; Joyner et al. 2008; Aguilar et al. 1995)

Table 6: ECG measurements reference values on lead II in selected avian species (amplitude in mV, duration in s)(Nap et al. 1992; Lumeij & Stokhof 1985; Oglesbee et al. 2001; Burtnick & Degernes 1993; Cinar et al. 1996; Sturkie 1976)

Note: to obtain a 95% interval, all published results in the form of mean \pm SD were reported as mean \pm 2SD and in the form of mean \pm sem were reported as mean \pm 2sem \sqrt{n} , when only the range was published, it was reported as is. N=number of birds examined.

Species	Racing pigeon	Amazon parrot	Grey parrot	Macaw	Cockatoo	RT hawk	Bald eagle	Pekin duck	Chicken
N	60	37	45	41	31	11	20	50	72
Heart rate	160-300	340-600	340-600	255-555	259-575	80-220	50-160	200-360	180-340
P-wave amplitude	0.4-0.6	0.25-0.60	0.25-0.55	0.03-0.47	0.13-0.53	-0.1-0.175	0.050-0.325		
P duration	0.015-0.020	0.008-0.017	0.012-0.018	0.009-0.021	0.009-0.025	0.020-0.035	0.030-0.060	0.015-0.035	0.035-0.043
PR interval	0.045-0.070	0.042-0.055	0.040-0.055	0.040-0.068	0.039-0.071	0.050-0.090	0.070-0.110	0.04-0.08	0.073-0.089
S-wave amplitude	1.5-2.8	0.7-2.3	0.9-2.2	0.27-1.43	0.27-1.59	0.300-0.900	0.150-1.450	0.35-1.03	0.10-1.0
QRS duration	0.013-0.016	0.010-0.015	0.010-0.016	0.002-0.030	0.014-0.026	0.020-0.030	0.020-0.040	0.028-0.044	0.02-0.028
T amplitude	0.3-0.8	0.3-0.8	0.18-0.6	0.12-0.80	0.17-0.97	0.000-0.300	0.050-0.200	0.04-0.40	0.03-0.28
QT interval	0.060-0.075	0.050-0.095	0.048-0.080	0.053-0.109	0.065-0.125	0.080-0.165	0.110-0.165	0.08-0.12	
MEA	-83 to -99	-90 to -107	-79 to -103	-76 to -87	-73 to -89	-50 to -110	-30 to -150	-160 to 95	-91 to -120

v. Radiography

While radiologic examination is of low sensitivity for cardiovascular diseases, severe cardiac enlargement and vascular mineralization may be detected.(Pees, Krautwald-Junghanns, et al. 2006; Mans & Brown 2007) Other changes that frequently accompany cardiovascular radiologic signs include loss of coelomic contrast and airsac space due to ascites and hepatomegaly due to hepatic congestion. Several ratios have been determined but the most practical is the heart width to thoracic width ratio on the ventrodorsal view because these two measurements are highly correlated in birds (Figure 6). In medium sized psittacine birds, this ratio is 51-61%.(Straub et al. 2002; Pees, Krautwald-Junghanns, et al. 2006) In Harris' hawks, this ratio was found to have similar values.(Barbon et al. 2010) This ratio may also vary up to 10% based on the respiratory phase.(Lumeij et al. 2011) In falcons, this ratio is considerably greater with an upper limit of 70%.(Barbon et al. 2010; Lumeij et al. 2011)

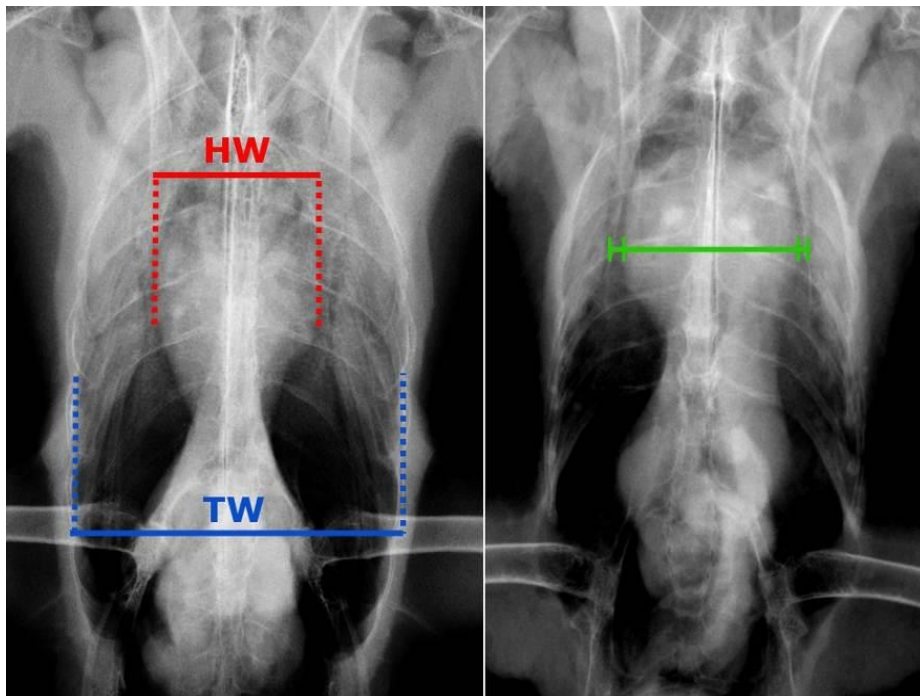


Figure 6: Left, heart width and thoracic width landmarks in a macaw (*Ara* spp.). Right, heart width and sternal width landmarks in a peregrine falcon (*Falco peregrinus*).

Rather than using a simple and similar ratio for all individuals, regression-based reference intervals for cardiac radiographic sizes have been determined in peregrine falcons (*Falco peregrinus*), red-tailed hawks (*Buteo jamaicensis*), screech owls (*Otus asio*), and Canada geese (*Branta canadensis*).(Hanley et al. 1997; Lumeij et al. 2011) With this approach, a predictive reference interval is calculated using established regression equations based on either the thoracic or the sternal width on ventrodorsal views and compared with the measured value of the patient (Table 7). The sternal width should be measured at the same level as the heart width, however the sternal landmarks may be obscured by an enlarged heart or fluids in diseased birds (Figure 6). In peregrine falcons, the sternal width on the ventrodorsal view was found to be a better predictor of the heart width than the thoracic width and the sternal and thoracic width were found to be collinear (thus could not be incorporated into the same equation).(Lumeij et al. 2011)

Table 7: Regression-based equations for reference heart width (in cm) in selected avian species.(Hanley et al. 1997; Lumeij et al. 2011)

HW, heart width; SW, sternal width; TW, thoracic width. The higher the R-square, the better the precision of the reference limits. These equations are for the 95% confidence interval of the fitted value, the 95% confidence interval of the predictive value is slightly wider but predictive equations are not practical.

Species	N	Regression equation	R-square
Peregrine falcon	60	HW=0.83×SW+0.37±0.16	0.68
		HW=0.41×TW+1.27±0.18	0.33
Red-tailed hawk	50	HW=0.42×SW+0.20×TW+3.42±2.02	0.50
Screech owl	50	HW=0.36×SW+0.13×TW+7.03±1.40	0.36
Canada goose	50	HW=0.27×SW+0.21×TW+15.15±5.00	0.27

vi. Echocardiography

Echocardiography is undoubtedly the single most useful diagnostic tool in avian cardiology and its clinical application and value have been documented in multiple case reports in various species.(Vink-Nooteboom et al. 1998; Pees et al. 2001; Straub et al. 2003; Phalen et al. 1996; Pees, Schmidt, et al. 2006; Oglesbee & Lehmkuhl 2001; Mitchell et al. 2008; Shrubsole-Cockwill et al. 2008; Mans & Brown 2007; Sedacca et al. 2009; Evans et al. 2001) Echocardiography can detect changes in chamber dimensions, valvular lesions and insufficiency, pericardial diseases, cardiac masses, pulmonary arterial hypertension, wall motion disorders, septal defects and diastolic disorders.

However, cardiac ultrasound examination presents some major limitations in birds due to the location of the heart in an indentation of the keel and the surrounding airsacs (see anatomy section). Therefore, available acoustic windows and cardiac views are limited. Two standardized approaches have been described for transcoelomic examination: a ventromedian and a parasternal approach.(Pees et al. 2004; Pees & Krautwald-Junghanns 2005; Krautwald-Junghanns et al. 1995; Pees, Krautwald-Junghanns, et al. 2006) A high frequency transducer with a small contact surface and high frame rate are recommended. The use of alcohol should be limited in anesthetized birds to prevent hypothermia. The ventromedian approach consists of placing the probe caudal to the keel and imaging the heart cranially using the liver as an acoustic window to avoid airsacs laterally and the keel ventrally (Figure 7). This approach is used most often in psittacines and raptors. It can be performed on the bird awake or anesthetized. Birds should be fasted to limit interference with the gastrointestinal tract. Simultaneous ECG can be performed to better interpret images in relation to the cardiac cycle but is not essential.

Only two views can classically be obtained through this approach: the horizontal four-chamber view and the vertical two-chamber view by rotating the probe by 90 degrees (Figure 8). All views are longitudinal (long axis) and cardiac transverse views (short axis) and M-mode echocardiography, which has better temporal resolution, cannot be performed in birds by the transcoelomic approach. This precludes the establishment of the same echocardiographic standards in birds as in small animal cardiology.(Thomas et al. 1993) Therefore the amount of information gathered from the transcoelomic echocardiographic examinations is much limited in birds and all morphometric and functional measurements have to be performed on two-dimensional images (B-mode). Measurements on several cardiac cycles should be averaged to obtain representative values. Reference intervals have been published for ventricular and atrial

dimensions and fractional shortening $[(\text{diastole-systole})/\text{diastole} \%]$ in several avian species (Table 8). (Pees et al. 2004; Krautwald-Junghanns et al. 1995; Pees, Krautwald-Junghanns, et al. 2006) Transcoelomic echocardiography is also thought to underestimate the true fractional shortening of the highly efficient avian heart. (Beaufreire et al. 2012) Right ventricular measurements are rarely taken in mammals due to its complex three-dimensional configuration. (Bélanger 2005) Furthermore, recent evidence suggest that taking echocardiographic measurements may not be clinically useful considering the avian heart size, heart rate, current equipment resolution and that observers can add up to 30% variability. (Beaufreire et al. 2012)

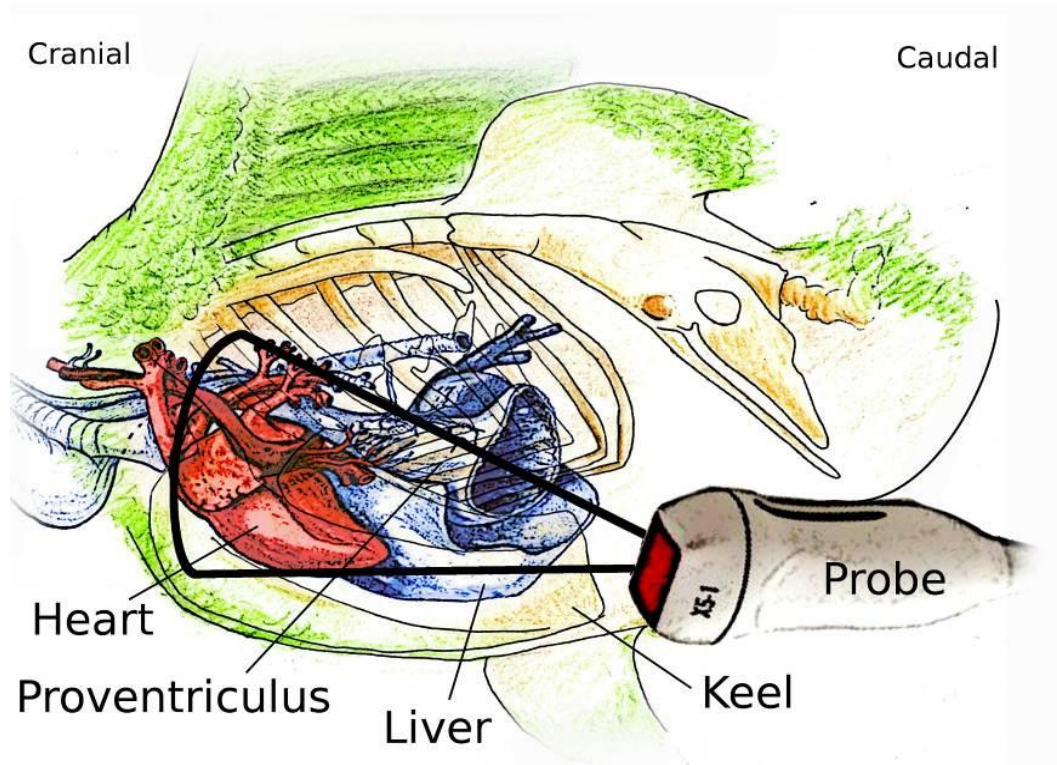


Figure 7: Schematic representation of the ventromedian echocardiographic approach in an Amazon parrot. The bird is oriented cranio-caudally and dorso-ventrally. The heart is imaged through the liver. It can easily be inferred from this diagram that a filled gastrointestinal tract may interfere with the acoustic window.

In most dogs and cats, a good impression of cardiac chamber size and function can be achieved without making any quantitative measurements. (Boon 2011) Likewise, an adequate morphologic and functional assessment of the avian heart can be performed qualitatively during the echocardiographic examination. Nevertheless, pathologic changes imaged in birds are usually severe when cardiac disease is present with drastic chambers dilation (commonly the right heart), pericardial effusion, ascites, and poor contractility, which do not require measurements for confirmation. If measurements are obtained for follow up evaluation, it is recommended that the same echocardiographer and equipment are used and changes in measurements should be larger than 20% to be considered genuine. Left ventricular measurements seem to be more reliable overall. (Beaufreire et al. 2012)

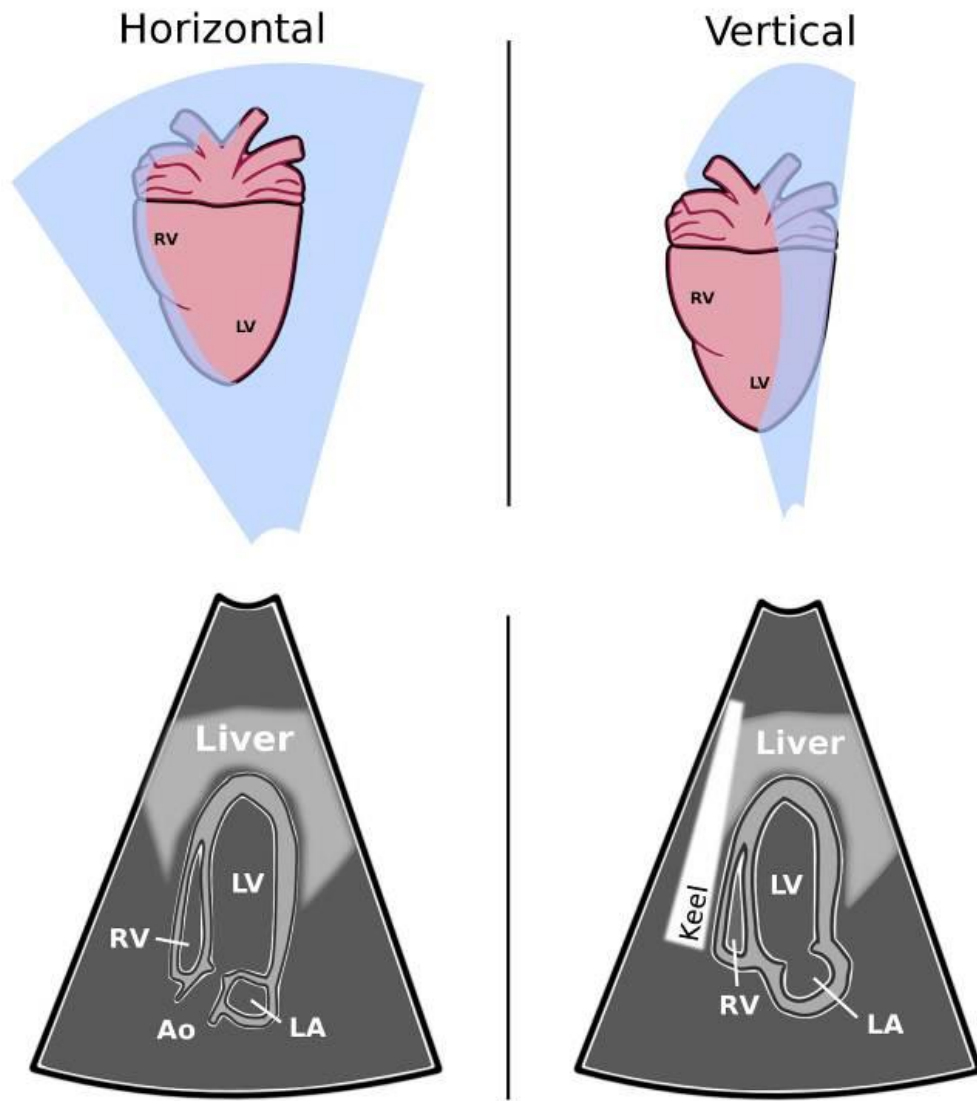


Figure 8: Horizontal four-chamber view and vertical two-chamber view in birds as classically obtained through the ventromedian approach.

Color Doppler echocardiography can be used for detection of turbulence and reflux indicative of valvular insufficiency with right atrioventricular insufficiency being most commonly imaged. Spectral Doppler echocardiography can be used to measure inflow and outflow velocities and reference intervals have been published in a few species (Table 9). (Pees, Krautwald-Junghanns, et al. 2006; Straub et al. 2004; Pees et al. 2004; Straub et al. 2003) Fortunately, echocardiographic examinations are easier and more rewarding in birds with cardiac disease because the ascitic fluid, pericardial effusion, hepatomegaly, and cardiac enlargement greatly improve acoustic windows and facilitate the procedure.

Table 8: Echocardiographic reference intervals (mm) in selected avian species obtained in the horizontal four-chamber view.(Pees et al. 2004; Boskovic et al. 1995; Pees, Krautwald-Junghanns, et al. 2006)

*Note: to obtain a 95% interval, all published results in the form of mean \pm SD were reported as mean \pm 2SD, N=number of birds examined, FS=Fractional shortening. Echocardiographic measurements may not be reliable and clinically useful. *European diurnal raptors included common buzzard, European sparrowhawk, northern goshawk, and black kite.*

Parameter	African grey parrots	Amazon parrots	Cockatoos	Diurnal raptors*	Pigeons (parasternal)
N	60	10	10	100	50
Left ventricle					
Systole length	18.4-26	16.5-25.7	16.4-21.6	9.1-20.3	15.9-19.9
Systole width	4.8-8.8	4.3-9.1	3.0-9.8	4.1-8.5	4.4-6.0
Diastole length	20.2-27.8	17.7-26.5	16.7-23.1	11.0-21.8	17.3-22.9
Diastole width	6.6-10.6	6.4-10.4	5.3-11.3	5.3-10.1	6.2-8.6
FS (%)	13.8-31.4	14.4-31.2	11.6-39.6		
Right ventricle					
Systole length	6.4-12.0	5.8-13.0	7.9-12.7	7.3-18.1	
Systole width	1.0-4.6	1.7-4.5	7.9-12.7	0.9-3.3	
Diastole length	7.7-15.3	7.7-12.9	6.7-15.9	8.9-18.9	8.3-11.5
Diastole width	2.6-7.0	2.6-7.8	2.5-4.5	0.9-4.1	3.0-5.0
FS (%)	17.0-64.6	26.7-41.5	12.7-53.9		
Aorta					
Systole diameter	2.8-4.4	2.0-4.0			
Diastole diameter	2.8-5.2	2.2-4.6		2.0-3.6	2.8-3.2

Table 9: Spectral Doppler echocardiographic reference intervals (m/s) in selected avian species obtained in the horizontal four-chamber view.(Pees, Krautwald-Junghanns, et al. 2006; Straub et al. 2004; Straub 2003)

Note: to obtain a 95% interval, all published results in the form of mean \pm SD were reported as mean \pm 2SD, N=number of birds examined. Parrots were anesthetized, raptors were awake.

Species	N	Left diastolic inflow	Right diastolic inflow	Aortic systolic outflow
Amazon parrots		0.12-.24	0.12-0.32	0.67-0.99
Cockatoos		0.02-0.62		0.40-1.16
African grey parrots		0.27-0.51		0.63-1.15
Macaws		0.40-0.68		0.55-1.07
Harris' hawks	10	0.13-0.25	0.15-0.27	0.75-1.43
Falcons	15	0.18-0.38	0.17-0.37	1.07-1.43
Common buzzard	10	0.16-0.28	0.13-0.25	1.04-1.68
Barn owls	10	0.14-0.26	0.10-0.34	0.84-1.32

The parasternal approach consists of placing the probe laterally (typically on the right to avoid the ventriculus) behind the ribs and above the sternum and imaging the heart cranio-

medially.(Krautwald-Junghanns et al. 1995; Pees, Krautwald-Junghanns, et al. 2006) This approach can be performed on pigeons, some raptors, and is the preferred choice when examining gallinaceous birds (especially younger chicken). In these birds, the limited caudal extension of the ribs and the larger fenestration of the keel allow a lateral approach to the heart. Typically, more imaging planes can be obtained and transverse views have been described in pigeons and chickens.(Krautwald-Junghanns et al. 1995; Martinez-Lemus et al. 1998)

A transesophageal echocardiographic protocol has been implemented in several species of birds in an attempt to alleviate the limitations associated with the transcoelomic approach. With this technique, a transesophageal ultrasonographic probe is inserted into the upper digestive system with the bird under general anesthesia and the heart is imaged from inside the proventriculus.(Beaufre et al. 2010) Better resolution imaging and details of cardiac structures are typically obtained with 3 positions of the probe (cranial, middle, caudal) giving 5 consistent echocardiographic views. Furthermore, transverse views and M-mode imaging are possible through the transesophageal approach. However, the equipment is expensive, not widely available, the bird must be anesthetized, and the procedure cannot be performed in small psittacine birds because of a narrow entrance to the thoracic inlet.(Beaufre et al. 2010) The procedure has been used to diagnose and monitor a case of dilated cardiomyopathy in a Harris' hawk at the Louisiana State University School of Veterinary Medicine.

vii. Advanced cross-sectional imaging

Computed tomography and magnetic resonance imaging are seldom used to image the avian heart as scans cannot be gated to the fast cardiac cycle in birds to reduce motion artifacts and improve diagnostic value. However computed tomography can be used to image the arteries and can readily diagnose cardiomegaly, venous congestion, and edema.

viii. Angiography

Angiography can be achieved on avian patients through the use of fluoroscopy or computed tomography. The circulation of intravenous contrast agents in birds is extremely fast and image acquisition should be performed during injection or shortly thereafter. The use of angiography in birds has recently been reviewed.(Beaufre et al. 2010)

Fluoroscopic angiography can visualize the heart and vascular tree in real time. Under general anesthesia, the bird is initially positioned in left lateral recumbency on a fluoroscopy table. A bolus of nonionic iodinated contrast agent (2 mL/kg IV; iohexol 240 mg/mL; Omnipaque, GE Healthcare Inc, Princeton, NJ, USA) is injected, at a rate of 1–2 mL/kg per second, through a catheter inserted into the basilic or medial metatarsal vein during video acquisition at a rate of 30 frames/s for the best resolution. The same bolus is repeated to obtain the ventrodorsal view with the bird placed in dorsal recumbency. The brachiocephalic trunks, aorta, pulmonary arteries, pulmonary veins, and caudal *vena cava* can be observed. The brachiocephalic trunks and aorta can be seen pulsating with the heartbeats. Marked lumen changes are noted during the cardiac cycle. The procedure is easy, inexpensive, and can be recorded for further analysis and measurements. For measurement, to account for different degrees of magnification, a calibrated marker should be kept in the field during fluoroscopic acquisition but fluoroscopic angiography is likely more useful for qualitative assessment and investigation of aneurysm and stenosis. Digital subtraction angiography is a fluoroscopic technique used in interventional radiology to clearly visualize blood vessels in a dense soft tissue or bone environment. Images are produced by subtracting a pre-contrast image from later images once the contrast medium has been

introduced into the vascular system, which results in visualizing only the contrast-filled vessels, without the background. It considerably increases the outlines of the arteries and the detection of smaller arteries not seen with conventional angiography, specifically for extremities, such as legs, wings, and the head, however the images tend to be easily degraded by small motions and noise (Figure 9). A preliminary, nonenhanced fluoroscopic image is recorded before administering a bolus of contrast medium and is digitally subtracted during the angiography procedure. The same bolus technique and a similar dose of contrast medium as used for regular fluoroscopic angiography are required for digital subtraction angiography, except that this option is selected in the machine. Reports of angiography applications are still limited in birds. A coronary aneurysm was diagnosed with angiography in an umbrella cockatoo.(Vink-Nooteboom et al. 1998) Angiocardiography has also been used clinically in a racing pigeon, 2 blue and gold macaws (*Ara ararauna*), and a whooper swan (*Cygnus cygnus*). (Lumeij & Ritchie 1994; Phalen et al. 1996)

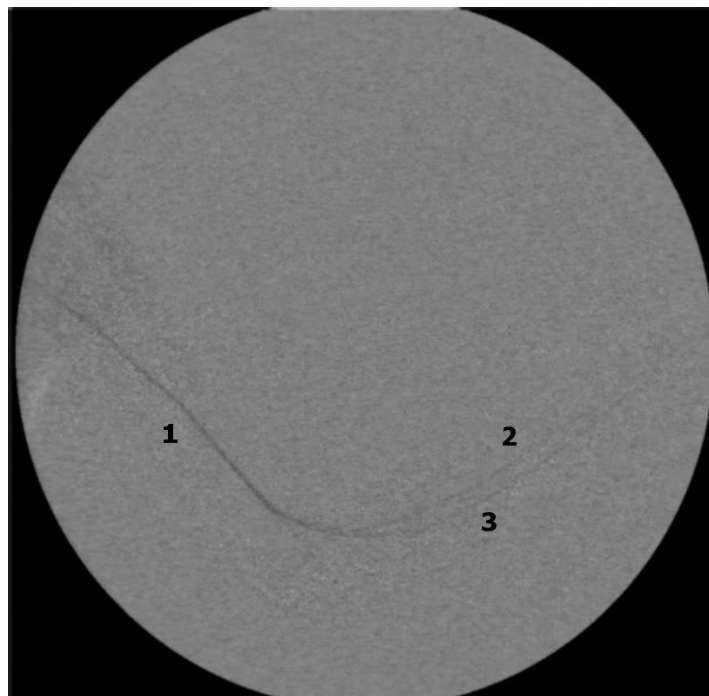


Figure 9: Digital subtraction angiography on the wing of a barred owl (*Strix varia*), ventral view. 1, brachial artery; 2, deep radial artery; 3, superficial ulnar artery.

A CT examination provides an excellent assessment of all major arteries and their anatomy in psittacines and raptors. (Krautwald-junghanns et al. 2008) The addition of contrast media greatly enhances the visualization of the arteries and veins and their lumen but a standardized protocol has yet to be established. In particular, the optimal timing of the scan in respect to the intravenous injection of contrast, and the reliability of measurement in different window and level presets have not been evaluated. It is expected that CT angiography will be a valuable diagnostic tool for avian vascular diseases due to its three-dimensional resolution and reconstruction capabilities.

ix. Coelioscopy

Coelioscopy allows direct visualization of the heart and major arteries through the standard lateral approaches with the endoscope located in the cranial thoracic airsacs, the interclavicular approach with the endoscope located in the interclavicular airsac, and the ventral midline approach with the endoscope located in the ventral hepato-peritoneal cavities.(Taylor 1994; Beaufrère et al. 2010) Endoscopy can only detect gross, color, and structural changes to the cardiovascular system such as cardiomegaly, pericardial effusion, pericardial exudate, arterial discoloration, and the presence of granulomas in the area. Pericardial biopsy and pericardiocentesis can be performed via endoscopy. The midline approach is recommended for pericardiocentesis to reduce the possibility of fluid leakage into the airsacs. An endoscopic needle is used with its sheath and should only protrude from the sheath by 1-2mm to prevent puncturing the heart during the procedure. Pericardial fluids should be analyzed.

C. Cardiovascular diseases of birds (other than atherosclerosis)

i. Prevalence of cardiovascular disease in birds

Overall, cardiac diseases are only common in poultry and companion psittacine birds (Tables 10 and 11). In other avian groups, cardiac disease appears to be a relatively rare occurrence but several disease entities have been documented (Table 11). In large pathologic reviews of birds of prey, primary cardiac diseases were not or rarely reported except for atherosclerosis.(Griner 1983; Cooper & Pomerance 1982; Naldo & Samour 2004)

Table 10: Prevalence (%) of selected cardiovascular diseases / lesions in psittaciformes (other than atherosclerosis)

	Oglesbee, 1998 (n=269)	Krautwald- Junghanns, 2004 (n=107)	Griner, 1983 (n=1322)	Kellin, 2009 (n=1298)
Cardiac disease	9.7	36	5.5	5.2
Congestive heart failure	5.6			
Pericardial effusion	1	6		
Fibrinous pericarditis		15		
Ascites	1.5	2		

Table 11: Some commonly reported cardiovascular diseases / lesions by species (other than atherosclerosis).(Griner 1983; Oglesbee & Oglesbee 1998; Lumeij & Ritchie 1994)

Species	Common cardiovascular diseases
Psittacines	Congestive heart failure
Ducks, geese, swans	Vascular nematodiasis (schistosomes, filarioids)
Chickens, turkeys	Ascites syndrome, cardiomyopathies, infectious, aortic rupture
Ostriches	Aortic rupture
Birds of prey	Viral myocarditis (West Nile virus)
Mynahs	Dilated cardiomyopathy

ii. Congestive heart failure

1. Pathophysiology of avian heart failure

Congestive heart failure is not a disease in itself but is the ultimate consequence of disease processes that affect parts of the avian cardiovascular and pulmonary systems (Table 12). Congestive heart failure occurs when the volume of blood presented to the heart is in excess of what can be pumped into the arterial system with ensuring organ congestion and decreased cardiac output. Heart failures can be due to abnormalities in the cardiac conduction system, valvular system, cardiac muscle, blood shunting, infection, impaired systolic and diastolic function, and to inadequate preload and afterload. All heart diseases do not necessarily lead to congestive heart failure but this condition is a frequent clinical end-point.

Table 12: Documented causes of congestive heart failure in birds

Causes	References
Valvular insufficiency	(Oglesbee et al. 2001; Pees et al. 2001; Beehler et al. 1980; Ensley et al. 1979; K. Rosenthal et al. 1993)
Valvular stenosis	(Mitchell et al. 2008)
Septal defects	(Evans et al. 2001; Bailey et al. 2001; Schmidt et al. 2003; Harari et al. 1983; Risi et al. 2011)
Ischemic cardiomyopathy	(Shrubsole-Cockwill et al. 2008)
Dilated cardiomyopathy	(Knafo et al. 2011; Julian 1998; Risi et al. 2011; Crespo et al. 2008)
Hypertrophic cardiomyopathy	(Pees et al. 2009; Schmidt et al. 2003; Oglesbee et al. 1998)
Arrhythmias	(Olkowski & Classen 1998)
Nutritional causes	(Lumeij et al. 1994; Crespo et al. 2008)
Pericardial effusion	(Straub et al. 2003; Balamurugan et al. 2004)
Iron storage disease	(Ensley et al. 1979; Morris et al. 1989)
Pulmonary arterial hypertension	(Sedacca et al. 2009; Currie 1999)
Pulmonary fibrosis/aspergillosis	(Zandvliet et al. 2001; Oglesbee et al. 1998)
Cardiac infection	(Lumeij et al. 1994; Schmidt et al. 2003; Isaza et al. 1992; Jessup 1980)
Toxic causes	(Burger et al. 1994; Fulton 2008; Czarnecki 1986)
Atherosclerosis	(Mans et al. 2007; Phalen et al. 1996; Sedacca et al. 2009; Shrubsole-Cockwill et al. 2008; Vink-Nooteboom et al. 1998)

Since birds possess similar neuroendocrine regulation of the cardiovascular system as mammals, the general pathophysiology of congestive heart failure is expected to be analogous. (Smith et al. 2000) One difference is that in birds, right congestive heart failure is more common than left which is suspected to be related to the particular anatomy of the right atrioventricular valve. (Julian 2002; Oglesbee & Oglesbee 1998) In addition, the pathophysiology of avian heart failure has been well studied in the prevalent chicken ascites syndrome but this disease is mainly related to production and rapid growth so not all findings may translate well to companion avian patients. (Julian 1993; Olkowski 2007; Currie 1999) In chicken ascites syndrome, the increased workload of the heart and oxygen demand brought about by fast

growing is coupled with an overall insufficient pulmonary capillary capacity and decreased respiratory efficiency in chickens compared to other birds. The cumulative effects of these conditions quickly leads to pulmonary hypertension which in turns leads to right ventricular hypertrophy and ultimately to dilation. Erythrocytosis also occurs which renders the blood more viscous thereby further increasing the cardiac workload. With the dilatory changes affecting the right ventricle, the right atrioventricular valve, which extends from its wall, develops insufficiency, which in turn increases the preload leading to systemic congestion and ascites by increased hydrostatic pressure (Figure 10). In the turkey spontaneous dilated cardiomyopathy, abnormal troponin T structure, and dysregulation of some cardiac enzymatic pathways may participate in the pathogenesis.(Crespo & Shivaprasad 2008; Biesiadecki & Jin 2002)

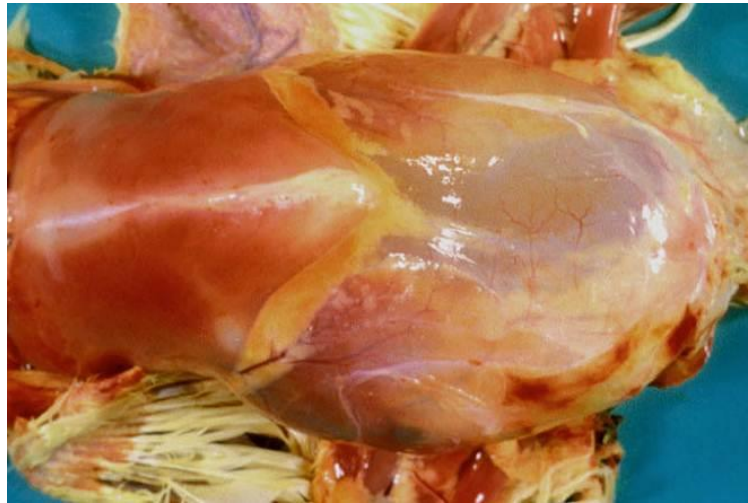

Figure 10: Ascites syndrome in a broiler chicken (Courtesy of Dr. John Barnes, North Carolina State University)

The decrease in cardiac output and blood pressure is detected by chemoreceptors, baroreceptors, cardiac mechanoreceptors, and the renal juxtaglomerular complex. Then, several compensatory measures similar to those induced by blood loss and dehydration take place, which may be counterproductive in the long-term in congestive heart failure cases.(Sisson 2010) Sympathetic tone increases causing an increase in heart rate, contractility, vasomotor tone, activation of the renin-angiotensin-aldosterone system (RAAS), and stimulation of the release of arginine vasopressin (arginine vasotocin in birds).(Sisson 2010) Renin released from the juxtaglomerular complex under stimuli such as hypotension, hypovolemia, decreased plasma sodium, and catecholamines accelerates the conversion of circulating angiotensinogen into angiotensin I which is itself converted into angiotensin II by the angiotensin-converting enzyme.(Sisson 2010) Angiotensin II promotes drinking, vasomotor tone, and the production of aldosterone (to a lesser extent than in mammals) which causes water and sodium retention.(Smith et al. 2000) Aldosterone is also a mediator of inflammation and fibrosis. (Sisson 2010) Most clinical signs are the results of these compensatory mechanisms to restore and maintain cardiac output and blood pressure associated with an increase in preload and afterload. Furthermore the heart undergoes some changes (cardiac remodeling) in response to the hemodynamic challenges (pressure or volume overload) such as dilation and hypertrophy.(Sisson

2010) The increased preload leads to edema and effusion with the increased afterload further impairing cardiac output.

2. *Clinical findings*

Low cardiac output and limited cardiovascular adaptive abilities in response to exercise can cause exercise intolerance, syncope, tachycardia, cyanosis, decreased peripheral perfusion and arrhythmias. Since right heart failure is more common in birds, signs of fluid retention from the systemic circulation usually prevail and include ascites, hepatomegaly, pericardial effusion, jugular distension, and dyspnea from airsac compression. Pulmonary edema and congestion are associated with left heart failure.(Oglesbee & Oglesbee 1998) However, any cardiologic sign can be encountered in bilateral congestive heart failure. Pleural effusion is possible in birds but, if present, does not cause dyspnea. Fluid analysis will reveal either a pure or modified transudate. A moderate increase in bile acids due to hepatic congestion is common.

Electrocardiographic findings may include MEA deviations (usually right deviation), tachycardia, widened or tall P wave, atrial fibrillation, widened QRS complex, prominent R wave, widening of QT interval, and AV blocks.(Lumeij & Ritchie 1994; Olkowski et al. 1997) These changes are associated with delayed electrical conduction and chamber enlargement. Radiographs usually show a cardiomegaly with ascites and loss of abdominal airspace and details (Figure 11). The axillary diverticula of the interclavicular airsac may appear hyperinflated from volume compensation of the airsac system and severe dyspnea.

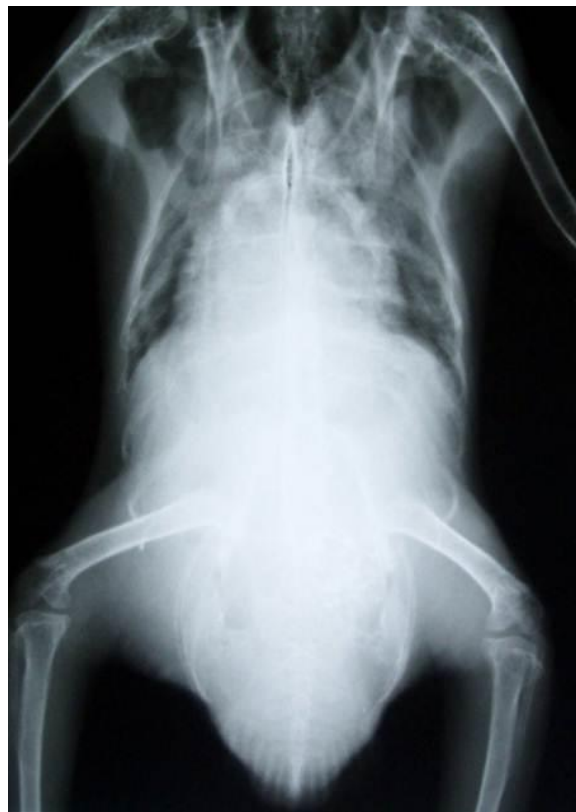

Figure 11: African grey parrot diagnosed with congestive heart failure. Radiographic findings include cardiomegaly (heart width to thoracic width ratio=71%), ascites, loss of abdominal details and airspace, hyperinflation of axillary diverticula.

Echocardiography is the definitive tool to diagnose congestive heart failure and ascites. Some degrees of pericardial effusion, right heart dilation and hepatic congestion are usually observed, along with valvular regurgitation and poor contractility (Figure 12). Angiocardiography will demonstrate an enlarged heart but is seldom indicated when considering other more practical imaging modalities.

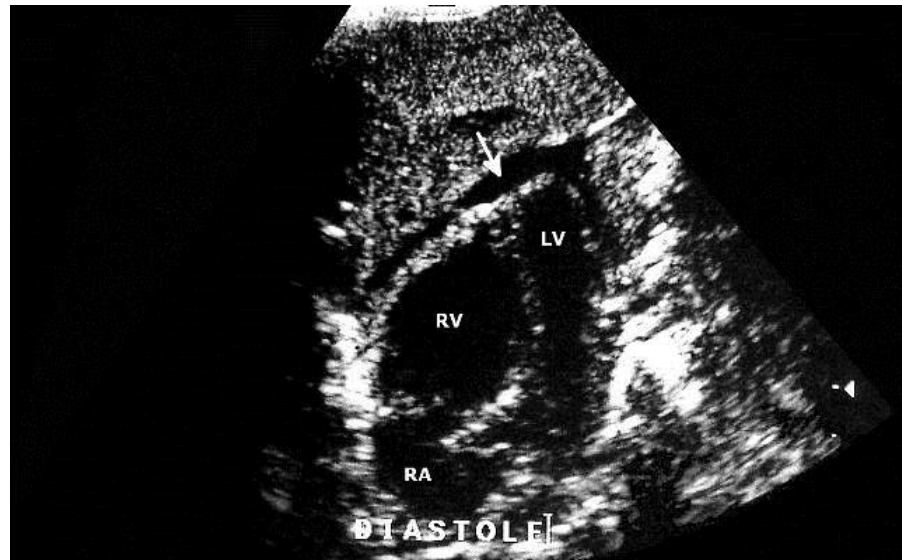

Figure 12: Four chamber horizontal view echocardiography in an African grey parrot with congestive heart failure. RV, right ventricle; LV, left ventricle; RA, right atrium; arrow, pericardial effusion

iii. Arrhythmias

Alterations of the ECG are common but do not always correlate with clinical signs and are rarely primary disease processes in birds. Arrhythmias can be classified into excitability disturbances and conduction disturbances. Reported arrhythmias in birds are summarized in Table 13.

Excitability disturbances have various causes and are common with dilated cardiac chambers and organic diseases. Atrioventricular blocks are associated with disrupted conduction between the sinoatrial and atrioventricular node where the conduction can be delayed (first degree), fail to propagate to the AV node (second degree), or be independent from the AV node (third degree) during which, an atrioventricular escape rhythm can occur. Second degree AV block may be characterized as Mobitz type 1 (PR progressively lengthening prior to block) usually caused by excessive vagal tone and atropine responsive and Mobitz type 2 (constant PR) often initiated by diseases of the His bundle and is non-responsive to atropine. Atrioventricular blocks are normally found in certain avian species and may occur with some frequency during anesthetic events. However, a drop in blood pressure or clinical signs associated with AV blocks are abnormal. Syncope has been reported in a Moluccan cockatoo (*Cacatua moluccensis*) and during hypotensive episodes in a Hispaniolan Amazon parrot (*Amazona ventralis*) with second degree AV block. (Van Zeeland et al. 2010; Rembert et al. 2008) Hypotension associated with 2nd degree AV blocks was observed following dobutamine administration in four Hispaniolan

Amazon parrots.(Schnellbacher et al. 2012) A bundle branch block was associated with lead toxicosis in a galah cockatoo (*Eolophus roseicollis*). (Westerhof et al. 2011)

In addition, various waves alterations have been associated with cardiac chamber enlargement, toxicities, nutritional imbalances, electrolytic disorders, and infectious agents.(Lumeij & Ritchie 1994; Sturkie 1976)

Table 13: Selected arrhythmias and some documented causes in birds.(Lumeij & Ritchie 1994; Westerhof et al. 2011; Sturkie 1976; Zandvliet 2005; van Zeeland et al. 2010; Rembert et al. 2008; Aguilar et al. 1995; Kushner 1999; Martinez et al. 1997; Odom et al. 1991; Cote & Ettinger 2005)

Arrhythmias	ECG changes	Causes
Excitability disturbances		
Respiratory sinus arrhythmia	Slowing of HR during expiration	Physiologic
Sinus bradycardia	Low HR. normal sinus rhythm	Vagal stimulation, atropine, anesthesia, hypokalemia, hyperkalemia, Vitamins E and B1 deficiency, acetylcholinesterase inhibitors
Sinus tachycardia	High HR, normal sinus rhythm	Sympathetic, catecholamine stimulation
Atrial tachycardia	Series of fast atrial extrasystoles	Atrial distension, ectopic foci
Atrial fibrillation	Absent P wave, irregular SS intervals	Atrial enlargement, cardiac disease
Ventricular premature Contraction (VPC)	Wide, bizarre QRS unrelated to P	Ectopic foci, hypo/hyperkalemia, Vitamin B1 and E deficiency, paramyxovirus 1, avian influenza, myocardial infarction
Ventricular tachycardia	Series of VPC	Similar causes as for VPCs
Ventricular fibrillation	Chaotic ventricular depolarization	Myocardial hypoxia, shock, severe disorders
Conduction disturbances		
1 st degree AV block	Long PR intervals	Anesthetics, increased vagal tone
2 nd degree AV block	Long PR intervals, some P without QRS	Anesthetics, increased vagal tone, occasionally normal in pigeons, parrots, raptors
3 rd degree AV block	Escape ventricular rhythm (slow and bizarre QRS), no consistent PR	Severe cardiomegaly
Bundle branch block	Short PR, bizarre and widened QRS	Lead, myopathy, myocarditis, uncommon in birds

iv. Valvular diseases

Valvular diseases appear more prevalent with the right than the left atrioventricular valve, which frequently results in insufficiency. This valve responds to right ventricular dilation by thickening and readily acquires insufficiency because of its fixed position on the ventricular wall.(Lumeij & Ritchie 1994; Pees, Krautwald-Junghanns, et al. 2006; Julian 2002; Oglesbee & Oglesbee 1998; Krautwald-Junghanns et al. 2004) A congenital valvular fissure was reported in a blue-fronted Amazon parrot (*Amazona aestiva*) with congestive heart failure.(Pees et al. 2001) Left atrioventricular valve insufficiency has been reported in an Indian ringneck parakeet (*Psittacula krameri*) with valvular myxomatous degeneration, an Indian hill mynah (*Gracula religiosa*), and a Pukeko (*Porphyrio melanotus*) with valvular endocardiosis.(Oglesbee & Lehmkuhl 2001; Rosenthal & Stamoulis 1993; Beehler et al. 1980) Endocardiosis is a non-inflammatory nodular thickening of the valves and is more commonly diagnosed on the left atrioventricular valve in birds. It is a common lesion of chickens and is a frequent occurrence in the ascites syndrome.(Crespo & Shivaprasad 2008; Fletcher & Abdul-Aziz 2008) Valvular stenosis is not common in birds but has been reported in a duck.(Mitchell et al. 2008) Idiopathic valvular degeneration may also occur.

In addition, valvular endocarditis is a common manifestation of bacterial cardiac infections, may result from chronic infections, and lead to septic emboli.(Lumeij & Ritchie 1994; Isaza et al. 1992; Jessup 1980) The left atrioventricular valve appears more often affected than the right.(Schmidt et al. 2003) In severe cases, *Trichomonas* can colonize the atrioventricular valves in pigeons.(Lumeij & Ritchie 1994) A variety of bacterial agents have been isolated from hearts of birds diagnosed with valvular endocarditis (Table 14, endocarditis).

In cases of significant insufficiency, a systolic murmur may be audible on cardiac auscultation. Complete blood cell count may reveal a leukocytosis and blood culture can be performed to attempt isolation of a bacterial organism. Cardiomegaly may be evident in advanced cases on radiographic images along with signs of congestive heart failure. Valvular vegetative growths may be identified on a cardiac ultrasound examination and signs of congestive heart failure, valvular regurgitation (Doppler echocardiography), and myocardial dysfunction may also be evident.

v. Myocardial diseases

Dilated cardiomyopathy refers to primary myocardial disorders leading to a dilated heart. Due to volume overload, the cardiac chambers usually dilate during congestive heart failure but this should not be confused with dilated cardiomyopathy. Spontaneous dilated cardiomyopathy is a well-known disorder of 1-4 week old turkeys. The exact cause of the disease is unknown in turkeys but it is associated with rapid growth and production. Genetic factors, previous myocarditis, hypoxia during incubation, and other environmental and dietary factors have also been proposed to play a role in the etiology.(Charlton et al. 2006; Julian 2005; Crespo & Shivaprasad 2008) Gross findings include a large right ventricle with thin walls and signs of congestive heart failure. Histopathologic lesions include degeneration of myofibers with vacuolation, secondary endocardiosis, focal infiltration of lymphocytes, and secondary changes in the liver.(Crespo & Shivaprasad 2008; Fletcher & Abdul-Aziz 2008) On the ECG, the following changes, associated with dilation and hypertrophy of the ventricles, can be identified: increased R wave amplitude, negative T wave, and rotation of the mean electrical axis.(Martinez et al. 1997; Czarnecki & Good 1980) Chicken round heart disease is characterized by an enlarged heart, hypertrophy of the left ventricle, and myofiber degeneration but currently the

disease is extremely rare.(Crespo & Shivaprasad 2008) In other avian species, the diagnosis of dilated cardiomyopathy is unclear. A red-tailed hawk (*Buteo jamaicensis*) was reported with primary right dilated cardiomyopathy and concurrent plasma troponin I elevation. No valvular regurgitation or other potential causes could not be identified with that case.(Knafo et al. 2011) A macaw was also diagnosed with lesions compatible with right dilated cardiomyopathy.(Oglesbee & Oglesbee 1998) In addition, some cases of left dilated cardiomyopathy have been diagnosed in pet birds.(Schmidt et al. 2003) Dilated cardiomyopathy is best diagnosed by echocardiography and is characterized, apart from chamber enlargement, by poor contractility and systolic dysfunction.

Hypertrophic cardiomyopathy has been poorly documented in birds.(Schmidt et al. 2003; Krautwald-Junghanns et al. 2004; Oglesbee & Oglesbee 1998) On echocardiography, hypertrophic cardiomyopathy shows the ventricular lumen with diminished dimensions, thickened ventricular walls, and diastolic dysfunction. Restrictive cardiomyopathy has not been reported in birds. Ischemic cardiomyopathy and myocardial infarction is rare overall but has been documented in several cases in relation to atherosclerosis (see corresponding section p69).

Myocarditis can occur with a variety of infectious agents (Table 14). In North American birds of prey, West Nile virus infection seems to be a common cause of myocarditis.(Ellis et al. 2007; Saito et al. 2007) In psittacines, myocarditis with cell infiltration of Purkinje fibers can be present in up to 79% of proventricular dilation disease cases.(Gancz et al. 2012; Lumeij & Ritchie 1994; Krautwald-Junghanns et al. 2004) Iron storage disease can induce myocarditis but, only in mynahs (*Gracula religiosa*) has this disease been suspected to lead to clinical myocardial disorders.(Ensley et al. 1979; Morris et al. 1989) Electrocardiographic changes usually accompany myocarditis due to increased excitability (Table 13).

Myocardial degeneration often results from nutritional deficiencies (vitamin E / selenium), toxicities (Table 15), or ischemia.(Schmidt et al. 2003) A fatal disease primarily characterized by myocardial degeneration has been reported in great billed parrot (*Tanygnathus megalorynchos*) along with skeletal muscle and neural lesions resembling vitamin E deficiency.(Schmidt et al. 2003)

vi. Pericardial diseases

Pericardial effusion is common with congestive heart disease in birds and can precipitate decompensation if cardiac tamponade occurs.(Lumeij & Ritchie 1994; Pees, Krautwald-Junghanns, et al. 2006) Cardiac tamponade first affects the right heart diastolic function because of the lower pressure. Pericardial effusion can also be caused by hypoproteinemia, exudative pericarditis, hemorrhage, atrial rupture, coagulopathy, neoplasm, and idiopathic syndromes. Viral causes of hydropericardium producing transudates have been recorded (Table 14). Avocado toxicity can also induce pericardial effusion.(Hargis et al. 1989) Right auricle rupture leads to hemopericardium and sudden death in poultry.(Crespo & Shivaprasad 2008; Bougiouklis et al. 2005) Pericardial fluid analysis and culture may be helpful to pinpoint a cause when primary cardiac disease is not suspected. Pericardial fluid can be collected by endoscopy through a midline approach or guided by ultrasound.(Straub et al. 2003) Pericardial biopsies may also be valuable in some cases. A permanent surgical window or partial pericardectomy can be performed if necessary by endoscopy.(Lumeij & Ritchie 1994) Enlargement of the cardiac silhouette is observed radiographically but may not be differentiable from true cardiomegaly (Figure 13). Echocardiography will readily diagnose pericardial effusion (Figure 12).

Electrocardiographic findings may include left axis deviation and low voltage.(Lumeij & Ritchie 1994)

Pericarditis has been associated with a variety of infectious agents (Table 14). Clinical signs are usually non-specific but fibrinous pericarditis can result in constrictive pericarditis. Pericardial filarioids have also been documented in birds including cockatoos housed outdoors.(Greiner & Ritchie 1994; Greenacre et al. 1993) Uric acid deposits on the pericardium are common with visceral gout and should not be confused with infectious pericarditis. Echocardiography is of low value to diagnose pericardial diseases without effusion. In these cases endoscopy and direct visualization of the pericardium is more sensitive.

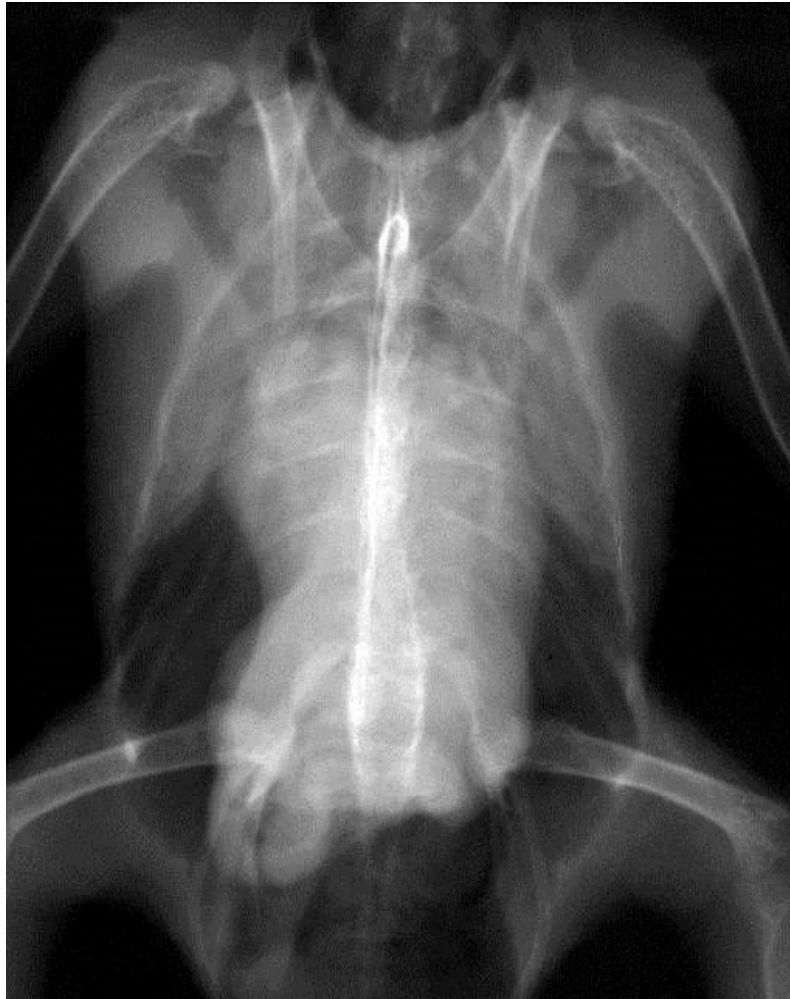


Figure 13: Ventrordorsal radiograph of an African grey parrot showing a widened cardiac silhouette caused by pericardial effusion.

vii. Infectious and parasitic

The different bacterial, viral, fungal, and parasitic agents reported to cause cardiovascular disorders are summarized in Table 14.

Table 14: Infectious agents reported to cause cardiovascular lesions in birds

Pericarditis / Epicarditis	Myocarditis
<i>Listeria monocytogenes</i>	<i>Escherichia coli</i>
<i>Riemerella anatipestifer</i> (turkeys, ducks)	<i>Salmonella</i> spp.
<i>Chlamydophila psittaci</i>	<i>Listeria monocytogenes</i>
<i>Mycoplasma gallisepticum</i>	<i>Pasteurella multocida</i>
<i>Salmonella</i> spp.	<i>Mycobacterium</i> spp.
<i>Escherichia coli</i>	<i>Aspergillus</i> spp.
<i>Mycobacterium</i> spp.	West Nile virus
<i>Aspergillus</i> spp.	Eastern equine encephalitis virus
<i>Trichomonas gallinae</i> (pigeons)	Avian leucosis virus
Reovirus	Parvovirus (geese and Muscovy ducks)
Endocarditis	Avian encephalomyelitis virus
<i>Enterococcus</i> spp.	Reovirus
<i>Streptococcus</i> spp.	Avian paramyxovirus 1
<i>Staphylococcus</i> spp.	Avian influenza
<i>Pasteurella multocida</i>	Proventricular dilation disease (ABV)
<i>Erysipelothrix rhusopathiae</i>	<i>Sarcocystis</i> spp.
<i>Pseudomonas aeruginosa</i>	<i>Leucocytozoon</i> spp.
<i>Escherichia coli</i>	<i>Toxoplasma gondii</i>
Reovirus	<i>Atoxoplasma serini</i> (canaries)
Intravascular / intracardiac parasites	Pericardial effusion
<i>Trichomonas gallinae</i> (pigeons)	Fowl adenovirus (serotype IV)
<i>Splendidofilaria</i> spp.	Reovirus
<i>Chandlerella</i> spp.	Polyomavirus
<i>Cardiofilaria</i> spp.	Cardiac neoplasias
<i>Paronchocerca</i> spp.	Marek's disease virus
<i>Sarconema</i> spp. (swans, geese)	Avian leukosis virus
Schistosomes (geese)	Reticuloendotheliosis virus

Blood culture is the diagnostic test of choice for bacterial cardiopathies. Specific viral diagnostic tests can also be performed depending on the infectious dynamic of the agent. Electrocardiographic changes have been recorded in some instances. Cardiac parasites that can

be encountered include myocardial protozoans and filarioid nematodes living in cardiac chambers, vessels, and body cavities.(Bartlett 2008; Greenacre et al. 1993; Latimer et al. 1990) These parasites infest mainly birds housed outside where they get exposed to definitive hosts (cats, opossums) and arthropod hosts or mechanical vectors (cockroaches, simuliids, mosquitoes). Examinations of blood smears and buffy coats may be helpful.

viii. Congenital

Congenital diseases are rare and include atrial or ventricular septal defects and valvular stenosis. Some defects may be functionally closed. Cockatoos seem to have a higher prevalence of congenital defects than other psittacine species.(Schmidt et al. 2003; Evans et al. 2001) In addition, persistent *truncus arteriosus* and aortic hypoplasia have been reported in combination with septal defects in 2 cockatoos.(Evans et al. 2001) In these two cockatoos, an audible murmur and tachycardia were present on cardiac auscultation and an ante-mortem diagnosis could be reached with a cardiac ultrasound examination. A congenital valvular defect was suspected in a blue-fronted Amazon parrot.(Pees et al. 2001) Congenital and toxin-induced cardiac malformations have also been reported in the chicken and turkey.(Siller 1958; Einzig et al. 1972) A ventricular septal defect was reported in a tundra swan (*Cygnus columbianus*), a Houbara bustard (*Chlamydotis undulata*), and a Griffon vulture (*Gyps fulvus*).(Harari & Miller 1983; Bailey & Kinne 2001; Risi et al. 2011) A duck presenting an audible murmur was diagnosed with congenital mitral stenosis and subvalvular aortic stenosis by echocardiography.(Mitchell et al. 2008) Ventricular or atrial septal defects associated with heart murmurs were diagnosed in 8/111 Mississippi sandhill cranes (*Grus canadensis pulla*) in a mortality survey at the Patuxent Wildlife Research Center.(Olsen et al. 1997)

Bifid sternum in which the sternum is split longitudinally thereby exposing the heart to external trauma has been reported in 3 African grey parrots (*Psittacus erithacus*) and an orange-winged Amazon parrot (*Amazona amazonica*).(Buerkle & Wust 2010; Bennett & Gilson 1999)

ix. Aneurysm and aortic rupture

Arterial aneurysm is a focal, blood filled dilation of the arterial wall communicating with the arterial lumen and may be caused in birds by atherosclerosis, copper deficiency, hypertension, and fungal infection.(Vink-Nooteboom et al. 1998; Grosset et al. 2012; Ferreras et al. 2001; Baptiste et al. 1997; Courchesne & M. Garner 2009; Vanhooser et al. 1994; Mitchinson & Keymer 1977) Non-atherosclerotic aneurysms with aortic dissection and rupture are mainly seen in ostriches (*Struthio camelus*) and turkeys (*Meleagris gallopavo*).(Mitchinson & Keymer 1977; Vanhooser et al. 1994; Ferreras et al. 2001; Baptiste et al. 1997; Gresham & Howard 1961; Crespo & Shivaprasad 2008) The exact cause of aortic dissecting aneurysm is not known in these two species. However, systemic hypertension (common in meat-type turkeys, especially young males), genetic factors, connective tissue disorders, peas in the ration (peas' toxin β -aminopropionitrile will cause aortic rupture experimentally by interference with collagen formation), and dietary deficiencies notably in copper may contribute to the pathogenesis.(Charlton et al. 2006; Crespo & Shivaprasad 2008; Julian 2002; Simpson et al. 1970) A copper-dependent enzyme is needed for connective cross-linking of collagen and elastin in the arterial wall.(Schmidt et al. 2003)

x. Toxicity

Documented cardiotoxins in birds are summarized in Table 15.

Table 15: Selected cardiotoxic compounds in birds. *Note/ Toxicities may vary by species, especially for plant toxins. Some toxin effects are poorly documented in birds.*

Toxic	Effect	References
Dietary and phytotoxins		
Avocado (persin)	Pericardial effusion	(Hargis et al. 1989; Burger et al. 1994)
Sweet pea (β -aminopropionitrile)	Aneurysm	(Simpson et al. 1970)
Lily of the valley (glycosides)	Tachycardia, arrhythmias	(Lightfoot et al. 2008)
Oleander (glycosides)	Tachycardia, arrhythmias	(Lightfoot et al. 2008; Shropshire et al. 1992)
<i>Kalanchoe</i> (glycosides)	Tachycardia, arrhythmias	(Lightfoot et al. 2008)
<i>Cassia</i>	Myocardial degeneration and necrosis	(Fletcher et al. 2008)
<i>Crotalaria</i> (pyrrolizidine, monocrotaline)	Ascites, hydropericardium	(Fulton 2008)
Rapeseed (erucic acid, glucosinolate)	Ascites, hydropericardium, fatty changes	(Fulton 2008)
Chocolate (theobromine, caffeine)	Tachycardia, hypertension, arrhythmias	(Lightfoot et al. 2008; Dumonceaux et al. 1994)
Alcohol	Fatty changes	(Fulton 2008)
Moniliformin (<i>Fusarium</i> mycotoxin)	Myocardial degeneration and necrosis	(Hoerr 2008)
Iron	Oxidative myocardial injury	(Ensley et al. 1979; Morris et al. 1989)
Sodium	Congestive heart failure	(Jullian 2002)
Potassium	Arrhythmias, hypertrophy and degeneration of myofibers	(Fletcher et al. 2008)
Vitamin D3	Cardiac mineralization	(Fletcher et al. 2008)
Environmental toxins		
Lead / Zinc	Conduction abnormalities, hydropericardium (geese, swans), myocardial necrosis	(Degernes 2008; Redig et al. 2008; Westerhof et al. 2011)
Organochlorines	Cardiac malformation	
Organophosphates/carbamates	Bradycardia	(Redig et al. 2008)
Iatrogenic toxins		
Furazolidone (nitrofurantoin)	Dilated cardiomyopathy	(Czarnecki 1986)
Ionophores (monensin, salinomycin)	Myocardial degeneration and necrosis	(Fletcher et al. 2008; Fulton 2008)
Antipsychotic (haloperidol)	Bradycardia, hypotension	(Martin 2006)
Lidocaine/bupivacaine	Arrhythmias, hypotension	(da Cunha et al. 2011)
Doxorubicin	Cardiomyopathy, arrhythmias	(Gilbert et al. 2007; Czarnecki 1986)

i. Neoplasms

Cardiovascular neoplasms are rare in birds. Oncogenic viruses can induce various cardiac tumor formations in chickens (Table 14). A vascular hemangiosarcoma arising from the right internal carotid artery was reported in a double yellow headed Amazon parrot (*Amazona ochrocephala oratrix*). (Hanley et al. 2005) Hemangiomas and are often present as a cutaneous growth. (Reavill & Dorrestein 2010)

D. Treatment and management

i. Prognosis

Once an avian patient is diagnosed with cardiovascular diseases, the long-term prognosis is poor, even with treatment. For instance, a review of 14 clinical cases of congestive heart failure in birds showed a median survival time of 32.5 days (Table 16).

Table 16: Survival time of selected avian cases of congestive heart failure (CHF) after diagnosis. AV, atrioventricular.

Species	Diagnosis	CHF	Treatment	Survival time	Reference
African grey parrot	Atherosclerosis Cor pulmonale	Right	Furosemide Spironolactone Benazepril Pimobendan Coelomocentesis	35 days	(Sedacca et al. 2009)
African grey parrot	Valve regurgitations, hyperechoic aorta	Bilateral	Pimobendan Furosemide Imidapril	30 days	(Beaufreire et al. 2007)
Indian ringneck parakeet	Myxomatous degeneration of left AV valve	Bilateral	Furosemide Digoxin	10 months	(Oglesbee et al. 2001)
Amazon parrot	Right AV valve insufficiency	Right	Furosemide Digoxin	8 days	(M Pees et al. 2001)
Amazon parrot	Right AV valve insufficiency	Right	Enalapril Furosemide	27 months	(M Pees et al. 2006)
Blue and gold macaw	Atherosclerosis	Right	Furosemide	70 days	(Phalen et al. 1996)
Grey-cheeked parakeet	Atherosclerosis	Right	Supportive	3 days	(Mans et al. 2007)
Umbrella cockatoo	Atherosclerosis Coronary aneurysm	Right	Supportive	Euthanized at diagnosis	(Vink-Nooteboom et al. 1998)
Fischer lovebird	Pericardial effusion Pericarditis, myocarditis	Right	Pericardiocentesis Enalapril Furosemide	11 months	(Straub et al. 2003)

(Table 16 continued)

Species	Diagnosis	CHF	Treatment	Survival time	Reference
Pukeko	Left AV valve insufficiency	Bilateral	Digoxin	49 days	(Beehler et al. 1980)
Red-tailed hawk	Dilated cardiomyopathy	Right	Furosemide	Euthanized at diagnosis	(Knafo et al. 2011)
Mynah	Left AV valve insufficiency	Bilateral	Furosemide Digoxin	10 months	(Rosenthal et al. 1993)
Mynah	Coronary calcification Cause not determined	Right	Abdominocentesis	12 days	(Ensley et al. 1979)
Duck	Congenital left AV valve stenosis Subvalvular aortic stenosis	Bilateral	Supportive Furosemide Coelomocentesis	29 days	(Mitchell et al. 2008)

The variety of therapeutic treatments, causative conditions, outcomes, and species hamper the formation of any conclusion regarding the association between therapeutic protocols and survival time. In small animals, long-term prognosis for congestive heart failure is also poor with dogs having a median survival times of 27-133 days for dilated cardiomyopathy and 588 days for preclinical mitral valve disease.(Tidholm et al. 1997; Borgarelli et al. 2012; Martin et al. 2009) The shorter survival time in birds may be associated with the paucity of pharmacologic information on cardiac drugs, poor standardization of treatment protocols, greater cardiac efficiency and metabolism, diagnoses achieved at advanced clinical stages, and the challenges of long term treatment in birds.

ii. Therapeutics

Therapeutic management is the cornerstone of cardiac disease management and is directed toward the heart, vessels, and regulation of volemia. In general, goals are to extend the patient's quality of life and survival time. Since congestive heart failure is not a diagnosis, the correct treatment will also depend on an accurate diagnosis of the underlying cause of heart failure. There is a scarcity of pharmacologic information on cardiovascular agents in companion birds. Few pharmacokinetic studies have been performed (Table 17) but no clinical trials are available. This emphasizes the need for therapeutic drug monitoring when possible when treating the individual avian patient. Several commercial laboratories offer plasma drug measurements including those for digoxin or carvedilol.

Diuretics are used to reduce fluid overload, edema, and effusion. The reduction of vascular volume is a double-edged sword where the decrease in organ congestion and edema should be counterbalanced with the decrease in the cardiac output. In a study in chickens, urine output was measured after administration of the diuretics furosemide, spironolactone, hydrochlorothiazide, and urotropin.(Esfandiary et al. 2010) Furosemide had the greatest diuretic effect, especially when given parenterally. Other diuretics did not have a greater effect than the control group at the dosage used. Loriinae may be extremely susceptible to furosemide and doses used in these species should be lower.(Hawkins et al. 2013) Furosemide is a potent loop diuretic with good

efficiency and rapid onset of action in birds despite the presence of only 10-30% of looped nephrons in the avian kidney.(Goldstein & Skadhauge 2000) Cardiac tamponade is a contraindication for the use of furosemide because of its effect on cardiac output and it should be used with caution in birds with renal diseases. Hypokalemia is a possible side-effect.(Pees, Krautwald-Junghanns, et al. 2006; Schroeder 2010) Electrolytes and renal parameters (BUN, uric acid) should be monitored when chronically using furosemide on an avian patient. Spironolactone, an aldosterone antagonist, is a potassium-sparing diuretic which decreases myocardial fibrosis. It may be used concomitantly with furosemide to offset the loss of potassium. Hyperaldosteronism is one of the key compensatory mechanisms leading to congestive heart failure. Overall, spironolactone is considered a weak diuretic.(Schroeder 2010) Furosemide should not be used alone in the long term but combined to an ACE inhibitor as it further activates the RAAS.(Schroeder 2010)

Angiotensin-converting enzyme (ACE) inhibitors block the formation of angiotensin II, which promotes venous and arterial vasodilation and blocks aldosterone production. This reduces pre and afterload but hypotension and hyperkalemia are potential side-effects and ACE inhibitors are contraindicated for cardiac tamponade.(Bulmer 2010) Enalapril and benazepril are the most commonly used ACE inhibitors (Table 17) because of their longer half-life. Empirical evidence suggest that enalapril is safe and effective in companion psittacine birds.(Pees, Kuhring, et al. 2006)

Positive inotropes are used to enhance cardiac contractility. Disadvantages of positive inotrope use include an increase in myocardial oxygen consumption, arrhythmias (except pimobendan), and are contraindicated in cases of hypertrophic cardiomyopathy. Digoxin is a digitalis glycoside which enhances contractility by inhibiting Na/K ATPase pump promoting intracellular sodium thus Na/Ca exchange results in an increase calcium cytosolic concentration.(Fuentes 2010) Several pharmacokinetic studies exist in birds and digoxin has been used in several cases with monitoring of plasma levels (Table 17).(Oglesbee & Lehmkuhl 2001; Beehler et al. 1980; Rosenthal & Stamoulis 1993) Digoxin is a positive inotrope, negative chronotrope, and positive lusitrope. However, the use of digoxin is becoming more controversial in small animal and human cardiology because of the failure to reduce overall mortality and is mainly indicated to treat atrial fibrillation. Digoxin is a weak positive inotrope and side-effects are common, therapeutic levels are 0.8-1.2 ng/mL in humans and dogs.(Fuentes 2010) Pimobendan is a positive inotrope and arterial vasodilator (inodilator) with its mode of action associated with calcium sensitization of myofibrils and phosphodiesterases III inhibition.(Beaufrère & Pariaut 2009; Guzman et al. *in press*; Fuentes 2010) Pimobendan is commonly used in small animal cardiology and has been shown to increase both survival time and quality of life in canine dilated cardiomyopathy.(Summerfield et al. 2012) There has been more clinical trials with pimobendan than with any other drug in veterinary cardiology. However, only in 2 psittacines cases has the use of pimobendan been reported at a dose of 0.25-0.6 mg/kg q12h in triple therapy achieving mixed results.(Sedacca et al. 2009; Beaufrere et al. 2007) However, the required pimobendan dose appears to be much higher in parrots and this may partially explain the poor clinical effect.(Guzman et al. *in press*) Dobutamine is a potent positive inotrope that exerts its activity by selective β_1 adrenergic activity. Since it is short-lived, it is used as a constant rate infusion (CRI) in refractory cases with severe systolic dysfunction and cardiogenic shock. In Amazon parrots, dopamine and dobutamine significantly increased the blood pressure in a dose-dependent manner.(Schnellbacher et al. 2012) Side-effects of dobutamine treatment include arrhythmias and tachycardia.

Beta-blockers (e.g. carvedilol, atenolol, propranolol) and calcium channel blockers (e.g. diltiazem) are negative inotropes. They are mainly used in the treatment of hypertrophic cardiomyopathy and supraventricular arrhythmias and tachycardia. Side-effects include bradycardia and hypotension.

The initial treatment of congestive heart failure with severe clinical signs aims to achieve a marked reduction in volemia mainly through the use of diuretics and vasodilators (trap blood in venous system which already contains 70% of total blood volume). Oxygen supplementation should be instituted for dyspneic animals especially if pulmonary edema is present. Injectable inotropes and vasodilators may be indicated in anorexic patients. Fluid therapy is not indicated in the initial treatment of congestive heart failure where the goal is to reduce fluid overload but can be instituted at low dose once cardiac function has improved if dehydration and azotemia are present. Combination therapy with furosemide, ACE inhibitor and pimobendan can then be initiated and are the consensus recommendations for long-term treatment of canine chronic valvular disease.(Keene et al. 2010) The diuretic dose can then be tapered to the lowest effective level. Beta-blockers can be used in supraventricular tachycardia and atrial fibrillation. Multiple diuretic therapies may be necessary to control effusion formation and limit side effects.

Furthermore moderate sodium restriction is recommended. Coelomocentesis is indicated to relieve respiratory signs due to airsac compression and is an effective means of decreasing volume overload. Coelomocentesis can be performed on a regular basis for chronic treatment of right heart failure in birds. Pericardiocentesis (guided by endoscopy or ultrasound) is indicated in severe pericardial effusion and cardiac tamponade. Slow aspiration is essential.

Table 17: Doses of selected cardiac therapeutic agents in birds. PK, pharmacokinetic study; PD, pharmacodynamics study; EU, empirical use.

Drug	Species	Dose		Reference
Diuretics				
Furosemide	Parrots,	0.15-2 mg/kg PO,	EU	(Pees, Krautwald-
	raptors	IM q12-24h	PD	Junghanns, et al. 2006)
	Chickens	5 mg/kg PO	PD	(Esfandiary et al. 2010)
		2.5 mg/kg IM		(Esfandiary et al. 2010)
Spironolactone	Chickens	1 mg/kg PO	PD	(Esfandiary et al. 2010)
	Parrots	1 mg/kg PO q12h	EU	(Sedacca et al. 2009)
Positive inotropes				
Digoxin	Budgerigars	0.02 mg/kg PO q24h	PK	(Hamlin & Stalnaker 1987)
	Sparrows	0.02 mg/kg PO q24h	PK	(Hamlin & Stalnaker 1987)
	Quaker	0.05 mg/kg PO q24h	PK	(Wilson et al. 1989)
	parrots			
Pimobendan	Amazon	10 mg/kg PO q12h	PK	(Guzman et al. n.d.)
	parrots	0.25 mg/kg PO q12h	PK,	(Guzman et al. n.d.)
	Harris hawk	0.25 mg/kg PO q12h	EU	(Sedacca et al. 2009; van
	Parrots		EU	Zeeland et al. 2010)
Dobutamine	Amazon	5-15 µg/kg/min	PD	(Schnellbacher et al. 2012)
	parrots	(CRI)		
Dopamine	Amazon	5-10 µg/kg/min	PD	(Schnellbacher et al. 2012)
	parrots	(CRI)		

(Table 17 continued)

Drug	Species	Dose	Reference	
Negative inotropes				
Propranolol	Most species	0.2 mg/kg IM, 0.04 mg/kg IV	EU	
Atenolol	Most species	5-10 mg/kg PO q12-24h	EU	
Diltiazem	Most species	1-2 mg/kg PO q8-24h	EU	
Vasodilators				
Enalapril	Pigeons	1.25 mg/kg PO q12-8h	PK	(Pees, Kuhring, et al. 2006)
	Amazons		PK	(Pees, Kuhring, et al. 2006)
	Parrots	1.25 mg/kg PO q12-8h	EU	(Straub et al. 2003; Pees, Schmidt, et al. 2006)
		2.5-5 ,g/kg PO q12h		
Benazepril	Parrots	0.5 mg/kg PO q24h	EU	(Sedacca et al. 2009)
Parasympatholytics				
Atropine	Most species	0.01-0.02 mg/kg IM	EU	
Glycopyrrolate	Most species	0.01-0.02 mg/kg IM	EU	
Antiarrhythmics				
Lidocaine	Amazon parrot	2.5 mg/kg IV	PK	(da Cunha et al. 2011)
Mexiletine	Parrots	4-8 mg/kg PO q12-24h	EU	
Proprantheline	Parrots	0.1-0.3 mg/kg PO q8h	EU	(van Zeeland et al. 2010)

II. Atherosclerosis in mammals

A. Pathogenesis

i. Response to injury hypothesis and endothelial dysfunction

Atherosclerosis is an inflammatory and degenerative disease of the arterial wall characterized by the disorganization of the arterial intima due to the accumulation of inflammatory cells, fat, cholesterol, calcium, cellular debris, and inflammatory cells, potentially leading to complications such as stenosis, ischemia, thrombosis, hemorrhage, and aneurysm.

The etiology and development of the atherosclerotic lesions can be broadly explained by the response-to-injury hypothesis first proposed by Ross et al. (Ross et al. 1977). While this widely accepted hypothesis has been constantly refined, it postulates that damage to the endothelium lining of the artery sets the stage for atherogenesis. Direct mechanical damage to the endothelium such as endothelial denudation was initially thought to be required, but an increasing body of scientific evidence has highlighted the importance of endothelial dysfunction and oxidative stress in lesion initiation. (Cullen et al. 2005; Falk 2006; George & Lyon 2010; McGorisk & Treasure 1996; Poredos 2001)

Apart from the maintenance of vessel wall permeability, the endothelium participates in many physiologic processes and has hemodynamic, hemostatic, inflammatory, and endocrine functions. The endothelium regulates blood flow through secretion of mediators that affect

vascular hemodynamics and blood fluidity. Secreted vasoactive molecules include vasodilators such as nitric oxide (NO), prostacyclin (PGI₂) and vasoconstrictors such as endothelin-1 (ET-1) and platelet activating factor (PAF).(Cullen et al. 2005; Falk 2006; George & Lyon 2010; Cines et al. 1998; Sitia et al. 2010) NO and ET are some of the most potent vasodilators and vasoconstrictors known, respectively.(Poredos 2001) Nitric oxide has also protective effects against vascular injury, inflammation, thrombosis, and inhibits leukocyte adhesion and limits platelet adhesion and aggregation.(Szmitko et al. 2003; Cullen et al. 2005; Cines et al. 1998) Endothelial cells also produce an endothelium-derived hyperpolarizing factor (EDHF) that relaxes smooth muscles.(Cines et al. 1998) The endothelium provides an antithrombotic surface and limits local thrombosis by the production of tissue plasminogen activator, heparans, and thrombomodulin.(Cullen et al. 2005; Rabelink et al. 2010; Cines et al. 1998) Finally, endothelial cells express cell surface molecules that plays a role in blood cells trafficking and chemotaxis.(Cines et al. 1998) The endothelial surface molecules assists the direction of the migration of leukocytes during physiologic and pathologic processes.

Under certain circumstances, interactions with blood cells, and stimulation by cytokines and other inflammatory factors, the endothelium becomes activated and increases its production of procoagulant and proinflammatory factors such as tissue factor, Von Willebrand's factor, monocyte chemotactic factor-1, vascular cell adhesion molecule-1, and interleukin 1, 6, and 18.(Cullen et al. 2005; Hamburg & Vita 2005) During sustained endothelial-cell activation, endothelial microparticles containing a variety of proinflammatory agents and procoagulant factors may be released and endothelial cells may detach from the vessel wall and are referred to as circulating endothelial cells.(Rabelink et al. 2010) Ultrastructurally, activated endothelial cells are characterized by cytoplasmic volume increase, pinocytotic vesicles, filopodia, increased vacuolization, and blood cells attachment.(Cheville 1994b) Endothelial dysfunction is characterized by a specific state of endothelial activation and is associated with specific risk factors that promote an atherogenic environment.(Cullen et al. 2005) For instance, hypercholesterolemia promotes attachment of blood leukocytes to the endothelium, oxidized lipoproteins and reactive oxygen species cause endothelial activation and endothelial damage, and angiotensin II, associated with hypertension, antagonizes the effects of NO.(Szmitko et al. 2003) Several atherogenic risk factors such as dyslipidemia, diabetes, metabolic syndrome, smoking, inflammation, and hypertension increase oxidative stress which has been suggested as an important cause of endothelial dysfunction.(Poredos 2001; Stocker & Kearney 2005)

Endothelial dysfunction is initially characterized by a decrease in the production and bioavailability of NO coupled with an increase in vasoconstrictors such as with ET-1.(Cullen et al. 2005; George & Lyon 2010; Hamburg & Vita 2005; Szmitko et al. 2003) This leads to impairment of endothelium-derived vasodilation and promotion of a proinflammatory, proliferative, prooxidative, and procoagulatory state that is atherogenic.(Cullen et al. 2005; Szmitko et al. 2003; Sitia et al. 2010; Ross 1999) Impairment of endothelial vasodilator function may also play a role in the pathogenesis of tissue ischemia.(Poredos 2001) The decreased expression of NO, increased expression of selectins, vascular cell adhesion molecule-1 (VCAM-1) and intercellular adhesion molecule-1 (ICAM-1) promotes the adherence of monocytes and, to a lesser extent lymphocytes, and their migration into the subintimal space, which is one of the earliest events in atherogenesis (Figures 14 and 15).(Cullen et al. 2005; Szmitko et al. 2003; Poredos 2001; Libby 2012; Hansson 2005; Cybulsky & Gimbrone 1991) A dysfunctional endothelium fails to inhibit the proliferation and migration of smooth muscle cells.(Cullen et al. 2005) In addition, local factors such as hemodynamic shear stress and genetic factors are also

associated with endothelial dysfunction and platelet and leukocytes attachment to the endothelium.(Cullen et al. 2005; Cines et al. 1998) Once within the subintimal area, the monocytes differentiate into macrophages and begin internalization of lipoprotein particles and evolved into foam cells. Other cells contribute to atherosclerotic lesion formation such as smooth muscles cells, T-cells, dendritic cells, and mast cells. Furthermore, entrapment of low-density lipoproteins (LDL, apolipoprotein-B containing lipoproteins) in the arterial wall coupled with the increased permeability of the endothelium promotes the accumulation of lipid, the chemoattraction of macrophages, and the formation of foam cells. There is evidences that arterial extracellular matrix components such as proteoglycans can bind to LDL leading to LDL retention.(Stocker & Keaney 2005) This has been formulated as the response-to-retention hypothesis(Williams & Tabas 1998) but can also be considered part of the complex changes that can lead to initial vascular injury and subsequent effects on vascular physiology, homeostasis and endothelial dysfunction. Heightened oxidative stress in the arterial wall promotes the oxidization of lipoproteins which are readily taken up by macrophages. Oxidized LDL and other polypeptides are recognized as auto-antigens that have strong pro-inflammatory stimulus thereby sustaining chronic inflammation, leukocytes recruitment, immune activation, and endothelial dysfunction.(Sitia et al. 2010) The subendothelial retention of modified LDL is a key event in the early attraction of monocytes and their differentiation into macrophages.(Raines et al. 2005; Moore & Tabas 2011) Inflammation has a preponderant role in atherogenesis and intervenes in the effects of many known risk factors.(Libby et al. 2011; Hansson 2005)

ii. Cells of atherosclerosis and development of lesions

Proliferation and accumulation of macrophages is one of the main characteristics of atherosclerotic lesions and happens at all stages of lesion development with foam cell formation, secretion of signaling molecules, cytokines, inflammatory mediators, proteolytic enzymes, growth factors, reactive oxygen species, and components of the extracellular matrix.(Cullen et al. 2005; Moore & Rayner 2010; Moore & Tabas 2011; Ross 1999) Adhesion of macrophages and their diapedesis are mediated by chemoattractants, integrins, and adhesion molecules secreted by activated endothelial cells (VCAM, ICAM).(Moore & Tabas 2011) There is evidence that different subsets of macrophages (M1 and M2) may act at different levels of the inflammatory response occurring in atheromas.(Moore & Tabas 2011; Woollard & Geissmann 2010; Libby et al. 2011) Also, a large number of molecules contribute to LDL retention, modification, and uptake.(Moore & Rayner 2010; Williams & Tabas 1998) Modified lipoproteins have the ability to trigger key signaling pathways of inflammation and foam cell formation. Oxidized LDL and monocyte chemoattractant protein 1 (MCP-1), produced by endothelial cells, macrophages, and smooth muscles cells, are potent atherogenic chemoattractants.(Libby 2012) The proliferation of macrophages is upregulated by modified lipoproteins, macrophage growth factor, macrophage colony stimulating factor 1 (M-CSF), and cytokines (TNF- α , IFN- γ) produced by inflammatory cells.(Cullen et al. 2005; Raines et al. 2005) Macrophages express several scavenger receptors namely scavenger receptor A (SR-A), B1 (SR-B1), and CD36 implicated in uptake of oxidized LDL.(Cullen et al. 2005; George & Lyon 2010) Lipid accumulates within the macrophages and some expressed scavenger receptors (SR-A) are not subject to negative feedback regulation unlike the standard LDL receptors (see lipoproteins).(Cullen et al. 2005; Moore & Rayner 2010) Macrophages store cholesterol in the form of cholesteryl esters and become foam cells (Figure 14). Additionally, macrophages deal with excess cholesterol with various cholesterol efflux pathways including transfer to high-density lipoproteins (HDL) via SR-B1, transfer to apoA1

and apoE-containing lipoproteins (HDL) and to other cholesterol acceptors via ATP binding cassette A1 (ABCA-1) and ABCG-1 transporters, and shedding of lipid rafts (Figure 15). (Cullen et al. 2005; Moore & Tabas 2011; Cuchel et al. 2010) Thus, SR-A seems to be atherogenic whereas SR-B1 and cholesterol efflux transporters are atheroprotective. (George & Lyon 2010) Cholesterol efflux is thought to be fundamental in lesion regression when risk factors are reduced. (Moore & Tabas 2011) With continuous exposure to excess cholesterol, adapting mechanisms of the macrophages eventually fail (particularly due to the absence of down-regulation of scavenger receptors by cellular cholesterol accumulation) and the cells die which may lead to further release of proteases and inflammatory molecules and accumulation of extracellular lipid and necrotic debris. Modified lipoproteins can also induce macrophage apoptosis. (Moore & Tabas 2011) Atherosclerosis is a non-resolving inflammatory condition where macrophages continue to enter lesions, accumulate cholesterol and modified lipoproteins and die by apoptosis or necrosis which ultimately lead to the necrotic core of the atheromatous plaque.

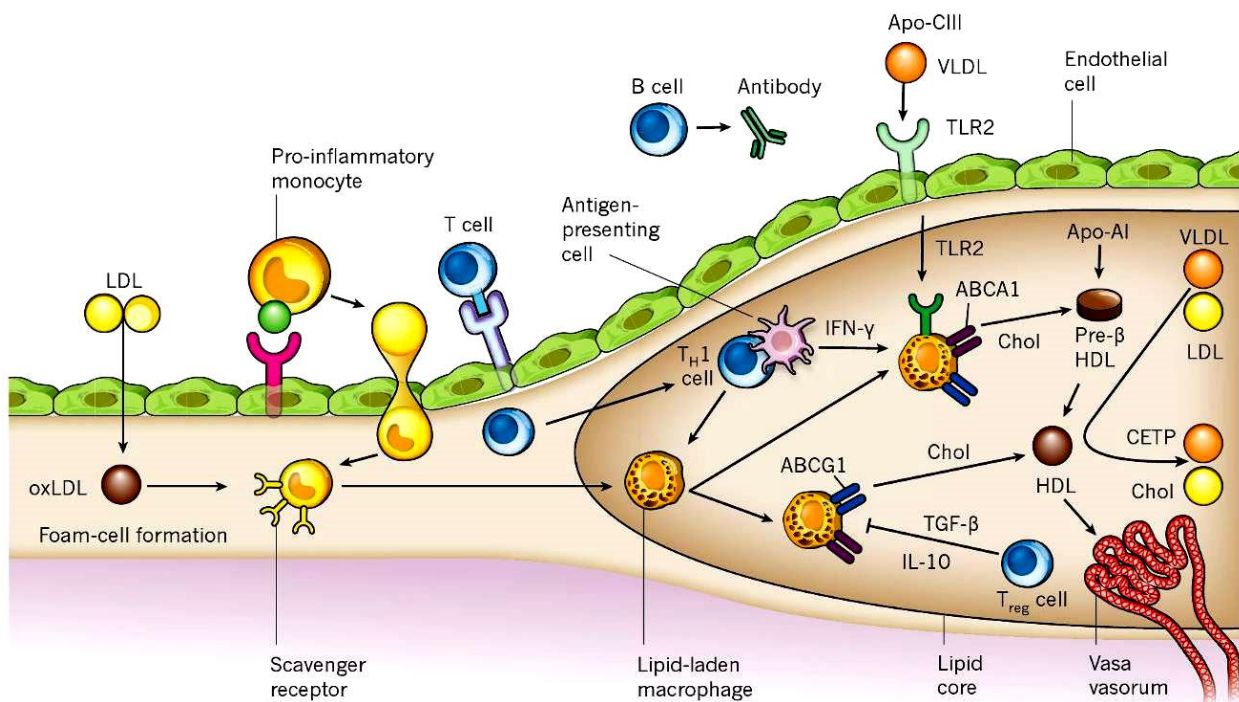


Figure 14: Role of inflammation and lipoproteins in atherogenesis. Activated endothelial cells express leukocyte adhesion molecules. Oxidized lipoproteins are also strong chemoattractants for monocytes. After entry into the intima, monocytes differentiate into macrophages and express scavenger receptors for the uptake of modified LDL particles. Inflammation is sustained by pro-inflammatory mediators, reactive oxygen species, and tissue factor. Macrophages ultimately evolve into foam cells. In addition to modified LDL, triglyceride rich lipoproteins (VLDL) can promote inflammation through Toll-like receptor 2. Cholesterol efflux from macrophages is orchestrated by ATP-binding cassette transporters (ABCG1, ABCA1) toward HDL. Cholesteryl ester transferase protein transfers cholesterol from VLDL/LDL to HDL and promote atherogenesis. Reprinted by permission from Macmillan Publishers Ltd: Nature (Libby P, Ridker PM, Hansson GK. Progress and challenges in translating the biology of atherosclerosis. *Nature*. 2011;473(7347):317–25.), copyright (2011).

Smooth muscle cells proliferation and migration to the intima and subintima plays an important role in the development of the atherosclerotic lesion (Figure 15). They are the main cells synthesizing extracellular matrix constituents such as collagen, elastic fibers and proteoglycans.(Wight 2005) It has been shown that the arterial wall reacts to experimental injury by proliferation of smooth muscle cells from the media and migration into the subintimal space where these cells are responsible for arterial healing and repair.(Cullen et al. 2005) Unlike most experimental animals, intima of human arteries also contains resident smooth muscle cells.(Libby et al. 2011; Stary et al. 1992) De-differentiation and phenotypic changes also occur from a contractile to a synthetic state with production of extracellular matrix components (proteoglycans, collagen).(George & Lyon 2010; Cullen et al. 2005; Coen & Bochaton-Piallot 2010) Smooth muscle cells also take up cholesterol and develop into foam cells and constitute a significant proportion of foam cells. In advanced fibroatheromatous lesions, the fibrous cap is composed of vascular smooth muscle cells. The formation of the fibrous cap and the phenotypic modulation of intimal smooth muscle cells are stimulated by growth factors and cytokines such as platelet-derived growth factor (PDGF), fibroblast growth factor (FGF-2) and transforming growth factor β (TGF- β).(George & Lyon 2010; Wamhoff et al. 2005; Libby et al. 2011) The origin of the smooth muscle cells implicated in atherosclerotic disease is still debated and a high degree of monoclonality has been observed.(Cullen et al. 2005; Coen & Bochaton-Piallot 2010) Bone marrow derived smooth muscle progenitor cells may also play a role in lesion development.(Wamhoff et al. 2005) Further proliferation of smooth muscle cells and formation of fibrous tissue lead to additional enlargement and restructuring of the lesions which becomes covered by a fibrous cap that overlies the lipid and necrotic core (Figure 15).(Ross 1999; Libby et al. 2011) Smooth muscle cells and their production of matrix constituents confer stability to atheromatous plaques in an attempt to encapsulate the necrotic core.(Schwartz et al. 2000)

As the atherosclerotic lesion evolves, macrophages are joined by other inflammatory cells. Lymphocytes participate in the immune modulation during the progression of atherosclerotic lesions. Dendritic cells and mast cells are also present. Immune activation is mainly stimulated by modified lipoproteins but also by microbial antigens and pro-inflammatory mediators.(Falk 2006) Natural killer T cells recognize lipid antigens and are especially present in early lesions.(Hansson 2005) CD4 and CD8 T cells are also present and express a variety of cytokines, cell surface molecules, and enzymes. In particular, Th1 effector cells activate macrophages and produce interferon γ and it has been shown that atherosclerotic lesions contain cytokines that promote a Th1 response rather than Th2 (Figure 14).(Hansson 2005) Mast cells play an additional role in inflammatory cells recruitment and foam cell formation by increasing the uptake of LDL by macrophages and smooth muscle cells.(Cullen et al. 2005) Histamine released from mast cells may also enhance arterial permeability and increase the intimal accumulation of LDL. Furthermore, heparin proteoglycans contained in mast cells granules bind LDL.(Lindstedt et al. 1992)

Platelets adhere to the activated endothelium and further contribute to endothelial activation by production of inflammatory and vasoactive molecules.(Hansson 2005; Harper et al. 2010) The release of adhesion molecules, growth factors, chemokines, cytokines, and coagulation factors enhances recruitment, adhesion, and diapedesis of monocytes into the intima.(Harper et al. 2010) Furthermore, platelets along with macrophages produce the potent smooth muscle cell chemoattractant PDGF.(Wamhoff et al. 2005)

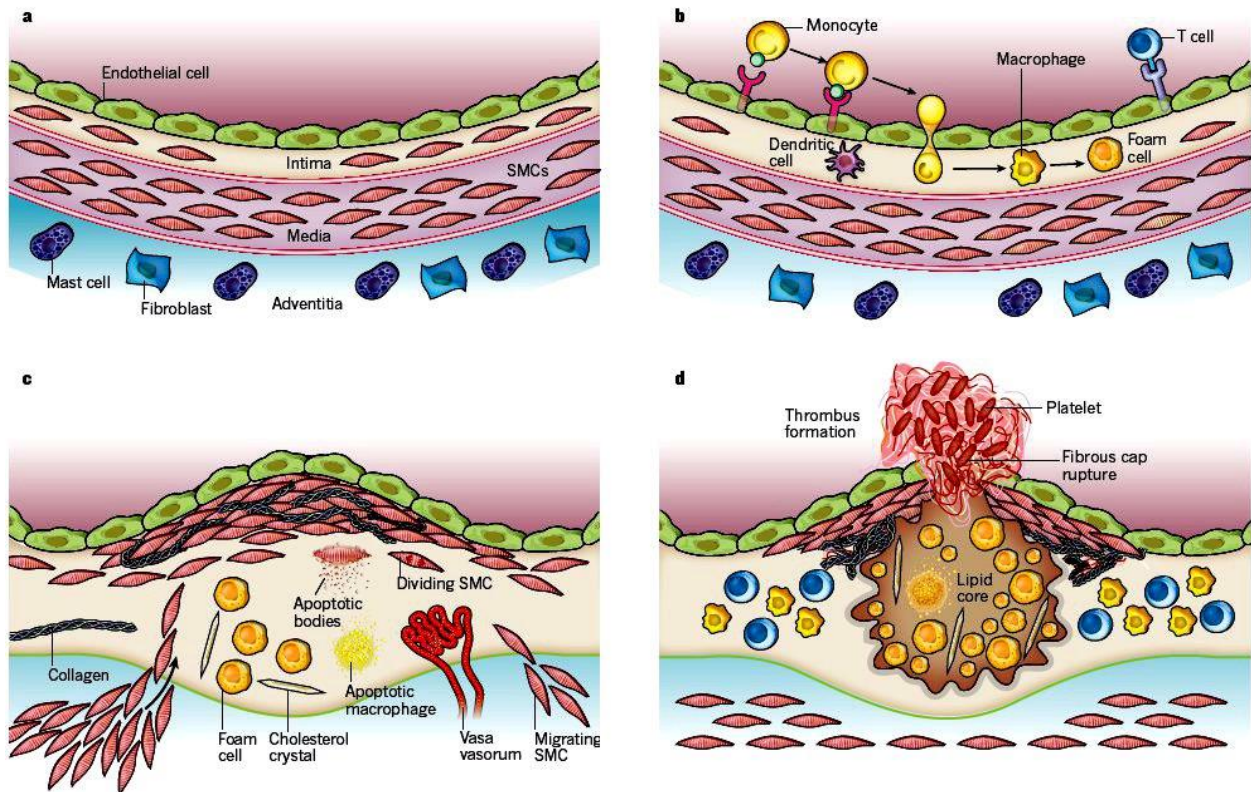


Figure 15: Stages in the development of atherosclerotic lesions. A, the normal human artery is composed of the intima presenting resident smooth muscle cells in contrast to animal models, the media composed of layers of elastin and smooth muscle cells, and the adventitia containing connective tissue and other cells. B, after endothelial activation, adherent monocytes migrate to the intima and differentiate into macrophages which ultimately develop into foam cells. C, smooth muscle cells migrate from the media into the intima and the resident intimal smooth muscle cells proliferate and together produce extracellular matrix component and form the fibrous cap overlying the lipid and necrotic atherosclerotic core. D, thrombosis is the ultimate complication of human atherosclerotic lesions where the fibrous cap rupture exposing lipid core constituents that are highly thrombogenic. Reprinted by permission from Macmillan Publishers Ltd: Nature (Libby P, Ridker PM, Hansson GK. Progress and challenges in translating the biology of atherosclerosis. *Nature*. 2011;473(7347):317–25.), copyright (2011).

The vascular extracellular matrix is composed of collagen and elastic fibers embedded in proteoglycans, hyaluronan, glycoproteins, and water and maintains vascular wall structure and provide a biomechanically active scaffold.(Wight 2005) The extracellular matrix is modified by macrophages and smooth muscle cells through secretion of both matrix constituents (collagen) and various matrix-degrading proteolytic enzymes such as matrix metalloproteinases (MMP) and tissue factor.(George & Lyon 2010; Cullen et al. 2005; Libby 2012) Type I collagen is mainly deposited within the fibrous cap.(Wight 2005) Fragmentation and disruption of elastic fibers are common in atherosclerotic lesions and are thought to be caused by released proteases.(Wight 2005) This causes a loss in arterial compliance and elasticity and exaggerated matrix deposition contributes to arterial luminal narrowing. Proteoglycans are protein polysaccharides formed of glycosaminoglycans (GAG) and a core glycoprotein and are predominant in the intima.(Wight et al. 1991; Wight 2005) The amount of proteoglycans increases at the beginning of the lesions and

decreases as lesions become more advanced and fibrotic. Changes in the proteoglycan composition of the extracellular matrix affect vascular permeability and promote lipoproteins binding.(Wight 2005; Williams & Tabas 1998) Calcification of atherosclerotic plaques is common and resembles active calcification such as happening in bones.(Falk & Shah 2005)

iii. Atherothrombosis and complications

Complications and clinical signs are usually due to either severe stenosis from the continuously growing atheromatous plaque or thrombosis and hemorrhage caused by plaque disruption that can decrease or interrupt blood flow or provoke emboli. Atherosclerotic lesions are silent and asymptomatic until such complications arise. Plaque disruption and smooth muscle cell death are promoted by proteolytic enzymes (e.g. MMP) and inflammatory mediators produced by macrophages, T cells, and mast cells.(Libby et al. 2011; Hansson 2005; Cullen et al. 2005) Variation in distribution of fibrillar collagen may create areas of the fibrous cap with differences in susceptibility to plaque rupture.(Wight 2005) Neovascularization is frequently present in advanced plaques and is associated with inflammatory cell infiltration, expression of adhesion molecules (e.g. VCAM-1 and ICAM-1), and hemorrhage.(Falk & Shah 2005) Plaque composition rather than plaque type plays a determinant role in rupture and complications. While the exact pathophysiology of plaque rupture remains to be determined, it is associated with specific features that include a large and soft lipid-rich atheromatous core, a thin and collagen-poor fibrous cap, lack of smooth muscle cells and accumulation of macrophages at rupture site, extracellular matrix deterioration, neovascularisation, and arterial inflammation.(Falk & Shah 2005; Virmani et al. 2000) Fracture of the fibrous cap or endothelial erosion cause procoagulant elements of the necrotic and lipid core (phospholipids, tissue factor, platelet-adhesive matrix molecules) to be exposed to coagulation proteins in the arterial lumen triggering coagulation, platelet adhesion, and thrombosis (Figure 15).(Libby et al. 2011; Hansson 2005; Harper et al. 2010; Virmani et al. 2000) Platelet aggregation may also be stimulated by exposed collagen fibers, oxidized lipoproteins, and other plaque constituents as well as local flow disturbances and systemic thrombotic propensity.(Falk & Shah 2005; Wight 2005) The thrombus composed of platelets and fibrin evolves and may lead to flow obstruction and embolization.

B. Atherosclerotic lesions

Different types of atherosclerotic lesions have been described that reflect the pathophysiology and progression of atherosclerosis. The old classification relies mainly on morphological gross description and includes:(Stary 2003c; de Brue et al. 1958)

- Fatty dots/streaks: superficial yellow intimal lesions that stain positively with lipid stains
- Fibrous plaque: firm circumscribed and elevated intimal thickening
- Atheroma: atherosclerotic plaque with fatty softening
- Complicated lesions: lesions with additional changes or alterations such as hemorrhage, thrombosis, ulceration, and calcification.

This gross classification has many limitations and precise lesion types cannot be determined especially as it relates to the pathogenesis and pathways of development. More precise and detailed histopathologic classification of atherosclerotic lesions based on large reviews of cases in conjunction with experimental studies and clinical considerations have been developed since. The reference classification is the one endorsed by the American Heart Association (AHA) which includes 8 lesion types (Figures 16-17).(Stary et al. 1994; Stary et al. 1995; Stary 2005; Stary et al. 1992; Stary 2000)

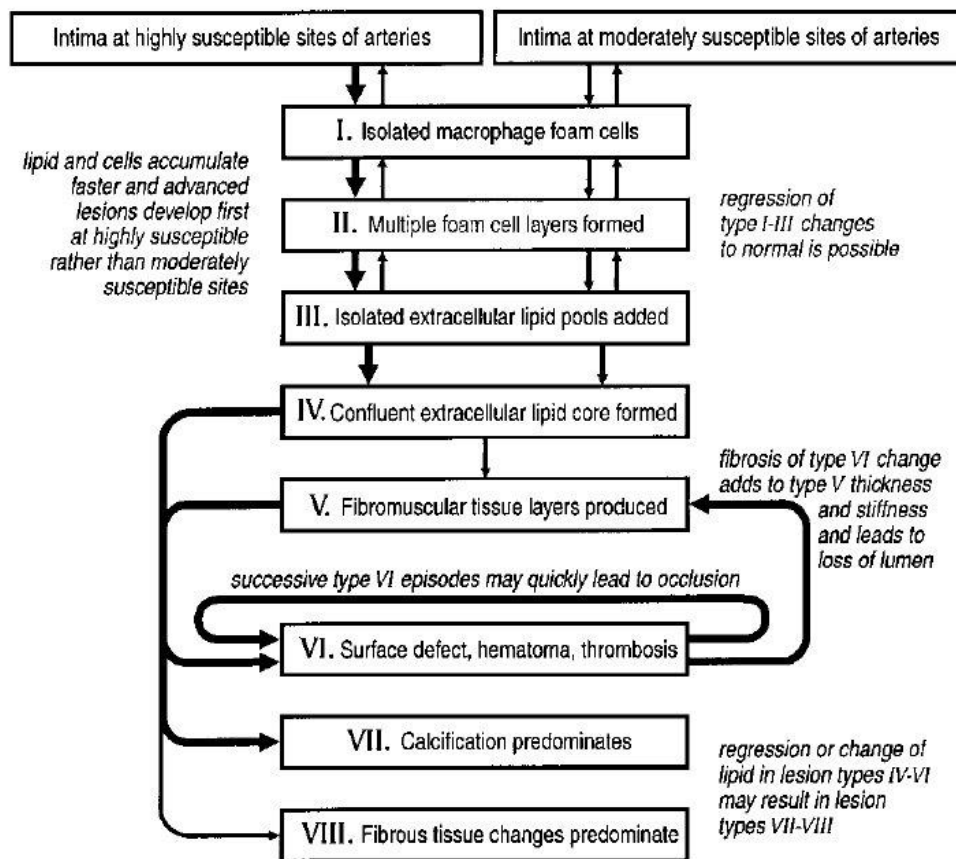


Figure 16: American Heart Association (AHA) classification of human atherosclerotic lesion types with their pathways of progression and regression. Thick and thin arrows differentiate between the relative ease with which lesions develop in specific location, or they indicate the relative frequency and importance of a specific pathway section. Reprinted with permission from Wolters Kluwer Health: (Stary HC, Natural history and histological classification of atherosclerotic lesions: an update. *Arterioscler Thromb Vasc Biol.* 2000; 20:1177-1178).

Minimal atherosclerosis comprises type I and II lesions mainly formed of macrophages and foam cells which never produce clinical manifestations or obstruct blood flow. Type III lesions are intermediate between lesions with minimal changes and those with advanced atherosclerotic changes and are characterized by extracellular lipid accumulation. Advanced lesions also known as clinically important lesions include changes that produce clinical signs and silent ones that have yet to obstruct blood flow, rupture, or lead to thromboembolism. These lesions include type IV lesions composed of a lipid and necrotic core, type V lesions including a thick fibrous cap over the lipid core, type VI lesions with added complications such as endothelial defects, hematoma, and thrombus, type VII lesions which are mainly calcific with reduced presence of fat, and type VIII lesions that are fibrotic without a lipid core. Type VI lesions are most commonly associated with disease and fatalities. Type VII and VIII are regressive lesions with minimal amount of fat and are sometimes referred to as type Vb and Vc lesions, respectively (Figures 16-17).

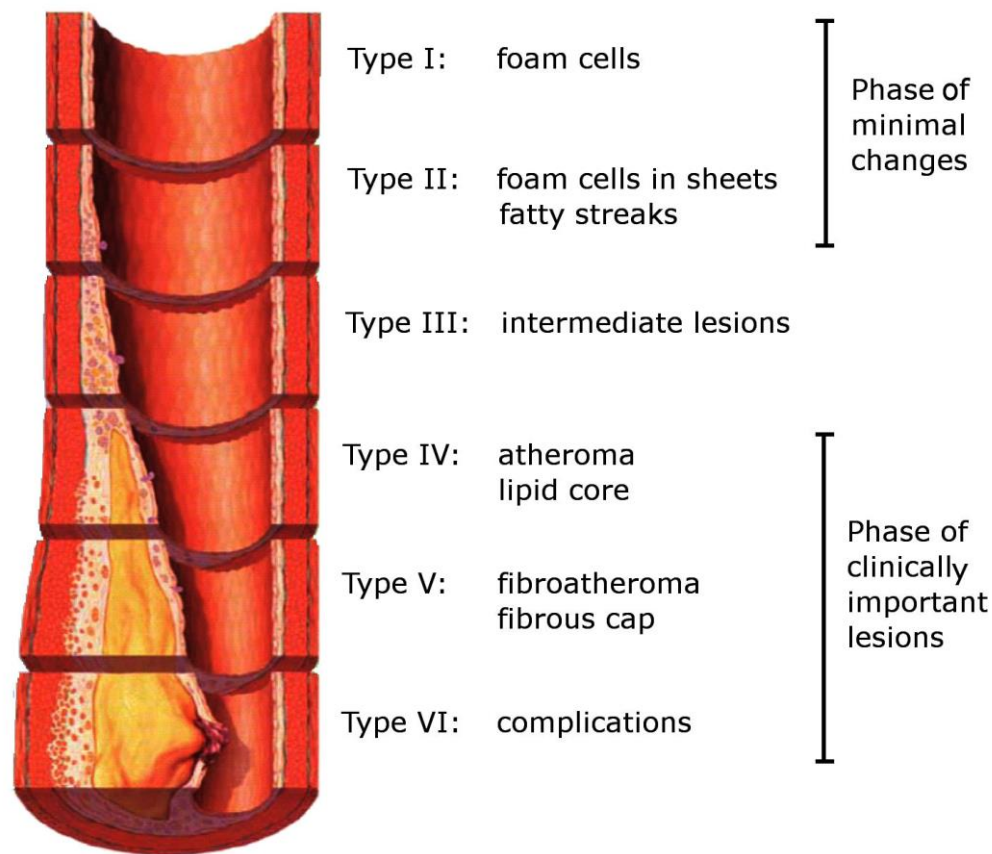


Figure 17: Diagrammatic representation of the main human atherosclerotic lesion types as classified by the AHA. This illustrates the usual sequence in the development of atherosclerosis. Modified and reprinted with permission from Wolters Kluwer Health: (Koenig W, Khuseyima N. Biomarkers of atherosclerotic plaque instability and rupture. *Arterioscler Thromb Vasc Biol.* 2007, 27: 15-26).

This classification system has been revised and modified by some authors. A modified classification scheme has been proposed in which atherosclerotic lesion types have names referring to clinically important morphological attributes without the use of roman numerals that may imply a linear pattern of lesion progression (Figure 18). (Virmani et al. 2000) In this more descriptive classification, initial xanthoma replaces fatty streak or initial lesion and describes focal accumulation of fat-laden macrophages. Intimal thickening is another mechanism of the initial lesion, which may be an adaptation to local hemodynamic constraints and these intimal cell masses can progress to erosion and give rise to clinical signs. Fibrous cap atheroma accounts for type IV and V lesions of the AHA classification. Since the thickness of the fibrous cap is an important determinant of rupture and symptoms, thin and thick fibrous cap atheromas are distinguished. Complicated lesions are further classified into 3 processes: rupture, erosion, and calcified nodules. Thrombus can be seen either communicating with the lipid core through a ruptured fibrous cap or overlying an eroded plaque. Finally, complex lesions are also described.

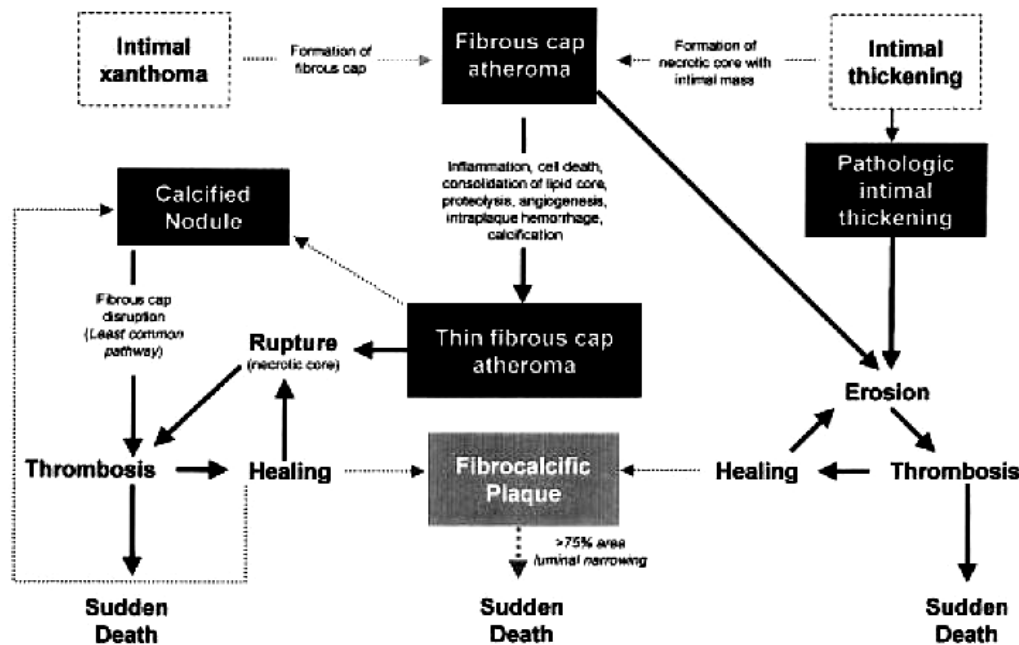


Figure 18: Modified AHA classification based on lesion morphology and clinical outcome. Boxed areas represent the 7 categories of lesions. This also shows processes of lesion progression. Dotted lines represent the least established processes while thick lines represent events with high strength of evidence. Reprinted with permission from Wolters Kluwer Health: (Virmani R, Kolodgie FD, Burke AP et al. Lessons from sudden coronary death: a comprehensive morphological classification scheme for atherosclerotic lesions. *Arterioscler Thromb Vasc Biol.* 2000, 20: 1262-1275).

C. Risk factors for atherosclerotic diseases

i. Overview

Risk factors are clearly defined by occurrence or characteristics that have been associated with the increased rate of a subsequently occurring disease; causality may or may not be implied.(Albert et al. 2012) Also risk factors usually refer to clinical diseases. As such, risk factors have been characterized in humans for clinical atherosclerotic diseases such as coronary heart disease, cerebrovascular accidents, and peripheral arterial disease but not for atherosclerotic lesions themselves, which are present in almost everyone to some degree. Atherosclerotic lesions and their characteristics are actually risk factors themselves for clinical disease. In human epidemiology, risk factors are typically studied in prospective and clinical studies. With atherosclerosis being the major cause of human death in the world, countless large prospective studies, such as the pioneering Framingham study, have been conducted in an attempt to identify risk factors for atherosclerotic diseases in various populations.(Abbott et al. 1983; Karim et al. 2008; D'Agostino et al. 2008; von Eckardstein 2005; Jousilahti et al. 1999) Risk factors may be definitely modifiable (e.g. lifestyle, diet), potentially modifiable (e.g. hematologic) or fixed (e.g. age, gender).(Wilson 2005) Also, some risk factors (e.g. obesity) may not emerge in studies as statistically independent because they partially affect the pathogenesis of atherosclerosis indirectly via other measurable risk factors. They are classified as underlying risk factors but are still targets for intervention.(von Eckardstein 2005)

Identifying and quantifying individual risk factors is an important aid in diagnosis and prevention and specific guidelines have been developed by scientific groups such as the AHA, World Health Organization (WHO), or the European Atherosclerosis Society (EAS).(Pearson 2002; Hirsch et al. 2006; Kavey et al. 2003; Reiner et al. 2011; WHO 2007) Global risk assessment scores have been developed in which classical and independent risk factors are combined in algorithms to estimate individual risks of developing atherosclerotic diseases.(von Eckardstein 2005; Reiner et al. 2011; Kavey et al. 2003; Grundy et al. 1999; WHO 2007)

Apart from total cholesterol values, the leading risk factors globally according to the WHO in the ascending order are increased blood pressure, tobacco use, increased blood glucose (diabetes mellitus), physical inactivity, and obesity.(WHO 2011) Furthermore, according to a large number of epidemiological studies, 80-90% of patients having coronary heart disease events have at least one of the four classical risk factors including hypercholesterolemia, hypertension, diabetes mellitus, or smoking.(von Eckardstein 2005) Risk factors can be classified into biochemical, lifestyle, personal, and physiological (Table 18).(McGill & McMahan 2005; George & Lyon 2010; Wilson 2005; von Eckardstein 2005; Pearson 2002; Smith, Blair, et al. 2001; WHO 2007)

Table 18: risk factors for coronary heart disease associated with atherosclerosis (* other than dyslipidemia).

Biochemical*	Lifestyle	Physiological	Personal
Hyperglycemia (diabetes)	Dietary saturated fat	Elevated blood pressure	Age
Thrombogenic factors	Dietary cholesterol	Metabolic syndrome	Sex (male)
Homocysteinemia	Dietary calories	Obesity	Family history
Inflammatory markers (C-reactive protein, fibrinogen)	Low intake of fruits and vegetables		Genetic factors
	Alcohol		Personal history
	Tobacco smoking		
	Physical inactivity		
	Stress		

ii. Lipoproteins

1. Metabolism

Lipoproteins are a complex water-soluble transport system of lipids, cholesterol, triglycerides, and phospholipids in the circulation. This transport system cycles lipid to muscle and adipose tissue and cholesterol throughout the body that is used in cell membranes, bile acids, and steroid hormone synthesis. Cholesterol synthesis is controlled by transcriptional regulation of 3-hydroxy-3-methylglutaryl coenzyme A (HMG-CoA) reductase and HMG-CoA synthetase which are the rate-limiting enzymes in cholesterol biosynthesis.(Kane 2005) Retrieval of cholesterol from target sources to the liver occurs through a reverse cholesterol transport pathway. Lipoproteins are spherical or discoidal particles composed of a core of hydrophobic cholesteryl esters and triglycerides surrounded by a coat of phospholipids, unesterified cholesterol and proteins.(Zannis et al. 2005; Kane 2005) The proteins of the surface are known as the apolipoproteins and have functions in structural integrity, enzyme activation, and receptor binding.(Zannis et al. 2005) Apolipoproteins are grouped into several families depending on their structure and size. A family of small apolipoproteins can move among the lipoprotein types and

comprise apolipoproteins A-I, A-II, A-IV, A-V, C-I, C-II, C-III, C-IC, and E. The B apolipoproteins are larger proteins that are inexchangeable between lipoprotein types and include apoB-100 and apoB-48.(Kane 2005) Plasma lipoproteins are traditionally separated into subclasses based on their density: chylomicrons, very low-density lipoproteins (VLDL), intermediate-density lipoproteins (IDL), low-density lipoproteins (LDL), and high-density lipoproteins (HDL). Lipoprotein (a) is part of the LDL group.(Zannis et al. 2005) Chylomicrons, LDL, IDL, VLDL contain apoB (also called apoB-containing lipoproteins) and HDL contain apoA-I as the main apolipoproteins.(Kwiterovitch 2000; Hoofnagle & Heinecke 2009) Lipoprotein metabolism includes three different pathways: the chylomicron pathway, the VLDL/IDL/LDL pathway, and the HDL pathway.(Zannis et al. 2005) Different protein receptors and lipid transfer enzymes such as cholesteryl ester transfer protein (CETP), phospholipid transfer protein (PLTP), and lecithin cholesterol acyltransferase (LCAT) have functions in lipid exchange through these lipoproteins.(Kane 2005; Zannis et al. 2005)

The intestinal cells secrete chylomicrons in the lymph where dietary lipids assemble with apoB-48 that requires the enzyme microsomal triglyceride transfer protein (MTP).(Kindel et al. 2010) In plasma, the triglycerides of the chylomicrons are hydrolyzed into free fatty acids and glycerol by lipoprotein lipase at the surface of endothelial cells in a process requiring the cofactor apoC-II which, as a result, produces chylomicron remnants rich in cholesteryl esters and contain apoE. Free fatty acids, bound transiently to albumin, and glycerol are taken up by tissues. Chylomicron remnants are removed from the blood by the liver through LDL-receptor related protein and LDL receptors.(Zannis et al. 2005; Kwiterovitch 2000; Kane 2005) VLDL are secreted by the liver with apoB-100 on their surface and function to transport endogenous triglycerides along with LDL. VLDL also contains apoE. As for chylomicrons, the triglycerides of the VLDL are broken down in plasma by lipoprotein lipase with its cofactor apoC-II leading to the formation of smaller particles, the IDL rich in cholesteryl esters and other VLDL remnants such as β -VLDL. IDL may be further converted into LDL by the action of hepatic lipase. Some VLDL remnants and IDL are catabolized by the liver through the interaction between the LDL receptor and apoE as a ligand or VLDL receptor. LDL is also taken up by the LDL receptor in the liver with apoB as a ligand.(Zannis et al. 2005; Kwiterovitch 2000; Kane 2005) Small dense LDL are a subpopulation of LDL that has a lower affinity for the LDL receptor and remains longer in circulation. This subpopulation increases in the presence of hypertriglyceridemia. Regulatory mechanisms in cholesterol homeostasis are regulated in part by hydrolysis of cholesteryl esters contained in LDL subsequent to their binding with LDL receptors. This leads to a downregulation of HMG-CoA reductase (cholesterol synthesis), LDL receptors expression (entrance of cholesterol into cells), and upregulation of acyl-CoA cholesterol acyltransferase (ACAT2) which promotes intracellular cholesteryl ester storage.(Zannis et al. 2005) Lipoprotein (a) is another apoB-containing lipoprotein and represents a distinct class of lipoprotein similar to LDL but varying in density.(Zannis et al. 2005) Lipoprotein (a) contains apo(a), is secreted by the liver, and participates in the endogenous cholesterol transport pathway. Apolipoprotein (a), linked by a disulphite bond to apolipoprotein B-100, has a structure similar to plasminogen.(McLean et al. 1987)

HDL are mainly synthesized in the liver and contained apoA-I as the main apolipoprotein and small amounts of other apolipoproteins such as apoE and apoC proteins. HDL form a heterogeneous group with different density subfractions, HDL₁, HDL₂, and HDL₃. The latter is the smallest particle and contains the least amount of lipid.(Rader 2005) HDL have functions in the reverse cholesterol transport pathway where they acquire phospholipid and cholesterol

through the action of ATP-binding cassette A1 (ABCA1) lipid transporters at the efflux cells.(Rader 2005) LCAT participates also in HDL modification by esterification of free cholesterol.(Zannis et al. 2005) Cholesteryl esters can be transferred to apoB-containing lipoproteins, process notably mediated by CETP. Cholesterol can then be delivered to hepatocytes by receptor-mediated endocytosis (LDL receptor).(Kane 2005) Transfer of cholesterol from tissues to liver can also be mediated directly by the HDL through the activity of SR-B1.(Rader 2005)

2. Lipoproteins and atherosclerosis

LDL, VLDL and its remnant IDL promote atherogenesis whereas HDL has antiatherosclerosis properties. When the concentration of LDL and other apoB-containing lipoproteins increase, they may penetrate the subendothelium. Modified LDL (by oxidation or glycation (diabetes)) have an increased tendency to aggregate, adhere to arterial proteoglycans, and get incorporated into immune complexes which may induce endothelial injury and promotes endothelial dysfunction.(Ross 1999; Hessler et al. 1983) Oxidized lipoproteins may be the single most important injurious agent leading to endothelial dysfunction and the discovery of their cytotoxic effects has prompted a revision of the response to injury hypothesis.(Penn & Chisolm 2005) They upregulate the expression of adhesion molecules and the secretion of chemokines by the endothelial cells.(Sitia et al. 2010) Increased oxidative stress and products of lipid peroxidation stimulate the modification of LDL. Once trapped in the intima, LDL continue to undergo oxidation and are taken up by macrophages via scavenger receptors such as SR-B1, SR-A, or CD36 as a clearing mechanism. Internalized modified lipoproteins undergo modification and esterification, and ultimately, macrophages become foam cells. Oxidized LDL also act as auto-antigen stimulating the adaptive immune response, are strong chemotactic signals for macrophages, have strong pro-inflammatory properties, can stimulate proliferation of smooth muscle cells, and have procoagulant activities.(Ross 1999; Sitia et al. 2010; Penn & Chisolm 2005) Interaction between oxidized LDL and C-reactive protein (CRP) also promotes autoimmunity.(Sitia et al. 2010) Small, dense LDL have a lower affinity for the LDL receptor and have greater susceptibility to oxidation due to their longer half-life. (Zannis et al. 2005) Furthermore, oxidized lipoproteins induce macrophages and smooth muscle cells apoptosis and necrosis. Lipoprotein (a) also contributes to atherogenesis and thrombosis by interfering with LDL metabolism and fibrinolysis and chemoattraction of monocytes.(Zannis et al. 2005) A vicious circle of inflammation and further modification of these lipids perpetuates atherogenesis. In addition, defects at any stage along the cholesterol transport pathway may increase the amount of LDL/VLDL in the blood and predispose to the development of atherosclerosis. The most common examples in humans include low activity of lipoprotein lipase, an overproduction of VLDL (precursor of LDL) or chylomicrons, lipoprotein structure abnormalities, or defects in the LDL receptor.(Kwiterovitch 2000)

Conversely, HDL protect against atherosclerosis through the reverse cholesterol transport pathway by promoting cholesterol efflux from macrophages mediated by cholesterol transporters such as ABCA1 and ABCG1.(Rader 2005; Cuchel et al. 2010; Van Eck et al. 2005) HDL allows cholesterol to return to the liver through cholesterol transfer to LDL via CETP which can then be excreted into the bile. Enhancement of this pathway through higher HDL concentration or overexpression of apoA-I may decrease the occurrence of atherosclerosis and blood lipid levels. The relation between the expression of LCAT and CETP and atherosclerosis in animal models and humans is uncertain.(Rader 2005; Zannis et al. 2005) Additionally, HDL have antioxidant

properties and prevents LDL oxidation, have anti-inflammatory properties by reduction in cytokines and adhesion molecules expression, enhance NO production by endothelial cells, have the ability to bind to SR-B1, and have anticoagulant properties.(Rader 2005; Mineo et al. 2003)

3. *Dyslipidemia and risk factors*

Dyslipidemia are alterations in normal lipid metabolism and blood values that can be initiated by lifestyle, dietary, metabolic, and other underlying risk factors but also by genetic diseases such as familial hypercholesterolemia (deficient LDL receptor) and type III hyperlipoproteinemia (abnormal apoE).(Bersot & Mahley 2005) They are compelling evidence linking specific types of dyslipidemia with atherosclerotic diseases. The magnitude and strength of these associations have been reviewed in international guidelines such as those published by the AHA, the WHO, the EAS, the international atherosclerosis society (IAS), and the American Association of Clinical Endocrinologists (AACE) as well as the criteria for intervention defined (Table 19).(Pearson 2002; Reiner et al. 2011; Kavey et al. 2003; Talayero & Sacks 2011; Miller et al. 2011; WHO 2007; Smith, Blair, et al. 2001; Wood et al. 1998; Jellinger et al. 2012) Raised total cholesterol is the most important lipid abnormality and one third of coronary heart disease worldwide can be attributed to high blood total cholesterol.(WHO 2011)

Table 19: Dyslipidemic risk factors associated with human atherosclerotic diseases (* major risk factors).

Dyslipidemic risk factors associated with atherosclerotic diseases
Raised total cholesterol*
Raised LDL cholesterol*
Raised non-HDL cholesterol* (LDL+VLDL)
Low HDL cholesterol*
Raised triglycerides
Raised lipoprotein (a)
Raised apolipoprotein B
Increased ratio apo B/apoA1
Increased ratio non-HDL/HDL
Raised small, dense LDL
Increased LDL particle number

D. Diagnostic techniques

Diagnostic techniques for atherosclerosis are heavily based on imaging techniques to identify and characterize atheromatous plaques and affected arteries. Functional tests aim to detect abnormalities in blood pressure, cardiac function, and tolerance to exercise that are linked to atherosclerotic diseases. They are also, in most cases, prognostic indicators. Furthermore hematologic, inflammatory markers, and imaging diagnostic tests are used to detect preclinical atherosclerosis, evaluate the risk to develop subsequent atherosclerotic problems, and for designing prevention plans.

The ankle-brachial index (ABI) is the ratio between the indirect systolic blood pressure measured at the ankle and at the arm. The ABI is used for detection of peripheral arterial disease and is a simple, reproducible, and accurate method of determining, to some degree, the presence

of arterial obstruction. The normal ABI is 1 and is considered abnormal below 0.9.(Feinstein 2008; Hirsch et al. 2006; Wennberg & Rooke 2005) Pre-exercise and post-exercise ABI can also be compared. Segmental blood pressure measurements are indicated in the diagnosis and localization of peripheral arterial disease. Other non-invasive methods used to assess peripheral perfusion and pulse include pulse volume recording, continuous-wave Doppler ultrasound, duplex ultrasound, standardized treadmill exercise.(Hirsch et al. 2006)

Diagnostic imaging of arterial luminal stenosis and atheromatous plaques is the cornerstone of atherosclerosis diagnosis and management. Vascular imaging is evolving rapidly and the principal techniques are presented in Table 20. The value, invasiveness, and indications of the various diagnostic imaging technique vary with some aimed to detect luminal narrowing, others to quantify plaque calcification (CT calcium scoring), and more advanced techniques being able to provide information on plaque composition and characteristics.(Choudhury et al. 2005)

Table 20: Diagnostic imaging modalities used in human atherosclerotic diseases(Feinstein 2008; Choudhury et al. 2005; Budoff et al. 2008; Pakkal et al. 2011)

Technique	Comments
Arteriography	Gold standard and sensitive for stenosis Needs arterial catheterization No information on plaque composition
Stress echocardiography	Used with dobutamine, with coronary heart disease, stress results in myocardial ischemia manifested in regional wall motion abnormality.
Transthoracic Doppler ultrasound	Measurement of coronary flow velocity, ratio between hyperemic state and baseline. This ratio is correlated to the degree of stenosis.
Carotid ultrasound	Correlated to coronary atherosclerosis
Transesophageal ultrasound	Measurement of carotid and aortic wall thickness. Echogenicity of the plaque reflects its characteristics. Operator dependent and low reproducibility. Carotid and aortic atherosclerosis are markers for coronary atherothrombosis.
Multi-detector CT	Cardiac CT with ECG gating, a low heart rate is needed and patients need to breath-hold. Some patients are pretreated with beta-blockers. With contrast: coronary angiography, assess the severity of stenosis.
Electron-beam CT (ultrafast CT)	The X-ray tube is large and stationary and the X-ray source point is swept electronically along the anode in the tube, which is faster than mechanically. Has been developed specifically for heart because it moves and acquires information during the cardiac cycle. Calcification occurs predominantly due to atherosclerosis and in certain arteries is almost exclusively due to this disease. EBCT determines a calcium score. Does not require contrast.
Intravascular ultrasound	Invasive technique using a catheter with a miniaturized ultrasound transducer. The arterial wall and its different layers are visualized. Dynamic imaging histology has a high resolution especially in combination with digital image analysis. Can detect fibrous cap, necrotic core, and mineralization.

(Table 20 continued)

Technique	Comments
Intravascular ultrasound elastography	Evaluation of arterial wall biomechanics, deformation with and without application of stress. Plaque composition can be inferred from biomechanical patterns (lipid rich, fibrous, mineralized).
Optical coherence tomography	Uses back reflected infrared light. Samples with greater heterogeneity of optical index of refraction exhibit stronger scattering and stronger OCT signal. It is an intravascular technique.
Near infrared spectroscopy	Invasive method based on the absorbance of light by organic molecules. Can give insight into plaque chemical composition.
MRI	ECG gated. Plaques can be identified and measured. Thrombus can also be imaged with specific sequences. MRI angiography. Stress MRI.
Molecular imaging	Imaging of plaques using radiolabeled molecules.
PET/SPECT-scan	Imaging agents can be detected at very low concentration. 18FDG, a glucose analog accumulates in plaques in symptomatic patients.

E. Medical management and treatment

i. Reduction of risk factors and prevention

General guidelines for risk reduction have been proposed by the AHA, WHO, and EAS. Guidelines are mainly based on lifestyle and dietary modifications combined with cardiovascular risk reduction using therapeutic drugs for dyslipidemia and hypertension.(Hirsch et al. 2006; Smith, Blair, et al. 2001; Pearson 2002; Kavey et al. 2003; Reiner et al. 2011; WHO 2007; Weintraub et al. 2011; Smith et al. 2011) With the premise that atherosclerosis begins early in life, the main targets for general and global prevention are the major risk factors and prevention campaigns are primarily focused on smoking cessation, healthy dietary habits, reduction of blood pressure and obesity, increased physical activity, and reduced sedentary lifestyle. For instance, at least 30 minutes of moderate-intensity physical activity per day is recommended and dietary measures include reduction in calories, overall fat, saturated fat, trans-fat, cholesterol, sodium, alcohol and increased consumption of fruits, vegetables, whole grains, potassium, omega-3 fatty acids, and fish. Target values for total, LDL, and HDL cholesterol as well as for blood pressure have been determined. Aggressive risk reduction is recommended for secondary prevention after a first cardiovascular event.

ii. Medical treatment

1. Statins

The statins are a homogenous group of lipid-lowering drugs. They inhibit the biosynthesis of cholesterol by targeting the hepatic 3-hydroxy-3-methylglutaryl coenzyme A (HMG-CoA) reductase that participates in a critical step in the mevalonate pathway.(Paoletti et al. 2005) They are, in fact, HMG-CoA structural analog. Several statins are commercially available: lovastatin, simvastatin, pravastatin, fluvastatin, atorvastatin, and rosuvastatin. Among these drugs, only atorvastatin and rosuvastatin have a long half-life in humans of about 15-30h and are the most used statins at the present time.(Paoletti et al. 2005) A comprehensive systematic review on the use of statins in primary prevention concluded that statins reduced mortality and cardiovascular events due to atherosclerosis and were associated with significant reduction in total and LDL cholesterol.(Taylor et al. 2012) Multiple large scale studies and meta-analyses have also showed the beneficial effect of statins in both primary and secondary prevention.(Reiner et al. 2011) The

lipid effects of statins include lowering LDL by 18-55%, triglycerides by 7-30%, and increasing HDL by 5-15%.(Pasternak et al. 2002) In addition, statins have other non-lipid beneficial effects (Table 21). Side effects are uncommon and mainly muscular and include rhabdomyolysis and myalgia.(Taylor et al. 2012; Pasternak et al. 2002; Paoletti et al. 2005) Some statins have pharmacologic interactions, mainly with drugs metabolized by the cytochrome P450 pathway such as antifungals.(Pasternak et al. 2002; Paoletti et al. 2005)

Table 21: Non lipid-effect of statins.(De Loecker & Preiser 2012; Paoletti et al. 2005; Pahan 2006)

Non lipid-effects of statins	
Endothelial function	
	Attenuate endothelial monocyte adhesion
	Up-regulation of endothelial NO synthase
	Decrease in oxidative stress
Vascular inflammation	
	Reduction in CRP
	Reduction in local inflammatory markers (chemokines, adhesion molecules, cytokines)
Immunomodulatory	
	Decrease MHC-II expression and activity
	Decrease TLR-4 expression
	Decrease T-cell activation
	Decrease monocyte/macrophage proliferation
Antioxidant	
	Decrease NADPH oxidase activity
	Increase heme oxygenase activity
Antithrombotic	
	Decrease platelet activity
	Decrease plasminogen activator
	Increase tissue plasminogen activator
	Increase thrombomodulin activity
Plaque stabilization	
	Inhibition of macrophage foam cell formation
	Prevention of smooth muscle cell proliferation
	Decrease in plaque thrombogenicity

2. *Fibrates*

Fibrates such as gemfibrozil or fenofibrate are hypolipidemic drugs used in the management of hypertriglyceridemia and dyslipidemia, especially diabetic dyslipidemia. Fibrates are agonist of the peroxisome proliferator-activated receptor alpha (PPAR α) which stimulates β -oxidation of fatty acids. PPAR α is a transcription factor that modulates expression of specific target genes and results in increased β -oxidation in the liver, decreased hepatic triglyceride secretion, increased lipoprotein lipase activity, increased HDL, and increased clearance of remnant particles.(Robillard et al. 2005; Chapman 2006; Pahan 2006) Elevated triglycerides level can decrease by up to 50% and HDL can increase by up to 5-15%.(Chapman 2006) Fibrates also

have non-lipid positive effects on atherogenesis prevention such as an influence on endothelial dysfunction and monocytes adhesion and other steps of atherosclerotic lesion development such as foam cell formation and fibrous plaque development.(Robillard et al. 2005) A number of clinical trials have demonstrated a significant reduction of cardiovascular risks and beneficial effects on atherosclerotic lesion progression.(Robillard et al. 2005; Jun et al. 2010) Fibrates can also be used in combination with statins. Side effects appear to be uncommon as for statin drugs and include myopathy and stomach upset especially when gemfibrozil is combined with a statin. Long-term use of fibrates has been associated with peroxisome proliferation and hepatic tumors in laboratory rodents.(Pahan 2006)

3. *Others*

Bile acid sequestrants (resins) such as colestipol are not systemically absorbed and prevent the reabsorption of bile acids during the enterohepatic circulation of bile acids. Therefore, the liver synthesizes bile acids from cholesterol stores which subsequently increases LDL receptor activity and decreases LDL cholesterol blood levels. Reduction in LDL cholesterol is typically of a magnitude of 15-30% with no effect on other lipid values.(Reiner et al. 2011; Gotto & Farmer 2005)

Ezetimibe is a relatively new cholesterol absorption inhibitor which acts at the level of the brush border of the intestine. There is a subsequent decrease in the delivery of cholesterol to the liver by the intestine. Ezetimibe is frequently used in combination with statins and further decreases LDL cholesterol by 15-20%.(Reiner et al. 2011; Gotto & Farmer 2005)

Nicotinic acid has broad dyslipidemic indications and promotes HDL increase, LDL, VLDL, and triglycerides decrease by a reduction in the flux of fatty acids from adipose tissue to the liver. It also shows important decrease in lipoprotein(a).(Reiner et al. 2011; Gotto & Farmer 2005)

Patients with severe dyslipidemia may require low-density lipoprotein apheresis during which LDL and lipoprotein(a) are removed from the blood during weekly extracorporeal circulation procedures.(Reiner et al. 2011)

Antihypertensive drugs such as ACE inhibitors and angiotensin II receptor antagonists (sartans via AT₁ receptor) are beneficial in atherosclerosis when hypertension is present.(Dendorfer et al. 2005) Angiotensin II aggravates hypertension, metabolic syndrome, dyslipidemia, oxidative stress, inflammation, and endothelial dysfunction and has procoagulatory effects and promotes plaques destabilization. Antihypertensive drugs improve prognosis and reduce overall mortality after coronary disease events. Their actions are due to antihypertensive effects but they also improve vascular function, decreased myocardial remodeling, and improved vascular neuro-hormonal regulation.(Dendorfer et al. 2005)

Beta blockers have been shown to reduce the progression of atherosclerotic lesions, recurrence of myocardial infarction, and systemic blood pressure.(Sipahi et al. 2007; Bondjers 1994)

Platelets are involved in all stages of the pathogenesis of atherosclerosis and thrombosis and thromboembolism are ultimately the factors leading to acute clinical signs. In addition, a prothrombotic tendency is present in patients suffering from atherosclerotic diseases. Antiplatelet therapy commonly involves the use of aspirin, cilostazol, and clopidogrel but a large number of other compounds are also effective.(Ahrens et al. 2005) Aspirin, principally used in the treatment of atherothrombosis and strokes, inhibits cyclooxygenases COX-1 (expressed by platelets) and COX-2 thereby inhibiting the production of thromboxane TXA₂. Cilostazol inhibits platelet activation and increase vasodilation and is mainly used in the treatment of peripheral arterial disease.(Ahrens et al. 2005; Hirsch et al. 2006) Clopidogrel is now the drug of choice in

antiplatelet therapy because of excellent tolerability and low rate of side-effects. Clopidogrel is a P2Y₁₂ ADP receptor antagonist which is important in platelet aggregation and cross-linking of platelets by fibrin.(Ahrens et al. 2005)

F. Mammal models of atherosclerosis

i. Generalities

Animals have been used to experimentally reproduce atherosclerosis for more than a century.(Ignatowski 1908; Starokadomsky & Ssobolew 1909) Animal models provide the necessary controlled conditions to study the pathogenesis, management, treatment, risk factors while avoiding other confounding factors and approximating the naturally occurring disease of humans. Even with the considerable growth of *in vitro* research and cell culture experiments in atherosclerosis, animal models will still be useful in order to account for the complexity of real disease processes and their pathophysiology. There is a wide diversity of animal models that have been developed over the years with advantages and disadvantages inherent to each one. It is also important to realize that these models have been designed to develop atherosclerotic lesions in weeks to months, which normally take decades to develop in spontaneously occurring disease. Animal models of atherosclerosis develop lesions spontaneously or induced by dietary modifications, mechanical, chemical, immunological interventions, or by use of defective animals or genetic manipulations.(Moghadasian 2002)

When interpreting study results obtained from animal models, one should bear in mind the inherent limitations of such models and the difficulties in translating findings to the human disease or among animal species.(Libby et al. 2011)

ii. Rabbits

The first experimental diet-induced atherosclerosis study was conducted in rabbits.(Ignatowski 1908; Cullen et al. 2005; Moghadasian 2002) New Zealand White rabbits develop atherosclerotic lesions when fed a diet modified with 0.5-2% cholesterol, which is normally lacking from their herbivorous diet, for 4-16 weeks.(Cullen et al. 2005; Drew 2010) Since then, it has been shown that lesions may develop with feeding cholesterol amount as low as 0.1%.(Kolodgie et al. 1996). Rabbits absorb cholesterol efficiently and high plasma cholesterol is achieved. Along with cholesterol supplementation, other dietary modifications have also been implemented to induce lesions in rabbits using different types of oils and specific proteins.(Yanni 2004) Rabbits are particularly sensitive to dietary cholesterol induction of atherosclerosis due to their inability to increase sterol excretion in response to excess intake which leads to increased liver export of cholesteryl ester-rich lipoproteins into the circulation which subsequently accumulates in lesion-prone areas.(Thompson & Zilversmit 1983; MacKinnon et al. 1985; Kolodgie et al. 1996) Lesions in diet-induced atherosclerosis are usually localized in the aortic arch and ascending aorta.(Drew 2010; Moghadasian 2002; Yanni 2004) Lesions are highly lipid filled and macrophage rich and different from spontaneous lesions in humans.(Drew 2010; Cullen et al. 2005) However, feeding lower concentrations of cholesterol for longer periods or altering the source of fat may produce lesions more closely resembling those of humans.(Kolodgie et al. 1996; Kritchevsky et al. 1984; Yanni 2004) Dietary modifications can also be combined with mechanical injuries, such as performed with balloon injury, to accelerate lesion formation and stimulate the formation of a fibrous cap and a neointima.(Yanni 2004; Worthley et al. 2000) Genetic variants of the rabbit such as the Watanabe, St Thomas, and Houston RT present genetic abnormalities in lipid metabolism and

may develop atherosclerosis faster and with minimal dietary modifications.(Yanni 2004) Transgenic rabbits with altered gene expression have also been produced such as with increased apoA-1 expression, overexpression of LCAT (involved in HDL metabolism), apolipoprotein(a), or lipoprotein lipase which leads to a reduction in LDL and VLDL concentrations.(Yanni 2004; Moghadasian et al. 2001) Plaque rupture has been induced in rabbits by balloon injury.(Vilahur et al. 2011)

Rabbits possess similarities to humans in their lipoprotein metabolism: similar composition of apolipoprotein B containing lipoproteins, production by the liver of apo B₁₀₀-containing VLDL, plasma cholesteryl ester transfer protein (CETP) activity, and efficient absorption of dietary cholesterol.(Moghadasian et al. 2001) Watanabe heritable hyperlipidemic rabbit constitutes a model for human familial hypercholesterolemia and have a defect in membranous LDL receptor.(Drew 2010; Yanni 2004; Watanabe 1980)

Rabbits models have been used in studies investigating lesion characterization, pathogenesis, therapeutics, mechanical injury, and arterial metabolism.(Drew 2010; Yanni 2004) Disadvantages of rabbit models of atherosclerosis include differences in lesion location and composition with humans, absence of spontaneous disease without experimental modification, deficiency in hepatic lipase, cholesterol storage syndrome and that hepatotoxicity may develop on prolonged cholesterol feeding.(Yanni 2004; Drew 2010; Moghadasian et al. 2001)

iii. Swine

Swine develop spontaneous atherosclerosis in the coronary arteries. They can develop fatty streaks at 6 months and advanced lesions when older than a year.(Gottlieb & Lalich 1954; Drew 2010) Pig lesions show a high degree of similarity to human atherosclerosis but regular pigs do not develop intralesional haemorrhage or thrombosis.(Drew 2010; L Badimon 2001) Lesions are typically induced by cholesterol feeding but can occur when fed a normal porcine diet for a long time.(Singh et al. 2009; Moghadasian 2002) Pigs may develop fibrofatty lesions in about 14 weeks and atheromatous plaques in 24 weeks.(Holvoet et al. 1998; Badimon 2001) A pig variety (white Belgian) also experiences acute death from coronary disease when under stress.(Badimon 2001) Some lines of naturally defective pigs with apolipoprotein-associated mutations (Lpb5, Lpr1, Lpu1) develop hypercholesterolemia and accelerated atherosclerosis without dietary manipulation.(Prescott et al. 1991) Miniature swine are used preferentially for economic reasons and some breeds are highly susceptible to diet-induce disease (e.g. Yucatan miniature pig).(Drew 2010; Reitman et al. 1982) Microminipigs have also been used recently.(Kawaguchi et al. 2011) The IHLC (inherited hyperlipoproteinemia and hypercholesterolemia) pig is an inbreed strain with reduced catabolism of LDL that develops advanced atherosclerosis at an accelerated rate.(Rapacz & Hasler-Rapacz 1989)

Swine are popular models for atherosclerosis research because they develop spontaneous lesions in similar locations (in particular the coronary arteries) and have similar cardiovascular anatomy to humans, they are omnivorous with a tendency to overeat, they share similarities in lipoprotein metabolism and atherogenic pathways with humans, and they are large enough for cardiovascular surgery, angioplasty, and cardiac imaging.(Drew 2010; Moghadasian et al. 2001; Paslawski et al. 2011; Singh et al. 2009; Vilahur et al. 2011) Disadvantages of pig models of atherosclerosis include the cost and facilities for maintaining pigs in laboratories and handling.(Cullen et al. 2005; Badimon 2001)

iv. Guinea pigs

Guinea pigs develop diet-induced atherosclerosis and, as humans, transport the majority of their cholesterol in LDL and possess plasma CETP activity, which is different from other rodent models.(Fernandez & Volek 2006; West et al. 2003; Singh et al. 2009; Xiangdong et al. 2011) They also show lecithin/cholesterol acyltransferase and lipoprotein lipase activities.(Fernandez & Volek 2006; Singh et al. 2009) Ovariectomized guinea pigs have been used as animal models of atherosclerosis in post-menopausal women because of similar plasma lipid profile.(Fernandez & Volek 2006) Guinea pig models have been used to study diet intervention (fat saturation of the diet, influence of fibers, dietary supplements) and drug investigations. Disadvantages are that guinea pigs require constant supplementation with vitamin C which is an antioxidant and may interfere with atherosclerosis induction, they do not develop advanced lesions, and there is a lack of antibodies available for research.(Singh et al. 2009; Fernandez & Volek 2006)

v. Hamsters

Hamsters fed an atherogenic diet develop hypercholesterolemia and atherosclerosis. Dietary manipulation causes a drastic increase in LDL / VLDL cholesterol and a decrease in HDL cholesterol. In addition, golden-Syrian hamsters have plasma CETP activity and receptor-mediated uptake of LDL.(Moghadasian 2002; Dillard et al. 2010; Xiangdong et al. 2011; Singh et al. 2009) Several strains, in particular the F1B, have been obtained to study diet-induced atherosclerosis. They develop mild to moderate lesions in the ascending aorta after several months of feeding.(Xiangdong et al. 2011; Dillard et al. 2010) However, hamster models are no longer considered to be suitable to study experimentally-induced atherosclerosis due to inconsistency in the development of lesions regardless of dietary modifications and the absence of advanced lesions.(Dillard et al. 2010; Singh et al. 2009)

vi. Rats

Rats are highly resistant to atherosclerosis even with increased dietary cholesterol. Therefore genetic manipulations are usually necessary to induce the lesions. Unlike humans, rats do not have plasma CETP activity and most of the cholesterol is transported through HDL particles.(Xiangdong et al. 2011) Atherosclerotic lesions present major differences with humans. These major limitations hamper the use of rat models in atherosclerosis research. Nevertheless, inbred strains of rats with inherited hypercholesterolemia are more prone to atherosclerosis and consequently have been used in atherosclerosis research.(Xiangdong et al. 2011; Singh et al. 2009) Transgenic rats have been produced, notably the CETP transgenic Fisher rat which shows a high increase in non-HDL cholesterol when fed atherogenic diets.(Singh et al. 2009) Rats have been used to study vascular inflammation, hyperlipidemia, hypertension, and angioplasty.(Singh et al. 2009) Sand rats have a propensity to become obese and insulin resistant and may be a good model for atherosclerosis associated with type II diabetes.(Singh et al. 2009)

vii. Mice

Mice are undoubtedly the most widely used animal models in atherosclerosis research and contemporary research is dominated by the use of murine models. Like rats, mice are naturally resistant to atherosclerosis but the recent use of transgenic and knockout technology to create various atherosclerosis-prone lines stimulated their use.(Xiao 2010; Daugherty & Rateri 2005) Also similar to rats and unlike humans, mice do not have plasma CETP activity and most plasma cholesterol is found in HDL.(Moghadasian et al. 2001) The small size of mice also limits

frequent blood sampling and dissection of small arteries. Nevertheless, mice models of atherosclerosis are popular because their genetic makeup is well-defined, the low cost allows for the use of a large number of animals, they breed and can be easily handled, and a large number of transgenic lines are available.(Moghadasian et al. 2001; Xiangdong et al. 2011)

In some inbred strains of mice such as in the C57BL/6J, mild atherosclerosis can be induced by dietary modification with a high fat / high cholesterol atherogenic diet that also typically includes cholic acid and is referred to as the Paigen diet.(Nishina et al. 1990; Jawien et al. 2004; Paigen et al. 1985) Cholic acid has the ability to induce inflammation, hence enhancing atherogenesis. Lesions are usually confined to the aortic root and rarely progress to advanced stages.(Jawien et al. 2004) In transgenic models, lesions are also frequently amplified by dietary modifications with western-type diet (0.15% cholesterol, 21% fat), which is more physiological than an atherogenic diet.(Xiao 2010; Daugherty & Rateri 2005) To investigate specific atherogenesis pathways and given that atherosclerosis is strongly linked to dyslipidemia, various models have been established by genetic manipulation of the lipid metabolism. The genetic background of the transgenic mice also plays a significant role in atherosclerosis susceptibility.(Dansky et al. 2002) Apolipoprotein E knockout mice (apoE^{-/-}) was the first gene deletion performed in murine models.(Jawien et al. 2004; Xiao 2010; Daugherty & Rateri 2005; Xiangdong et al. 2011; Moghadasian et al. 2001; Piedrahita et al. 1992) This deficiency leads to accumulation of atherogenic lipoprotein particles (apoE is a ligand of LDL receptor), lower HDL concentration, elevated cholesterol and triglycerides levels in the blood, and apoE^{-/-} mice spontaneously develop reproducible and advanced atheromatous plaques even in the absence of dietary modification. The characteristics of the lesions present in this model are relatively similar to humans with the presence of fatty streaks that progress to advanced lesions with a lipid core which frequently displays calcified areas covered by a fibrous cap.(Daugherty & Rateri 2005) Plaque rupture is also seen in apoE^{-/-} mice atherosclerotic lesions.(Johnson et al. 2005) ApoE^{-/-} mouse models have been used for experiments on atherogenesis, risk factors, and to assess and screen for therapies.(Daugherty & Rateri 2005) LDL receptor deficient (LDLR^{-/-}) mice are used as a model of human familial hypercholesterolemia and atherosclerosis and need to be fed an atherogenic diet to obtain advanced lesions.(Ishibashi et al. 1993; Daugherty & Rateri 2005; Xiao 2010) ApoE/LDLR double knock-out mice have been created to develop both severe hyperlipidemia and atherosclerosis.(Ishibashi et al. 1994) Transgenic mice expressing normal (apoE2, apoE3) and defective variants (e.g. APOE*Leiden, APOE R142C) of the human apolipoprotein E have also been produced to study inherited human dyslipidemia.(Xiao 2010) These strains need additional dietary stimulation to develop significant lesions. A large number of other transgenic variants (overexpression of apoB₁₀₀, apo(a), apoC-III, Lp(a), CETP, LCAT, knockout of CD36, SR-A) have been generated and have been used to understand further the mechanism of the disease and screen newer drugs.(Singh et al. 2009; Xiao 2010; Moghadasian et al. 2001; Penn & Chisolm 2005) Cross-breeding of different transgenic mice results in the production of additional strains with specific characteristics. Experimental hypertension, one of the major risk factor of atherosclerosis and plaque rupture has been induced in transgenic mice using angiotensin II or deoxycortisone acetate salt administration.(Singh et al. 2009; Weiss et al. 2001; Weiss & Taylor 2008)

viii. Non-human primates

Non-human primates are phylogenetically close to humans and eat an omnivorous diet. They have similarities in lipoprotein composition and metabolism. Mild lesions may develop

spontaneously but feeding an atherogenic diet can induce advanced lesions. Lesions are similar to humans, present plaque calcification, and can be complicated with thrombosis leading to myocardial infarction.(Drew 2010; Singh et al. 2009) Therefore results obtained in these species may be more directly applicable to humans. New world monkeys are of limited use in atherosclerosis research due to severe complications such as chronic renal disease that are associated with atherogenic diets, inconsistent development of lesions, and a different anatomical distribution.(Clarkson 1998; Drew 2010) Old world monkeys such as rhesus and cynomolgus monkeys developed more consistent lesions and show sex predilection similar to humans.(Clarkson 1998; Drew 2010) Other old world primates that have been used include baboon, pigtail, stumptail, green monkey, and chimpanzees.(Singh et al. 2009; Blaton & Peeters 1976; Rainwater et al. 2009) Familial LDL receptor deficiency has been reported in rhesus monkey.(Scanu et al. 1988) Some laboratory assays designed for humans cross-react with monkeys.(Vilahur et al. 2011) Non-human primates have been used to study thrombosis associated with atherosclerosis, platelet function, pharmacokinetics of anti-atherosclerosis drugs, risk factors, and vascular surgery.(Vilahur et al. 2011; Singh et al. 2009; Rainwater et al. 2009) Disadvantages of the use of primates include expense, difficulties in maintenance and handling, availability, endangered species, and ethical considerations.(Drew 2010)

ix. Dogs and cats

Dogs and cats are extremely resistant to atherosclerosis and spontaneous lesions are rare. Dogs lack plasma CETP activity and HDL particles are their main cholesterol transporters.(Xiangdong et al. 2011) Experimental diet-induced atherosclerosis is possible with very high cholesterol content (5%) and saturated fat but advanced lesions are not common.(Xiangdong et al. 2011; R.W. Mahley et al. 1974; Singh et al. 2009) Beagles have similarities with humans in their lipid metabolism and have been used to study statin therapy.(Singh et al. 2009) Due to their large size, dogs are used for imaging studies, cardiovascular surgeries, atherothrombosis, and myocardial infarction.(Singh et al. 2009; Vilahur et al. 2011) Limitations include poor response to dietary induction, large amount of experimental agents needed, and ethical concerns.(Singh et al. 2009; Xiangdong et al. 2011; Moghadasian et al. 2001)

III. Avian atherosclerosis

A. Peculiarities of avian lipoprotein metabolism

Lipids are present throughout the avian body but most significant deposits are found in adipose tissues and, to a lesser extent, in the liver. Adipose tissues can be found in the abdomen (mainly) and subcutaneous and intramuscular tissues. The capacity of birds for storing fat exceeds that of any other class of vertebrates. Their lymphatic system is poorly developed and they have differences in bile composition and anatomy of the pancreatic duct that enters the distal portion of the duodenum.(Petzinger et al. 2010; King & McLelland 1984)

Triglycerides, cholesterol, and cholesteryl ester are present in the tissues and they are either acquired through the diet or produced *de novo*. Triglycerides are produced in the liver and lipogenesis is limited in the adipose tissue unlike in mammals.(Alvarenga et al. 2011) Similar enzymatic pathways are present in avian tissues with for instance HMG-CoA reductase and synthase. Also the large lipid deposits in the egg yolk have to be transported from the liver to the oocyte. As in mammals, most lipids are transported in the form of lipoproteins in order to solubilize lipids in the blood and interact with a variety of receptors in effector cells. The same

VLDL, IDL, LDL, HDL fractions are present but lipoprotein (a) has not been described in avian species yet. Similar HDL subfractions found in mammals are also present in birds.(Petzinger et al. 2011; Langelier et al. 1976) Lipoproteins have been mostly studied in the domestic fowl for commercial reasons and in avian models of atherosclerosis, notably the pigeon and the Japanese quail.(Wu & Donaldson 1982; Nagata et al. 1997; Iwasaki et al. 2000; Hammad et al. 1998; Alvarenga et al. 2011; Jones 1997; Langelier et al. 1976; Barakat & St Clair 1985; Schwenke & St Clair 1993; Hermier 1997) The roles of the different classes of lipoproteins are similar to mammals but a few differences exist. VLDL serve to transport endogenous lipids but also exogenous lipids from the small intestines.(Stevens 1996) In addition, since birds do not have a well-developed lymphatic system, triglycerides absorbed from gastrointestinal system are transported directly to the liver via the liver portal system as portomicrons, chylomicrons are not present.(Stevens 1996) Most birds transport the majority of their cholesterol as HDL.(Lizenko et al. 2007; Langelier et al. 1976; Anderson et al. 2012; Barakat & St Clair 1985; Suckling & Jackson 1993) Similar apolipoproteins are found in birds but some differences in structure and repartition in the lipoproteins are present. No apoE and apoB-48 have been detected in avian species.(Singh et al. 2009; Moghadasian et al. 2001; St Clair 1998) The avian apoA-I has some homology with the mammalian apoA-I but is a monomer and possess activities similar to the mammalian apoE. ApoB-100 is the main lipoprotein present in portomicrons, VLDL, IDL, and LDL and apoA-I the main lipoprotein present in HDL. Avian LDL have the ability to bind mammalian LDL receptors which demonstrates similarities in structure and function. Similar important transfer proteins and enzymes are present in birds such as LCAT, CETP, lipoprotein lipase, scavenger receptors, and ABCA-1.(Alvarenga et al. 2011; Anderson et al. 2012)

One major difference from mammals is that birds need to transport lipid synthesized in the liver to the developing oocyte to form the future egg yolk. Lipoproteins responsible for this process are VLDL and vitellogenin (VTG), a special type of lipoproteins, which are regulated by estrogen secretion. Apo VLDL-II is a unique apolipoprotein present in yolk-labelled VLDL_y and induced by estrogens that have anti-lipoprotein lipase activities.(Alvarenga et al. 2011; Walzem et al. 1999) VLDL_y are smaller than standard VLDL to pass through the granulosa basal lamina to reach receptors of the LDL family (LR8) located on the oocyte surface.(Schneider 2009) ApoB of VLDL_y binds to these receptors.(Alvarenga et al. 2011) VTG is a very high density lipoprotein targeting exclusively the yolk via the same receptor-mediated endocytosis. During the egg formation, total cholesterol, triglycerides, VLDL, total proteins, and protein-bound calcium increase dramatically and may have some implications in the pathogenesis of atherosclerosis in female birds.(Lumeij 2008; Alvarenga et al. 2011) Hematologic changes also occur, including a slight increase in the total white blood cell and red blood cell counts.(Joyner 1994)

B. Avian models of atherosclerosis

i. Pigeons (*Columbia livia*)

The pigeon has been one of the most used animal models in atherosclerosis research since the first demonstration of the lesion in 1959.(Clarkson et al. 1959) Its use is falling out of favor since the emergence of transgenic animals, notably mice. One of the main features of avian models is that they spontaneously develop atherosclerosis with aging. The White Carneau (WC) pigeon is very susceptible to atherosclerosis even on standard grain diet while the show racer (SR) pigeon is relatively resistant. This difference in susceptibility lies at the level of the aortic wall, is an autosomal recessive genetic trait, and may be expressed by aortic SMC.(Smith, Smith, et al.

2001; Anderson et al. 2012) On a standard grain diet (cholesterol-free), WC pigeons develop lesions in 3-4 years, mainly in the thoracic aorta at the bifurcation of the celiac artery.(St Clair 1998; St Clair 1983; Santerre et al. 1972) When atherosclerosis developed in coronary arteries, lesions involve mainly the intramyocardial coronary arteries and seem to occur independently from aortic lesions.(St Clair 1998) Pigeons respond well to cholesterol feeding to accelerate lesion formation typically at 0.5-1%. Also, pigeons are naturally hypercholesterolemic when compared to humans.(Anderson et al. 2012) As in most birds, the majority of the cholesterol is transported in HDL but β -VLDL and LDL are predominant in cholesterol-fed birds. However, in less than 3 day old nestlings, cholesterol is mainly transported in the form of LDL.(Anderson et al. 2012) WC pigeons have a higher plasma cholesterol levels than SR, a higher percentage of plasma esterified cholesterol, and higher sterol and sterol ester arterial concentrations but these differences are relatively mild and often not statistically different.(St Clair 1998; Subbiah et al. 1970; Langelier et al. 1976; Barakat & St Clair 1985; Anderson et al. 2012) When fed a cholesterol rich diet, total cholesterol and LDL cholesterol increase by about 5-15 times.(Barakat & St Clair 1985; Bavelaar & Beynen 2004b) Pigeons have been widely used to study the pathogenesis of atherosclerosis and its genetic determinants.(St Clair 1998; Prichard et al. 1962; Jerome & Lewis 1990; Schwenke & St Clair 1993; Lewis et al. 1985; Jerome & Lewis 1997; Taylor & Lewis 1986) The histopathology and ultrastructure of the pigeon atherosclerotic lesions are similar to humans with the presence of extra and intracellular fat and cholesterol, fibrous tissues, SMC- and macrophages-derived foam cells.(St Clair 1998; Santerre et al. 1972; Lewis et al. 1985; Barr et al. 1991; Hansen 1977) Furthermore, endothelial changes consistent with endothelial activation and monocyte adhesion to the endothelium have been demonstrated by electron microscopy.(Li 1989; Lewis & Kottke 1977; Taylor & Lewis 1986; Jerome & Lewis 1984) Macrophage foam cells appear early in the lesion formation and phenotypic switch of SMC from a contractile to a synthetic phenotypes was observed.(Jerome & Lewis 1984; St Clair 1998; Wight et al. 1977; Li 1989) Complications are also encountered with advanced lesions including hemorrhage, ulceration, mineralization, and thrombosis leading to myocardial ischemia, which constitute a major advantage of pigeon models.(St Clair 1998; Anderson et al. 2012; Prichard et al. 1963) Comparative studies between the WC and SR pigeons have demonstrated some constitutive differences in the arterial wall with a higher level of glycosaminoglycans (in particular chondroitin-6-sulfate known to bind to LDL), lipid, cholesterol esters, and metabolic differences.(Anderson et al. 2012; Santerre et al. 1972) Furthermore, an *in vitro* proteomic experiment showed differential gene expression between aortic SMC cultured from both breeds. In SR, genes expressed were more indicative of a contractile phenotype whereas WC expressed proteins reflecting a synthetic phenotype as well as the production of proteases and inflammatory signals.(Smith et al. 2008)

Unlike chickens, no relationship has been observed between columbid herpesvirus infection and atherosclerosis. Main advantages of the pigeon model are that atherosclerotic lesions occur spontaneously, complications and myocardial ischemia arise, and lesions are similar to humans. Disadvantages are those shared by all avian models, the differences from mammals in lipoproteins composition and metabolism, particularly in reproductively active females, and differences in arterial microanatomy (no SMC in intima, fibroblast-like cells in the media).(Anderson et al. 2012; Moghadasian 2002; Stout & Thorpe 1980)

ii. Japanese quails (Coturnix coturnix japonica)

Japanese quails develop diet-induced atherosclerosis and myocardial infarction and were first used as a model in 1972.(Ojerio et al. 1972) Susceptible and resistant strains are described. Similar to pigeons, coronary atherosclerosis developed primarily in intramyocardial coronary arteries. Lesions are similar to humans.(Bocan et al. 1994; Chapman et al. 1976) The SEA (susceptible to experimental atherosclerosis) quail strain is highly susceptible to diet-induced lesions and become hypercholesterolemic with a shift from HDL to VLDL and LDL as the main lipoproteins in the blood.(Radcliffe & Liebsch 1985; Shih et al. 1983) Increased levels of dietary cholesterol correlate with the severity of the lesions which can progress to stenosis and infarction.(Shih et al. 1983) Depending on the strain and experimental protocol, quails typically develop lesions from 10-15 weeks to 9-28 months.(Bavelaar & Beynen 2004b) Quails have been extensively studied for therapy but also in studies on the role of viruses in lesion development.(St Clair 1998; Day et al. 1977) Advanced atherosclerosis can take up to 2 years to occur with cholesterol feeding. The main advantage of quails is their low cost and small size.

iii. Chickens (Gallus gallus domesticus)

Chickens develop atherosclerotic lesions naturally in the aorta and coronary arteries and cholesterol feeding accelerates the development of lesions.(St Clair 1998; Dauber & Katz 1943) Lesions are initially fibrous and can be induced in as little as 2 weeks.(Xiangdong et al. 2011) As in women, estrogen reduced atherosclerosis in chickens, mainly in the coronary arteries.(Pick et al. 1952) Chickens are naturally hypercholesterolemic but transport most of their cholesterol in HDL. Addition of estradiol to the diet can stimulate the development of lesions in chickens.(Toda et al. 1981) Some lines of chickens deficient in VLDL, LDL, or HDL have been described.(Ayala et al. 2005) Marek's disease, an herpesvirus, has also been shown to promote atherosclerotic lesions in chickens. Mechanical denudation of the endothelium has been performed in chickens to induce focal atherosclerotic lesions.(Lucas et al. 1996) Additional advantages of chickens are that they are omnivorous and are cost effective to maintain.

iv. Others

Turkeys develop atherosclerosis naturally which can lead to aortic aneurysm.(Gresham & Howard 1961) Atherosclerotic lesions have also been encountered in wild turkeys.(Manning & Middleton 1972; Krista & McQuire 1988) Aortic aneurysm has been suggested to be related to copper deficiency and hypertension. Turkeys have high systemic arterial blood pressure, the highest recorded in vertebrates.(Smith et al. 2000)

Budgerigars have been used once in 1962 and developed severe atherosclerosis on a 2% cholesterol diet with 15% lard after 2-6 months.(Finlayson & Hirschinson 1961) Budgerigars have also been used for *in vivo* thrombosis assay.(Schmaier et al. 2011)

Several other avian species have been fed atherogenic diet anecdotally but these species have many experiments.

C. Psittacine atherosclerosis

i. Epidemiology and risk factors

The prevalence of atherosclerosis has been documented in multiple sources and ranges from 1.9% to 91.8% (Table 22).(Bavelaar & Beynen 2004a; Garner & Raymond 2003; Johnson et al. 1992; Pilny 2004; Fricke et al. 2009; Krautwald-Junghanns et al. 2004; Pilny et al. 2012; Bavelaar & Beynen 2003; Kellin 2009; Grunberg 1964; Finlayson 1965) The wide range of

reported prevalence is likely due to reports varying in inclusion criteria, lesion severity, geographical area, demographics and captive conditions of the studied population, psittacine species, and retrospective or prospective nature of the work. In one study reporting a relatively high number of psittacine cases, after review of the original database, the population was found to be composed for the most part of neonates and juvenile birds.(Johnson et al. 1992) In a prospective study, all types of atherosclerotic lesions also comprising early stages were included in calculation of the prevalence which lead to the highest reported prevalence of atherosclerosis in the literature (91.8%).(Fricke et al. 2009) While such a high variability in reported prevalence precludes a correct appreciation of the true importance of atherosclerosis in the captive psittacine population, previous investigations make clear that the condition can be frequent in some captive psittacine bird populations. The main drawback of previous pathology surveys is the lack of well-defined histopathologic inclusion criteria based on an established classification system of psittacine atherosclerotic lesions. For instance, some authors established their own classification system based on histopathology while others only used macroscopic criteria such as Sudan staining of arteries.(Fricke et al. 2009; Schenker & Hoop 2007; Bavelaar & Beynen 2004a) Also, the prevalence for pathologic lesions including early and mild lesions that seldom lead to clinical signs is of suspect clinical use, especially since it can be expected to vary significantly with age groups. Most studies focused on the pathologic lesions with little attention being drawn to estimating the prevalence of atherosclerosis-induced diseases and the clinical aspects of atherosclerosis. Finally, correct statistical analyses with at *minima* an estimation of the precision of the prevalence being reported (e.g. confidence intervals) were not performed in any study previously published which were most often limited to the documentation of raw percentages.

Table 22: Prevalence of atherosclerosis in Psittaciformes as reported in the literature sorted by year of publication (methods, inclusion criteria, and population demographics varied substantially between reports, %: raw prevalence, N: total number of birds investigated)

N	%	Genera	Country	Year	Reference
1157	2.3	Unspecified	USA	1933	H. Fox 1933
97	39.9	Unspecified	Belgium	1964	Grunberg 1964
126	22	Unspecified	UK	1965	Finlayson 1962
72	8.3	Unspecified	The Netherlands	1977	Dorrestein 1977
1322	2.8	Multiple genera	USA	1983	Griner 1983
394	8.9	<i>Amazona</i> , <i>Psittacus</i> , <i>Ara</i> , <i>Cacatua</i>	The Netherlands	1987	Kempeneers 1987
194	84.0	<i>Amazona</i> , <i>Psittacus</i> , <i>Ara</i> , <i>Cacatu</i> , <i>Eclectus</i>	The Netherlands	2003	Bavelaar 2003
3678	2.6	Unspecified	USA	2003	Garner 2003
107	13	22 genera	Germany	2004	Krautwald 2004
912	4.6	Unspecified	USA	2004	Pilny 2004
97	91.8	<i>Amazona</i> , <i>Psittacus</i>	Germany	2009	Fricke 2009
1298	1.9	Multiple genera	Spain	2009	Kellin 2009

Several risk factors have been suggested that may promote the development of atherosclerosis in psittacine birds and include age, gender, species, increased plasma total cholesterol and triglycerides, high energy and high fat diet, physical inactivity, thyroid disease, and co-infection

with *Chlamydophila psittaci*.(Bavelaar & Beynen 2004a; Reavill & Dorrestein 2010; Fricke et al. 2009; Pilny et al. 2012; Johnson et al. 1992; Garner & Raymond 2003; Bavelaar & Beynen 2003) Unfortunately, a clear demonstration of a statistically significant effect from any of these variables controlling for potential confounding factors such as age, gender, or species was often not done or not performed on a large representative sample. While a higher prevalence or severity of atherosclerotic lesions is often reported in older birds,(Bavelaar & Beynen 2004a; Fricke et al. 2009; Bavelaar & Beynen 2003; Kellin 2009; Pilny et al. 2012; Garner & Raymond 2003) a clear quantification of magnitude of the effect of age on the prevalence is not available. The influence of gender as a risk factor is also unclear from the literature with some studies reporting a male predisposition,(Fox 1933; Griner 1983) others a female predisposition,(Garner & Raymond 2003) and others no difference between genders.(Pilny et al. 2012; Johnson et al. 1992; Bavelaar & Beynen 2003) African grey parrots (*Psittacus erithacus*) and Amazon parrots (*Amazona* spp.) usually show a higher prevalence of lesions than other psittacine species but confounding effects of age and sex were usually not taken into consideration in these reports.(Fricke et al. 2009; Bavelaar & Beynen 2004a; Bavelaar & Beynen 2003)

A possible association between *Chlamydia pneumoniae* infection and atherosclerosis has been investigated in multiple studies in humans but remains controversial.(Dugan et al. 2002; Sessa et al. 2009; Hoymans et al. 2007) Since avian chlamydiosis is a common infection in psittacine species, this hypothesis was also explored in parrots but with mixed results. A study using PCR and immunohistochemistry on arterial tissues did not conclude to a positive association between atherosclerosis and avian chlamydiosis in psittacine birds.(Schenker & Hoop 2007) Pathologic surveys rarely identified lesions consistent with avian chlamydiosis concurrently with atherosclerosis.(Fricke et al. 2009) Conversely, a separate case-control study on 31 parrots reported a significant association between atherosclerosis and positive immunohistochemical (IHC) reaction for *C. psittaci* using specific anti-*C. psittaci* monoclonal antibodies in arterial tissues.(Pilny et al. 2012) However, anti-*Chlamydia* antibodies including monoclonal antibodies used in IHC are known to cross-react with atherosclerotic plaque constituents in human samples such as ceroids.(Dowell et al. 2001; Hoymans et al. 2007; Hoymans et al. 2004) Poor correlation has been observed between IHC, tissue PCR, and culture and the former usually leads to a higher detection rate. For immunohistochemistry involving chlamydial antigens, one should carefully select negative control tissues, use at least two negative control antibodies, and only intracytoplasmic staining of macrophages, endothelial cells, and smooth muscle cells in a granular pattern should be interpreted as true positive.(Dowell et al. 2001) In this psittacine study, negative controls were avian tissues including blood vessel but negative control antibodies were not used to assess background staining of atherosclerotic tissues and extracellular staining in lipid and necrotic pools were interpreted as positive, thus increasing the possibilities of false positives.(Pilny et al. 2012) Alternatively, *C. psittaci* PCR-negative psittacine atherosclerotic tissue could have been used as negative control tissues.

Dyslipidemic changes with notably hypercholesterolemia are thought to predispose to the development of atherosclerotic lesions as in other animal species. African grey and Amazon parrots, which are thought to be predisposed to atherosclerosis, tend to have a higher plasma cholesterol level than other psittacine species.(Bavelaar & Beynen 2004a) Total plasma cholesterol correlates with the occurrence of atherosclerosis in psittacine birds but changes in lipoproteins have not yet been investigated.(Pilny et al. 2012) In a case-control study on 22 birds, parrots with atherosclerotic lesions had a significantly higher median (range) plasma cholesterol based on their medical records at 421 (233-906) mg/dL than control birds at 223 (144-250)

mg/dL.(Pilny et al. 2012) The impact of diet on atherosclerosis and dyslipidemia has been investigated in a few studies. Atherosclerosis has been induced in budgerigars with 2% dietary cholesterol but this amount is about 100-200 times higher than found in a normal diet.(Finlayson & Hirschinson 1961; Petzinger et al. 2010) In a feed trial, African grey parrots fed a high-fat diet rich in saturated fatty acids had significantly higher plasma cholesterol levels than parrots on a low-fat diet or high-fat diet enriched in omega-6 unsaturated fatty acids (linoleic acid).(Bavelaar & Beynen 2003) Another feed trial in African grey parrots did not demonstrate a significant difference in cholesterol and lipoprotein plasma concentrations between groups on a pelletized or seed diets.(Stanford 2005) The intake of unsaturated fatty acids, especially omega-3 fatty acids, may protect against atherosclerosis in parrots.(Petzinger et al. 2010; Bavelaar & Beynen 2003) The severity of atherosclerosis negatively correlates with muscle and adipose tissue content of α -linolenic acid in parrots.(Bavelaar & Beynen 2003) Feeding Quaker parrots (*Myiopsitta monachus*) a diet rich in omega-3 unsaturated fatty acids caused a shift in the peak densities of HDL subfractions but total plasma cholesterol was not altered whereas the same dietary changes usually lower the cholesterol in mammals.(Petzinger 2012; Petzinger et al. 2011)

ii. Pathology

In parrots, atherosclerotic lesions are central and most commonly found in the great arteries at the base of the heart, brachiocephalic arteries, ascending aorta, and pulmonary arteries.(Bavelaar & Beynen 2004a; Garner & Raymond 2003; Krautwald-Junghanns et al. 2004; Lumeij & Ritchie 1994; Pees, Krautwald-Junghanns, et al. 2006; StLeger 2007; Reavill & Dorrestein 2010) Lesions in the abdominal aorta and peripheral arteries appear less frequent. However, peripheral lesions have been documented in the abdominal aorta, carotid, and coronary arteries in parrot species.(Johnson et al. 1992; Mans & Brown 2007; Vink-Nooteboom et al. 1998; Finlayson & Hirschinson 1961; Shivaprasad 1993; Finlayson 1965; Finlayson et al. 1962) In addition, a retrospective survey revealed 35% of birds diagnosed with atherosclerosis had peripheral lesions.(Garner & Raymond 2003) Atherosclerotic lesions are rarely complicated by thrombosis, hemorrhage, and plaque ruptures in parrots and myocardial infarction is rare. While confirmation is lacking, other histopathologic lesions are thought to occur in association with atherosclerosis such as hepatic lipidosis/fibrosis and yolk coelomitis.(Garner & Raymond 2003) Furthermore a recent study identified a correlation between atherosclerosis of the ascending aorta and organ alterations such as myocardial hypertrophy, myocardial fibrosis, pulmonary congestion and fibrosis.(Fricke et al. 2009)

In parrots, histologic lesions are reported to begin in the media and further extend in the media and intima. Atherosclerotic lesions are characterized, depending on the stage, by foam cells, presence of lipid, cholesterol clefts, chondroid metaplasia, fibrosis, and mineralization.(Fricke et al. 2009; Garner & Raymond 2003; Reavill & Dorrestein 2010; Schmidt et al. 2003) Macroscopically, fatty streaks and fibrous plaques are also recognized.(Bavelaar & Beynen 2003; Bavelaar & Beynen 2004a) Rupture of the fibrous cap and exposure of the lipid core content to the lumen is rarely reported in birds which may explain why thromboembolic events are uncommon. In two recent psittacine atherosclerosis pathology studies, atherosclerotic lesions were classified into four stages, one of these studies was conducted on Amazon and African grey parrots using histopathology, histochemistry, and immunohistochemistry.(Fricke et al. 2009; Schenker & Hoop 2007) Stage 1 was characterized by the fragmentation of elastic layers and increased extracellular matrix in the media, stage 2 by fat deposition in the intima and media, stage 3 by an increased presence of collagen fibers, and stage 4 by a fibrous appearance of the

plaque.(Fricke et al. 2009) This classification contrasts with those established in mammals, humans, and other avian orders.(Fricke et al. 2009; Stary et al. 1994; Stary et al. 1995; Stary 2005; Santerre et al. 1972; Orita et al. 1994; He et al. 2005) In humans, the classification accepted by the AHA divides lesions into 8 stages. The predominant cellular component of human and animal lesions are macrophages, smooth muscle cells, and, in lesser number, lymphocytes. Surprisingly, in the proposed classification of atherosclerosis in parrots, macrophages and smooth muscle cells were not found based on histology and immunohistochemistry in any stage.(Fricke et al. 2009) Moreover, the initiation and maintenance of atherosclerotic lesion in parrots is believed to occur mainly in the media.(Fricke et al. 2009; Schmidt et al. 2003) These observations contrast with what is known in other species and the current widely-accepted theory that atherosclerosis is initiated by endothelial dysfunction and the accumulation of oxidized lipoproteins in the intima and the chronic inflammatory response that ensues.(Stary et al. 1994; Cullen et al. 2005; George & Lyon 2010) Although fat deposition occurs in the tunica media and intima in several avian species, early lesions are found predominantly in the intima and the atherosclerotic plaques contain macrophages and smooth muscle cells.(Beaufrere, Holder, et al. 2011; Casale et al. 1992; Hansen 1977; Jerome & Lewis 1984; Simpson & Harms 1969; St Clair 1998) In an experimental induction of atherosclerosis in budgerigars, atheromatous plaques formed in the intima and inner media of the arteries.(Finlayson & Hirschinson 1961) It is possible that some lesions classified as stage I of the parrot classification, which do not contain any lipid, may be attributable to aging of the vessels or response of the media smooth muscles cells to arterial inflammation. Also, in more advanced lesions, the disruption of normal intimal and medial architecture, the migration of cellular elements into the intima, and the reorganization of the arterial wall may complicate one's ability to determine the origin of the lesions.(Stary et al. 1992; Stary et al. 1994; Nakamura & Ohtsubo 1992)

Clearly, there is a need for a better classification system in psittacine atherosclerotic lesions that would better reflect the progression of the lesions, the pathways of development, the clinical significance, and would be in accordance with the classification systems used in well-studied species such as humans. This is a prerequisite to designing further observational and experimental research projects as well as comparing the disease with other avian and mammalian species.

iii. Clinical signs

Clinical signs are uncommonly reported with psittacine atherosclerosis but, when present, consist of sudden death, congestive heart failure, dyspnea, neurologic signs, respiratory signs, exercise intolerance, and ataxia.(Fricke et al. 2009; Bavelaar & Beynen 2004a; Johnson et al. 1992; Lumeij & Ritchie 1994; Phalen et al. 1996; Sedacca et al. 2009; StLeger 2007; Vink-Nooteboom et al. 1998; Beaufrere, Holder, et al. 2011; Beaufrère et al. 2011; Finlayson 1965) Most clinical signs reported in parrots are associated with flow-limiting stenosis of the major arteries or the carotid arteries while clinical signs of thrombosis and thromboemboli are rare (or not diagnosed), unlike in humans. A recent experiment in budgerigars (*Melopsittacus undulatus*) revealed that *in vivo* carotid artery injury did not lead to the formation of occlusive thrombi contrary to mice in which carotid diameter and blood flow are similar to budgerigars.(Schmaier et al. 2011) Avian thrombocytes seem less capable of forming shear-resistant arterial thrombi and do not usually form 3-dimensional aggregates. The physiologic differences between avian thrombocytes and mammalian platelets may partly explain the clinical differences observed in

the nature and prevalence of atherothrombotic diseases. Also, the different pattern of coronary circulation in the avian heart with the predominance of intramyocardial arteries and possible increase in collateral circulation over humans may be responsible for the rarity of acute myocardial ischemia.

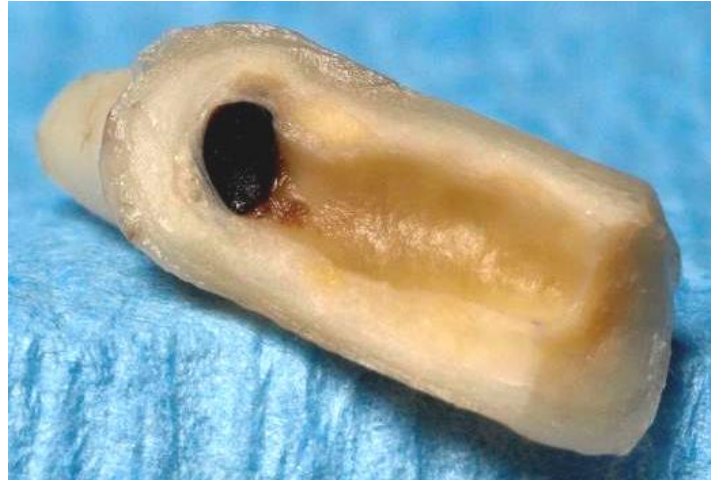

Figure 19: Wedge section of the brachiocephalic trunk in a macaw with advanced atherosclerosis. Note the severe luminal stenosis and extensive yellowish atheromatous plaque. Courtesy of Drs. W. Michael Taylor and Marina Brash, Ontario Veterinary College, University of Guelph, Canada.

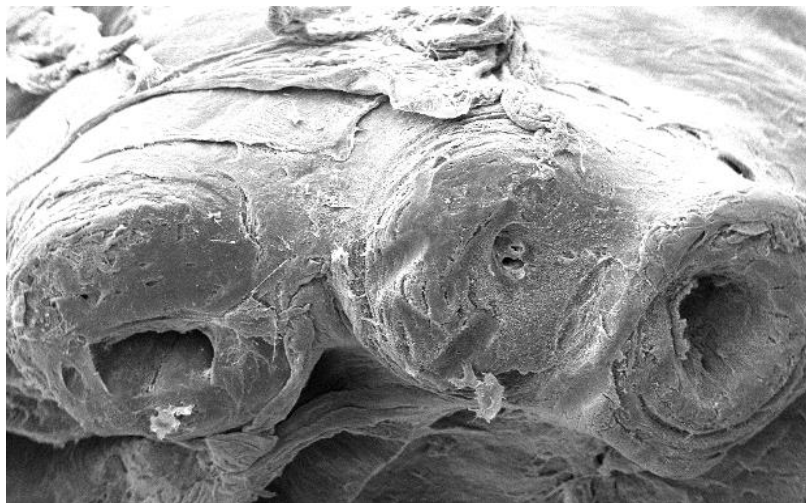


Figure 20: Scanning electron microscopy of stenotic arteries due to atherosclerosis at the base of the heart in a Quaker parrot. Note the severe stenosis with one artery almost completely obstructed. (x 60)

The extent of stenosis needed to induce clinical signs in parrots is unknown. In humans, the degree of luminal narrowing is correlated with sudden death. Clinical signs and >75% of luminal narrowing is common in fatal lesions.(Virmani et al. 2000)

Intermittent claudication, a clinical manifestation of peripheral arterial disease, was reported in an Amazon parrot with severe atherosclerotic lesions of the abdominal aorta and ischiatic arteries.(Beaufrere, Holder, et al. 2011) Cases of atherosclerosis have also been described in conjunction with pelvic limb ataxia and clinical signs compatible with intermittent claudication and peripheral arterial disease in parrots, especially in Amazon parrots.(Fricke et al. 2009; Johnson et al. 1992; Simone-Freilicher 2007; Bennett 1994) A yellow-collared macaw (*Ara auricollis*) had dry gangrene of the legs in conjunction with generalized atherosclerosis.(Finlayson 1965) Atherosclerosis was suspected as the cause of distal extremity necrosis in several zoo birds.(Calle et al. 1982)

Congestive heart failure and valvular insufficiency concurrent to atherosclerosis were also reported in several parrots.(Phalen et al. 1996; Mans & Brown 2007; Sedacca et al. 2009) The pathogenesis is unclear but chronic myocardial ischemia, systemic hypertension, and an increase in the cardiac afterload associated with decreased arterial compliance and lumen may contribute to this disease process. Also it can be postulated that the decreased myocardial oxygen supply due to stenotic arteries coupled with the increased myocardial oxygen consumption due to the increased afterload may lead to myocardial dysfunction such as reduced contractility, dysrhythmias, reduction of the cardiac output and ultimately congestive heart failure. In one study, severity of atherosclerotic lesions could be correlated with cardiac hypertrophy and fibrosis.(Fricke et al. 2009)

Parrots also experience stroke events. An African grey parrot displayed chronic seizure activity for at least 4 years following an acute ischemic cerebral stroke diagnosed on MRI, but, while strongly suspected, atherosclerosis could not be confirmed ante-mortem in this patient.(Beaufrère et al. 2011) A hemorrhagic stroke and brain infarct, diagnosed on MRI and confirmed on histopathology, caused severe vestibular signs in a blue and gold macaw (*Ara ararauna*) and was concurrent with advanced atherosclerosis.(Grosset et al. 2012) Hemorrhagic strokes have also been reported in an Amazon parrot and in budgerigars but the presence of atherosclerosis could not be confirmed or was not mentioned.(Shivaprasad 1993; Jenkins 1991) In addition, carotid atherosclerosis was associated with seizures in an African grey parrot and an aura-like behavior with altered consciousness in an Amazon parrot.(Shivaprasad 1993; Johnson et al. 1992) A recent study showed an 8-time increase in odds for birds with atherosclerosis to present with neurologic signs but this association was not statistically significant.(Pilny et al. 2012)

A coronary aneurysm developed secondary to coronary atherosclerosis in an umbrella cockatoo (*Cacatua alba*). (Vink-Nooteboom et al. 1998) An aortic aneurysm with severe atherosclerosis was reported in an alexandrine parakeet (*Psittacula eupatria*). (Finlayson 1965) Aneurysms are suspected to form in atherosclerotic arteries because of their lower compliance than healthy elastic arteries leading to limited and constant expansion of the arterial wall over a range of distending pressures caused by the pulsatile cardiac output.(Smith et al. 2000)

Exercise intolerance and non-specific respiratory signs are also frequently reported but may be caused by impaired cardiac function secondary to atherosclerotic lesions.(Johnson et al. 1992; Fricke et al. 2009) Sudden death or non-specific clinical signs are generally acknowledged as the most common presentation of clinical atherosclerosis and may be partially explained by the relative inactivity of some captive parrots that allows severe subclinical atherosclerotic lesions to develop without detection of clinical manifestations by their caretakers.(Bavelaar & Beynen 2004a; StLeger 2007) Finally, sudden death from lethal cardiac arrhythmia triggered by myocardial ischemia or undetected cerebral emboli are possible.

iv. Diagnostic tests

Currently, atherosclerosis is difficult to diagnose antemortem in birds and there are severe limitations in knowledge and resolution of imaging equipment that seriously impair visualization of lesions, their ischemic consequences, and the identification of avian patients at increased risk.

The lack of characterized clinical pathology markers and risk factors in birds and the drastic changes in blood lipid and lipoproteins during the female reproductive cycle prevent the identification of susceptible birds and the implementation of risk factor-targeted management. While avian models of atherosclerosis consistently show an increased blood cholesterol and LDL, the dyslipidemia is artificially induced by high cholesterol feeding and it is unclear if similar dyslipidemic changes occur in patients with spontaneous atherosclerosis. As mentioned previously, in a case-control study on 31 parrots, a total cholesterol median twice as high as in control parrots was found in birds exhibiting atherosclerotic lesions.(Pilny et al. 2012) Also, C-reactive protein which is an acute-phase protein that has diagnostic and prognostic value in human coronary artery disease does not seem to be a major acute-phase protein in birds (Cray, written communication, April 2012).

Blood pressure measurements could be useful in psittacine patients to detect chronic hypertension, which is a risk factor for atherosclerosis in several species and a means to diagnose certain clinical entities such as intermittent claudication (e.g. ankle-brachial index). Unfortunately, indirect blood pressure measurements methods such the oscillometric and the Doppler probe techniques are not reliable in parrots and direct arterial blood pressure measurement is invasive and not clinically practical.(Acierno et al. 2008; Johnston et al. 2011)

Electrocardiographic changes have not been characterized with atherosclerosis but are expected to occur in some cases due to cardiac consequences and ischemia.

Diagnostic imaging seems promising to assess the avian cardiovascular system but there is a lack of standardization of vascular imaging protocols and the small size and fast heart rate of birds provide limitations to the resolution of vascular structures that can reasonably be achieved. Antemortem diagnosis of atherosclerosis is primarily obtained in advanced cases, with severe calcification of the arteries, or in association with congestive heart failure.(Mans & Brown 2007; Sedacca et al. 2009; Shrubsole-Cockwill et al. 2008) Atherosclerosis targets the major arteries in birds and, fortunately, these arteries are the most accessible to diagnostic imaging. The two brachiocephalic arteries, pulmonary arteries, and the ascending and abdominal aorta can be visualized on plain radiographs and with advanced imaging techniques.(Beaufre, Pariaut, et al. 2010) Smaller arteries such as the carotid arteries, visceral arteries, and branches of the brachiocephalic arteries can also be observed on CT-scan.

Several authors claim that enlargement and opacification of the arteries are detectable on plain radiographs and are suggestive of atherosclerotic changes.(Pees 2006) Considering the variability in X-ray exposure, the fast heart rate of birds, and arterial motion artefacts that are likely present on radiographs in addition to the subjectivity in interpreting such changes, it is doubtful that this approach would have any clinical accuracy.(Pees, Krautwald-Junghanns, et al. 2006; Simone-Freilicher 2007; Krautwald-junghanns et al. 2011) Severe atherosclerosis may also be present in the absence of vascular radiographic signs as documented in several case reports.(Beaufre, Holder, et al. 2011; Sedacca et al. 2009) Thus, radiographs should be considered an insensitive method of detecting vascular diseases.(Beaufre, Pariaut, et al. 2010) However, arterial calcification is fairly specific to advanced atherosclerotic lesions and can be detected on radiographs and CT-scan when severe.(Mans & Brown 2007; Krautwald-junghanns et al. 2011)

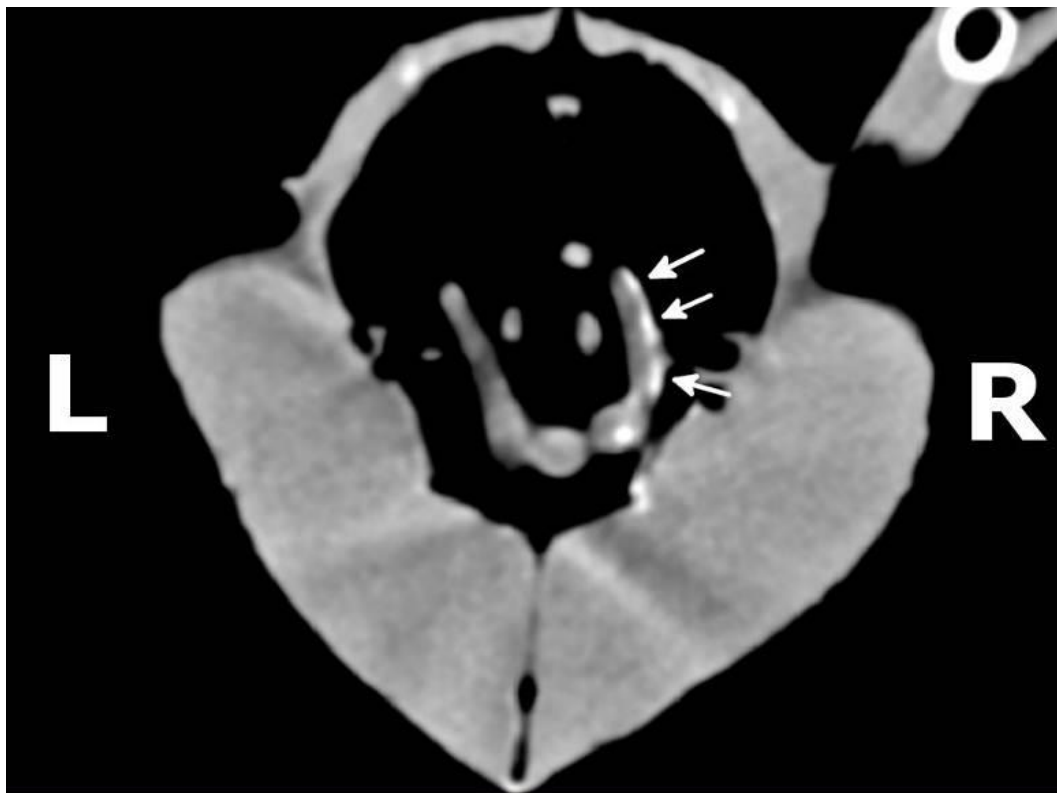


Figure 21: Computed tomography showing advanced aortic calcification of the ascending aorta in a female African grey parrot. Mediastinal window. Courtesy of Drs. Yvonne van Zeeland and Nico Shoemaker, Utrecht University, the Netherlands.

Since flow-limiting stenosis is the main mechanism leading to clinical signs in psittacine birds, angiography could be useful to assess arterial luminal narrowing. Angiographic procedures have also been described and can be expected to provide valuable information on arterial luminal patency but there is a lack of standardization and reproducibility of the techniques and measurements.(Krautwald-junghanns et al. 2011; Krautwald-junghanns et al. 2008; Beaufriere, Pariaut, et al. 2010) Angiography has successfully been used to diagnose coronary aneurysm in a single cockatoo.(Vink-Nooteboom et al. 1998) Digital subtraction angiography using fluoroscopy consists of subtracting precontrast images from contrast images to increase the outline of arteries in dense soft tissue and bone environment. This technique has been investigated in birds and may increase the diagnostic sensitivity of arterial luminal stenosis but has not been used in clinical cases.(Beaufriere, Pariaut, et al. 2010) Cardiac manifestations of atherosclerosis (e.g. congestive heart failure, valvular insufficiency) can be diagnosed with transcoelomic and transesophageal echocardiography but their association with atherosclerotic lesions cannot be made using these techniques.(Pees, Krautwald-Junghanns, et al. 2006; Beaufriere, Pariaut, et al. 2010) The aortic root can be imaged and measured by ultrasound, the outflow aortic velocity estimated using spectral Doppler, and reference intervals have been reported for aortic measurements.(Pees et al. 2004; Pees, Krautwald-Junghanns, et al. 2006; Straub et al. 2004) Furthermore, transesophageal echocardiography allows M-mode imaging of the aortic root.(Beaufriere, Pariaut, et al. 2010) Hyperechoic areas at the base of the aorta may

sometimes be seen on echocardiography.(Krautwald-junghanns et al. 2011) Likewise cerebral complications such as ischemic and hemorrhagic strokes can be diagnosed using CT-scan or MRI but concurrent atherosclerosis cannot be detected when calcification of the lesions is not severe.(Beaufrère et al. 2011; Grosset et al. 2012; Jenkins 1991) MRI was not a good diagnostic value for the vascular system in pigeons because of the rapid circulation of contrast media (gadolinium).(Romagnano et al. 1996) Organ perfusion imaging and radionucleotide-labelled atherosclerotic markers have not been investigated in psittacine birds. Finally, endoscopy using an interclavicular approach allows good and direct visualization of the base of the heart and the major arteries but is impaired by area fat stores in overweight birds and is more invasive.(Beaufrère, Pariaut, et al. 2010)

Therefore, the future of vascular imaging relies on the development and standardization of advanced imaging techniques and improvement in equipment resolution.(Beaufrère, Pariaut, et al. 2010) High quality angiographic techniques aiming to either diagnose arterial luminal stenosis or detect atheromatous plaques are likely to become the diagnostic tests of choice when limitations in resolution and motion artifacts are overcome.

v. Medical management and prevention

In the absence of well-characterized risk factors for prevention and pharmacologic information to be used for therapeutics, the medical management and preventative approach are largely empirical and based on information derived from human literature. While humans and parrots may share major lifestyle and dietary risk factors, psittacine birds may have specific risk factors that need to be explored for a more adapted approach. The treatment of atherosclerosis can be divided into the reduction of risk factors and the treatment of cardiovascular and ischemic consequences.

Lifestyle changes that could be implemented include increasing the physical activity of captive parrots by providing more opportunities for locomotion and foraging behaviors and decreasing the stress level in their captive environment. Parrots eat a cholesterol-free diet as cholesterol is an animal compound for which ergosterol is the vegetal equivalent. Therefore, animal products in the diet should be eliminated since they are a source of cholesterol and saturated fat. A well balanced plant-based diet is primordial. Supplementation with omega-3 fatty acids such as α -linolenic acid that can be found in flaxseed oil has been shown to be beneficial in improving lipid metabolism, minimizing inflammation, and minimizing atherosclerosis in several avian species.(Petzinger et al. 2010; Bavelaar & Beynen 2003; Bavelaar & Beynen 2004b) However, similar plasma lipid improvement than in mammals could not be documented in normal parrots but were not investigated in dyslipidemic parrots.(Petzinger 2012; Petzinger et al. 2011; Bavelaar et al. 2005) Limiting dietary excess and obesity in captive birds also appears to be a reasonable strategy but species-specific dietary needs should be considered. For instance, macaws and palm cockatoos need a much higher dietary fat content than other parrots.(Brightsmith et al. 2010)

Statins are employed in parrots but their use is controversial because no pharmacologic information is available and target levels of blood cholesterol and LDL that would reduce atherosclerosis risks are unknown in psittacine birds. Atorvastatin is the most commonly used statin and has a long half-life in humans (15-30 hours) but it undergoes extensive hepatic biotransformation and shows some pharmacologic interaction with itraconazole, an antifungal drug frequently used in psittacine birds.(Paoletti et al. 2005) On the other hand, rosuvastatin has a similar half-life, is not extensively metabolized by the liver and does not display problematic

pharmacologic interactions.(Paoletti et al. 2005; White 2002) Other statins (e.g. lovastatin, simvastatin, pravastatin) have short half-lives (1-4h). Therefore, if a statin is used empirically in pet birds, we would recommend choosing rosuvastatin for its pharmacologic properties that may be advantageous in avian patients.

Clinical signs of peripheral arterial disease have been treated with pentoxifylline or isoxsuprine in Amazon parrots.(Beaufrere, Holder, et al. 2011; Simone-Freilicher 2007) Despite the lack of evidence for efficacy in humans, isoxsuprine relieved signs of hindlimb weakness in an Amazon parrots but atherosclerotic disease was not confirmed.(Simone-Freilicher 2007; Hirsch et al. 2006) Likewise, the use of antihypertensive medications such as ACE-inhibitors and β -blockers are not yet applicable in birds when there is no accurate and repeatable means of measuring the arterial blood pressure in clinical cases for diagnosis and follow up. Antithrombotic agents have not been investigated in psittacine birds but atherothrombotic complications are rare. Medical management of congestive heart failure was described in a previous section.

D. Atherosclerosis in non-domestic avian species

Atherosclerosis has been described in almost all orders of birds.(Finlayson et al. 1962; StLeger 2007; Garner & Raymond 2003; Griner 1983; Bohorquez & C. Stout 1972) Three large retrospective studies reported the prevalence of atherosclerosis in multiple avian orders on 9949, 7689, and 919 birds, respectively (Table 23).(Garner & Raymond 2003; Griner 1983; Finlayson et al. 1962) Most lesions occurred in the major arteries as well as the carotid and coronary arteries. However, these prevalences should be interpreted with caution as it is likely that not all organs were reviewed in all cases when, for instance, biopsy cases were included in the calculation of the prevalence and methods and inclusion criteria were different. In addition, avian taxonomy is constantly changing and classifications used at the time may not directly relate to today's classification. For instance, prevalence reported in falconiformes actually included cases in the orders falconiformes and accipitriformes, cases belonging to coraciformes included cases from the orders of coraciformes and bucerotiformes, and struthioniformes only accounted for ostriches.

One report from the Oklahoma City Zoo documented a prevalence of 90% (65/72) of exotic birds with atherosclerosis with the most advanced lesions seen in galliformes and ciconiiformes.(Bohorquez & Stout 1972) A survey in captive birds of prey from England identified 5/66 diurnal birds of prey with atherosclerosis which was considered the cause of death in two Bonelli's eagle (*Aquila fasciata*). (Cooper & Pomerance 1982) A review of 57 penguin pathology records over 5 years at SeaWorld identified 25 birds with atherosclerosis which was the attributable cause of death in 4 of them.(StLeger 2007) In a large raptor collection in France in 2011-2012 (le parc du Puy du fou), a group of 80 black kites (*Milvus migrans*) experienced severe loss due to atherosclerosis of the great vessels that primarily manifested as acute deaths. (Facon & Beaufrère, in preparation)

Myocardial infarction in association with advanced atherosclerosis was diagnosed in several individuals including a bald eagle (*Haliaeetus leucocephalus*), two white-backed vultures (*Gyps africanus*), a Javan fishing owl (*Scotopelia* spp.), a concave-casqued hornbill (*Buceros bicornis*), three pelicans (*Pelecanus* spp.), a tawny frogmouth (*Podargus strigoides*) (arterial thrombus as well), and a Edward's pheasant (*Lophura edwardsi*). (Griner 1983; Finlayson et al. 1962; Finlayson 1965) Ischemic cardiomyopathy due to atherosclerosis was reported in a red-tailed hawk (*Buteo jamaicensis*). (Knafo et al. 2011)

Table 23: Prevalence of atherosclerosis in avian orders kept in zoological collections (methods, inclusion criteria, and population demographics varied substantially between reports, %: raw prevalence, N: total number of birds investigated)

Order	Garner 2003		Griner 1983		Finlayson 1962, 1965	
	N	%	N	%	N	%
Coraciformes	199	6.5	110	8.0	19	31
Struthioniformes	136	5.0	78	1.3		
Falconiformes	282	4.2	129	10.8	30	53
Piciformes	205	3.4	138	12.3	23	22
Strigiformes	136	2.9	87	1.1		
Ciconiformes	319	2.8	208	2.9	63	13
Psittaciformes	3678	2.6	1322	2.8	229	24
Galliformes	812	2.1	762	6.0	66	27
Gruiiformes	258	1.9	229	1.7	27	19
Phoenicopteriformes	275	1.8	56	3.6		
Columbiformes	305	1.6	186	12.4	28	9
Cuculiformes	64	1.5	64	0.0		
Anseriformes	1062	0.9	1047	3.1	131	19
Charadriiformes	249	0.8	256	1.6	40	12
Sphenisciformes	212	0.5	118	0.8	36	0
Passeriformes	1495	0.1	1300	2.4	168	7
Coliiformes	50	0.0	22	0.0		
Pelecaniformes	60	0.0	113	2.6		
Apodiiformes	20	0.0	198	0.0		
Procellariiformes	6	0.0	43	0.0		
Gaviiformes	65	0.0	22	0.0		
Caprimulgiformes	15	0.0	1	100.0		
Unknown	46	2.0			59	19
Total	9949	2.1	7689	3.0	919	21

Ruptured aortic aneurysm due to atherosclerosis has been diagnosed at least in a Sclater's crowned pigeon (*Goura scheepmakeri*), an Egyptian plover (*Pluvianus aegyptius*), a grey-winged trumpeter (*Psophia crepitans*), a crowned hawk-eagle (*Stephanoaetus coronatus*), and a maned goose (*Chenonetta jubata*). (Griner 1983; Finlayson 1965) A ruptured aortic aneurysm with advanced atherosclerosis was the cause of death in a flamingo (*Phoenicopterus* spp.) (Garner, written communication, May 2012). Likewise, several cases of aortic ruptures with atherosclerosis were reported in Antarctic penguins. (StLeger 2003) Most cases of dissecting aortic aneurysms in ostriches and turkeys are not due to atherosclerosis but are associated with copper deficiencies. (Mitchinson & Keymer 1977; Vanhooser et al. 1994; Ferreras et al. 2001; Baptiste et al. 1997; Gresham & Howard 1961)

Atherosclerosis is also diagnosed with some frequency in wild birds. Of 97 free-living birds examined in the United Kingdom and East Africa, 32 had evidence of atherosclerotic lesions and 4 had evidence of advanced aortic lesions. (Finlayson 1965) An investigation on 157 wild male turkeys collected by hunters in the United States found atherosclerosis in 49.5% of arteries

evaluated with the greatest prevalence of lesions found in the ischiatic artery and aorta.(Krista & McQuire 1988) A report from Iraq found 10% of a sample of 100 free-living pigeons with atherosclerotic lesions.(Al-Sadi & Abdullah 2011) A retrospective survey from Northern California found 6/409 free-living raptors with atherosclerosis, a frequency which is lower than usually reported in captivity for these species.(Morishita et al. 1998) In addition, atherosclerotic lesions were also found in a population of free-living Egyptian vultures (*Neophron percnopterus*). (Grünberg & Kaiser 1966)

While much emphasis has been placed on psittacine atherosclerosis, it is also evident that atherosclerosis is a major problem of other avian orders commonly seen by veterinarians, especially falconiformes and accipitriformes.(Cooper & Pomerance 1982; Finlayson 1965; Griner 1983; Garner & Raymond 2003) Some authors mention that atherosclerosis is uncommon in carnivorous animals, but this does not seem to hold in Aves as birds of prey showed a significant prevalence of lesions in captivity. Risk factors for atherosclerosis in non-psittacine species are speculative and epidemiologically unknown. The common practice of feeding day-old chicks which have a large yolk sac rich in cholesterol may potentiate atherosclerosis in susceptible raptorial species (e.g. insectivorous raptors, falcons). For instance, in a large retrospective study in humans, consumption of egg yolk was strongly associated with an increased atherosclerotic burden in the carotid arteries.(Spence et al. 2012)

CHAPTER I: CHARACTERIZATION AND CLASSIFICATION OF PSITTACINE ATHEROSCLEROTIC LESIONS BY HISTOPATHOLOGY, DIGITAL IMAGE ANALYSIS, TRANSMISSION AND SCANNING ELECTRON MICROSCOPY*

I. Introduction

Atherosclerosis is one of the leading causes of human deaths in the world and its pathologic complications underlie coronary heart disease, stroke, and peripheral arterial disease.(Mathers et al. 2004) Likewise, atherosclerosis is common in psittacine birds with the great vessels at the base of the heart being affected most often. The prevalence of atherosclerosis in psittacines, reported from post-mortem surveys, ranges from 2.6 to 91.8% depending on the geographical areas, the time span of the study, the species, and the inclusion criteria.(Bavelaar & Beynen 2004a; Fricke et al. 2009; Garner & Raymond 2003; Krautwald-Junghanns et al. 2004) Prevalences by age groups are unknown but the prevalence and severity of the lesions appear increased in older psittacine birds.(Bavelaar & Beynen 2004a; Fricke et al. 2009) All psittacine species appear susceptible but the disease is most frequently reported in Amazon parrots (*Amazona* spp.), African grey parrots (*Psittacus erithacus*), macaws (*Ara* spp.), cockatoos (*Cacatua* spp.) and cockatiels (*Nymphicus hollandicus*).(Bavelaar & Beynen 2004a; Fricke et al. 2009; Garner & Raymond 2003; Johnson et al. 1992; Krautwald-Junghanns et al. 2004; Pilny 2004; Schenker & Hoop 2007; StLeger 2007) Avian models, such as pigeons, Japanese quails, turkeys, and chickens, are an integral and important part of the research conducted on atherosclerosis and these models significantly contributed to the understanding of many aspects of the disease.(Moghadasian 2002; St Clair 1998) Moreover, pigeons are considered one of the best models for studying human atherosclerosis.(Moghadasian 2002; Moghadasian et al. 2001; St Clair 1998) Despite the high incidence of atherosclerosis in parrots and the high number of clinical case reports,(Beaufreere, Holder, et al. 2011; Johnson et al. 1992; Mans & Brown 2007; Pees, Schmidt, et al. 2006; Pees et al. 2001; Phalen et al. 1996; Pilny 2004; Sedacca et al. 2009; Simone-Freilicher 2007; Vink-Nooteboom et al. 1998) there are few pathologic investigations on the lesions in this group of birds.(Bavelaar & Beynen 2003; Fricke et al. 2009; Schenker & Hoop 2007) Detailed pathological description and categorization of atherosclerotic lesions, as can be found in the human literature and in reports from the Council on Arteriosclerosis of the American Heart Association (AHA),(Nakamura & Ohtsubo 1992; Stary 2000; Stary 2003c; Stary et al. 1992; Stary et al. 1995; Stary et al. 1994; Virmani et al. 2000) are a prerequisite to understanding the pathogenesis of psittacine atherosclerosis and its clinical impact, designing further experiments, and comparing the disease with other avian and mammalian species.

Atherosclerosis is a degenerative and inflammatory vascular disease characterized in mammals and birds by the accumulation of inflammatory cells, lipids, lipoproteins, calcium, and

* This chapter originally appeared as Beaufreere, H., et al., 2011. Characterization and classification of psittacine atherosclerotic lesions by histopathology, digital image analysis, transmission and scanning electron microscopy. *Avian Pathol*, 40(5), pp.531–544. Reprinted with permission of Avian Pathology, Taylor & Francis

formation of large fibrofatty lesions in the intima resulting in the disorganization of the arterial wall, stenosis of the lumen, and potentially leading to thrombotic complications.(Cullen et al. 2005; George & Lyon 2010; St Clair 1998; Stary et al. 1995; Stary et al. 1994) Atherosclerotic lesions are initiated by endothelial dysfunction associated with a variety of risk factors such as smoking, dyslipidemia, diabetes mellitus, hypertension, aging, obesity, sex, genetic factors, chronic systemic infections, lifestyle, hyperhomocysteinemia, and dietary factors.(Cullen et al. 2005; vonEckardstein 2005; George & Lyon 2010; McGill & McMahan 2005) Endothelial dysfunction causes increased endothelial permeability to lipoproteins and adhesion and recruitment of leukocytes, which set the stage for atherogenesis. In humans, the characteristics and composition of atherosclerotic lesions have been investigated by histopathology,(Stary 2000; Stary 2003c; C. Stary et al. 1995; Stary et al. 1994; Virmani et al. 2000) immunohistochemistry,(Katsuda et al. 1992; Stary et al. 1995; Stary et al. 1994) transmission electron microscopy,(Balakrishnan et al. 2007; Bocan & Guyton 1986; Nakamura & Ohtsubo 1992; Pasquinelli et al. 1989) scanning electron microscopy,(Congiu et al. 2010; Kamari et al. 2008; Walski et al. 2002) proteomics,(Duran et al. 2002) digital image analysis,(Dilley 2001; Taatjes et al. 2000) and isolation and purification of their different biochemical compounds.(Papakonstantinou et al. 2001) In birds, particularly the pigeon, similar pathological and ultrastructural studies have been performed and lead to similar findings.(Barr et al. 1991; Casale et al. 1992; Hansen 1977; Jerome & Lewis 1985; Lauper et al. 1975; Stout & Thorpe 1980) Recent studies have evaluated the characteristics of psittacine atherosclerosis using histopathology and immunohistochemistry.(Bavelaar & Beynen 2003; Fricke et al. 2009; Krautwald-Junghanns et al. 2004; Schenker & Hoop 2007) However, there are some limitations to light microscopy alone in describing atherosclerotic lesions such as difficulties in characterizing cell types, describing the fine structure of the atherosclerotic plaques, and quantifying the lesion composition. Furthermore immunohistochemistry in parrots suffers from the lack of sensitivity and standardization of protocols for the different species of interest. Finally, some details of atherosclerotic lesions may not be appreciated on conventional 5 µm thick histological sections.(Stary 2003a; Stary et al. 1992; Stary et al. 1995; Stary et al. 1994)

Lesion classification systems that reflect the progression of the lesions, the pathways of development, and their clinical significance have been described in humans and in other mammalian and avian species.(Santerre et al. 1972; Stary 2005; Virmani et al. 2000) The human classification of atherosclerotic lesions published by the AHA defines eight types of lesions based on histopathologic, ultrastructural, and biochemical criteria.(Stary 2003a; Stary 2005; Stary et al. 1995; Stary et al. 1994) Type I-III constitutes early atherosclerotic changes. Both type I and II are characterized by minimal lipid deposits in the tunica intima with macrophage foam cells accumulated in layers in type II lesions.(Stary et al. 1994) Type III lesions (preatheroma) are intermediate between early stages (type I-II) and advanced lesions (type IV-VI) and contain histologically visible extracellular lipid deposits and cellular debris from foam cells.(Stary et al. 1994) Advanced lesions type IV-VIII are associated with intimal disorganization and thickening and may produce clinical symptoms. In type IV lesions, extracellular lipids and debris converge to form a well-delineated lipid core that contains calcium granules and is defined as an atheroma.(Stary et al. 1995) The increase presence of fibromuscular tissue and calcium characterizes type V lesions. Type VI lesions are lesions complicated by disruption of the surface, hemorrhage, or thrombosis. Finally, type VII (calcific lesion) and VIII (fibrotic lesion) are regarded as specific lesions that result from regression, repair, or changes in lipid composition.(Stary et al. 1995) In birds, atherosclerotic lesion investigations have primarily

utilized pigeons and quails with the progression of arterial lesion development being very similar to atherosclerosis in humans with the presence of fibromuscular tissue, macrophage foam cells, extracellular lipids, smooth muscles cells, and complications in advanced stages such as thrombosis and mineral deposition.(Jerome & Lewis 1997; Moghadasian 2002; Santerre et al. 1972; Shih et al. 1983; St Clair 1998) Histopathologic classifications have been used in studies in pigeons, quails, chickens, and parrots, sometimes with very specific objectives thereby allowing this criteria to serve the study design.(Fricke et al. 2009; He et al. 2005; Orita et al. 1994; Santerre et al. 1972; Siegel et al. 1995) Nevertheless, these findings propose that the progression and the stages of the lesions are similar to humans with a few species variation. A staging system has recently been suggested in parrot species in two studies and seems to bear fundamental differences with other classifications in lesion description and interpretation.(Fricke et al. 2009; Schenker & Hoop 2007) The staging system developed in these two studies was very similar. Stage 1 was characterized by the fragmentation of elastic layers and increased extracellular matrix in the media, stage 2 by fat deposition in the intima and media, stage 3 by an increased presence of collagen fibers or the further development of the atherosclerotic plaque, and stage 4 by a fibrous appearance of the plaque with more calcification.(Fricke et al. 2009; Schenker & Hoop 2007) This classification also suggests that the different stages are successive steps in the development of the psittacine atherosclerotic lesion.

The objectives of our study were to further describe and quantify the microstructure and ultrastructure of psittacine atherosclerotic lesions and characterize their cellular and extracellular components. Our goals were also to propose a classification system that would adequately reflect the lesion composition, progression, pathophysiology, and current atherogenesis theories. Our hypothesis was that atherosclerosis in parrots showed similarities in composition and progression with the lesions present in humans and other avian species.

II. Materials and Methods

A. Sample collection

Arteries were collected from psittacine birds submitted for necropsy to the Louisiana State University School of Veterinary Medicine (LSU-SVM). A full necropsy was performed and the brachiocephalic arteries, ascending aorta, and pulmonary arteries were harvested from each bird when possible. Sections from the major arteries were fixed in 10% neutral formalin for histopathology processing. Additional sections were fixed in 2% paraformaldehyde and 1.25% glutaraldehyde in a 0.1 M sodium cacodylate buffer, with a pH of 7.3 and stored at 4°C for transmission and scanning electron microscopy evaluation.

A total of 24 birds were collected: 5 African grey parrots (*Psittacus erithacus*), 3 yellow-naped Amazon parrots (*Amazona ochrocephala auropalliata*), 1 double-yellow-headed Amazon parrot (*Amazona ochrocephala oratrix*), 5 blue and gold macaws (*Ara ararauna*), 1 red-fronted macaw (*Ara rubrogenys*), 3 cockatiels (*Nymphicus hollandicus*), 1 budgerigar (*Melopsittacus undulatus*), 1 Goffin's cockatoo (*Cacatua goffini*), 1 sun conure (*Aratinga solstitialis*), 1 green cheeked conure (*Pyrrhura molinae*), 1 white-bellied caique (*Pionites leucogaster*), and 1 Quaker parrot (*Myiopsitta monachus*). Ages ranged from 10 weeks to 48 years.

B. Histopathology

Formalin-fixed tissues were routinely processed into paraffin. Five micrometer sections were cut and stained by hematoxylin and eosin (H&E), von Kossa for calcium salts, and Verhoeff von Gieson for elastin fibers. Masson's trichrome staining was also performed on a selected section

for staining connective tissue. To reveal lipid, frozen formalin-fixed specimens were sectioned at five micrometer thickness and stained with oil red O. In addition, 0.5 micrometer thick sections obtained from the blocks used for transmission electron microscopy sections, as described below, were stained with toluidine blue.

Immunohistochemistry (IHC) for CD68 (anti-human macrophages), anti-human myeloid/histiocyte antigen, and anti-human lysozyme (all from DakoCytomation, Carpinteria, CA) was attempted for psittacine macrophages using a parrot granuloma as a positive control. The IHC for smooth muscle actin (DakoCytomation, Carpinteria, CA) was also performed on a selected artery.

C. Digital image analysis

All slides were digitized using a slide scanner (NanoZoomer 2.0-HT Digital Pathology System (NDP), Hamamatsu, Bridgewater, NJ, USA). The NDP can achieve a resolution of 0.23 microns per pixel using time-delay-and-integration charge-coupled technology. Slides were acquired and processed using the manufacturer software (NanoZoomer Digital Pathology suite, NDP.scan U10074-01 and NDP.view 1.1.27, Hamamatsu, Bridgewater, NJ, USA). Slides were scanned at 40X using the semi-automatic and brightfield modes. Scanning time varied between 10 to 40 minutes per slide. Histopathology slides were then evaluated and the atherosclerotic lesions were characterized.

For image processing, slides with appropriate cross-sectioning and staining quality were selected. Images of areas of interest from each slide were exported at 10X in tagged image file format (TIFF) in 24-bit RGB colors. TIFF was selected for its ability to store image data in a lossless format.

Digital image analysis was performed using the public domain NIH software ImageJ.(Rasband, 1997-2010) To improve visualization of the images, all images were initially standardized to account for variation in staining quality, brightness, and uneven background using the background correction plugin of the software (Figure 22.A-B).

For morphometric analysis, region of interests (ROI) were selected manually under 10X magnification (arterial wall, lumen, atherosclerotic lesion) using the freehand, polygon, and wand selection tools. The adventitia was not included in ROIs. Selections were saved in the ROI manager module of the software. Areas of selected ROIs were measured using the measurement analyzing tool and the atherosclerotic percentage area was subsequently determined. The degree of stenosis and the ratio arterial wall/lumen were not calculated as such measurements would be inaccurate in arteries not fixed under physiological pressure.

For staining quantification (Figure 22), color stains were first separated from the images using the plugin ‘Colour Deconvolution’ based on the color deconvolution method described by Ruifrok *et al.*(Ruifrok et al, 2001) The plugin returns three 8-bit images for the three different colors of a histochemical preparation. If the specimen is stained with only 2 colors, the third image represents the complimentary image of the first two. Stains discrimination was based on pre-set stain vectors. The stain vectors were determined for von Kossa (staining calcium), Verhoeff von Gieson (staining elastin), and oil red O (staining lipid) using single stain preparations of control slides processed, stained, and digitized using the same methods and the same laboratory. Histologic sections of canine calcinosis cutis, penguin’s epicardial fat, and psittacine arteries were used as positive controls respectively. The single stain images of the arteries obtained were then used to delineate and measure the area containing the target compound (calcium, lipid, and extracellular matrix) using thresholding segmentation and area

analyses. As with the stain vectors, threshold levels for each stain that best discriminated the stained target compound from surrounding counterstained tissues were determined on controlled slides and advanced atherosclerotic lesions. These levels were then set in the software and subsequently kept the same for all arterial images. Thresholding segmentation returns binarised images (pixels are either white or black). Previously determined ROIs were then recovered from the ROI manager module and applied on each of the segmented images. Percentage areas of the stains were then measured using the measurement analyzing tool which gives the percentage of black pixels in the selected areas. The image analysis protocol was slightly modified for Verhoeff van Gieson stained slides as the areas of interest that would approximately represent the extracellular matrix in the media would be the unstained and counterstained areas of the media. The atherosclerotic lesion ROI was subtracted from the arterial wall ROI and the percentage areas of extracellular matrix (percentage of white pixels) in the media was then measured on the thresholded single stain images.

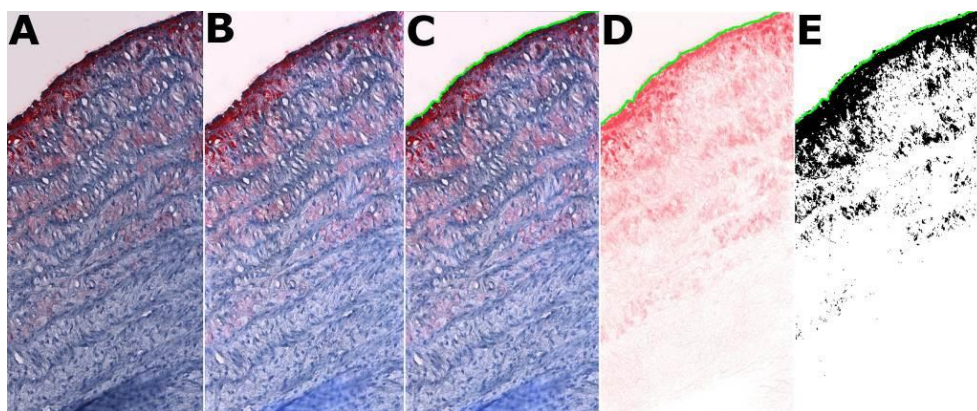


Figure 22: Digital image analysis process on a portion of a cross section of the ascending aorta of an Amazon parrot stained with oil red O and performed with ImageJ. **A.** Acquisition of the image, **B.** Standardization of the background, **C.** ROI is traced around the artery (green line). **D.** Separation of the lipids stained with oil red by color deconvolution. **E.** thresholding segmentation and binarization of D. Oil Red O, X 10.

D. Transmission and scanning electron microscopy

Selected arterial tissues fixed for electron microscopy were processed, sectioned and stained using standard techniques. For TEM, materials were fixed in 2% paraformaldehyde and 1.25% glutaraldehyde in a 0.1M sodium cacodylate buffer, then rinsed five times in 0.1M cacodylate buffer containing 0.02M glycine over 12 hr period. Samples were post-fixed in 2% osmium tetroxide for 1 hour, rinsed in water, en bloc stained in 0.5% uranyl acetate in the dark for 1 hour, rinsed in water twice, dehydrated in ethanol series, infiltrated in ethanol with LR White resin series for 12 hours periods, and embedded in LR White overnight at 60 °C. Sections with 0.5 micrometer thickness were cut with a Dupont Sorvall MT-2 microtome and stained with 0.5% toluidine blue O (TBO) in 2% sodium borate. The slides were examined and samples selected for ultra-thin sections (70 nm thickness) for TEM study were sectioned using the same microtome. Transmission electron microscopic sections were mounted on collodion-coated copper grids, stained with Reynolds lead citrate, and imaged with a JEM-1011 Transmission Electron Microscope (JEOL, Tokyo, Japan). For SEM, materials were fixed, rinsed and dehydrated as described above. Then the half mount of the materials were critical point dried with liquid CO₂

in a Denton CPD, mounted on aluminum SEM stubs, coated with gold/palladium 60/40 in an Edwards S150 sputter coater, and imaged with a Quanta 200 Scanning Electron Microscope (FEI, Hillsboro, OR, USA).

Based on the assessment of the thin sections, 17 birds were selected for electron microscopic evaluation representing a total of 43 arteries for TEM and 35 for scanning electron microscopy (SEM).

E. Classification of atherosclerotic lesions

All sections were evaluated by light microscopy and a classification system was established to evaluate the arterial pathology. The appropriateness of the AHA classification system for human atherosclerotic lesions (Stary, 2000, Stary, *et al.*, 1995, Stary, *et al.*, 1994) was evaluated for these psittacine lesions as it was the most comprehensive and detailed classification system described for atherosclerotic lesions and encompassed information obtained from clinical signs, histopathology, image analysis, electron microscopy, biochemical analysis, and animal experiments. Lesions were also compared to classification systems proposed for parrots, pigeons, quails, and chickens.(Fricke, *et al.*, 2009, He, *et al.*, 2005, Orita, *et al.*, 1994, Santerre, *et al.*, 1972, Siegel, *et al.*, 1995) Digital image analysis, and transmission and scanning electron microscopy were used to further describe the lesion types and refine the classification system.

F. Statistical Analysis

Descriptive summary statistics were performed on the lesion types and digital image analysis measurements. Normality was assessed using quantile plots and Shapiro-Wilk tests. Due to the apparent non normality of the data distribution and the small number of arteries in some categories, results were reported as median and range. Spearman rank correlation coefficients were also computed between age, type of lesions, percentage areas of the lesions, lipid, calcium, and extracellular matrix. Data were analyzed using SAS (SAS 9.1.3, SAS Institute Inc., Cary, NC, USA). Correlation was considered significant for $p < 0.05$.

III. Results

A total of 63 arteries were collected (24 brachiocephalic trunks, 23 ascending aortas, and 16 pulmonary arteries). Some of the arteries did not have the required cross-sectioning and staining quality (complete circle of artery) for digital image analysis evaluation (n reported in Table 23). Antibodies tested (CD68, myeloid/histiocyte antigen, and lysozyme) did not cross-react with psittacine macrophages therefore the use of IHC for identifying macrophages was removed from the study. The IHC for smooth muscle actin revealed intimal smooth muscle cells (SMCs) in an examined section. The American Heart Association classification of atherosclerotic lesions was found to appropriately reflect the different types of lesions identified in our sample of parrots and the course of cellular and extracellular events observed on electron microscopy and was then adapted for the classification of psittacine atherosclerotic lesions. Arteries were not fixed under physiological pressure which, sometimes, made the interpretation of the anatomy of the intima and luminal side of the media on contracted arteries difficult. Intimal changes representing minimal atherosclerosis were more accurately identified on light microscopy of sections of 0.5 micrometer thickness stained with toluidine blue. Based on the 0.5 micrometer-thick sections, 43 arteries (16 brachiocephalic trunks, 16 ascending aortas, and 11 pulmonary arteries) with different lesion types were selected for TEM and 35 for SEM evaluation. Mild degrees of autolysis not visible on light microscopy could be seen at the ultrastructural level. These

autolytic changes included mitochondrial swelling and degeneration in most cells, disruption of cell-to-cell contact, and the presence of various degrees of vacuolation, cytoplasmic edema, plasmalemmal disruption, and myelin figures in endothelial cells and, less commonly, in SMCs and macrophages. Some ultrastructural autolytic changes and some features of cellular degeneration induced by atherosclerosis were difficult to distinguish in several cases. It should be noted that mitochondria and endothelial cells are known to deteriorate extremely rapidly after death.(Cheville 1994a; Stary et al. 1992)

The different lesion types with their morphologic, histochemical, and ultrastructural characteristics are described below, summarized in Table 24 and presented in Figure 23. Moderate to advanced lesions were mainly identified in the aorta and brachiocephalic trunks while the pulmonary arteries often exhibited mild lesions (15 type I and one type VII).

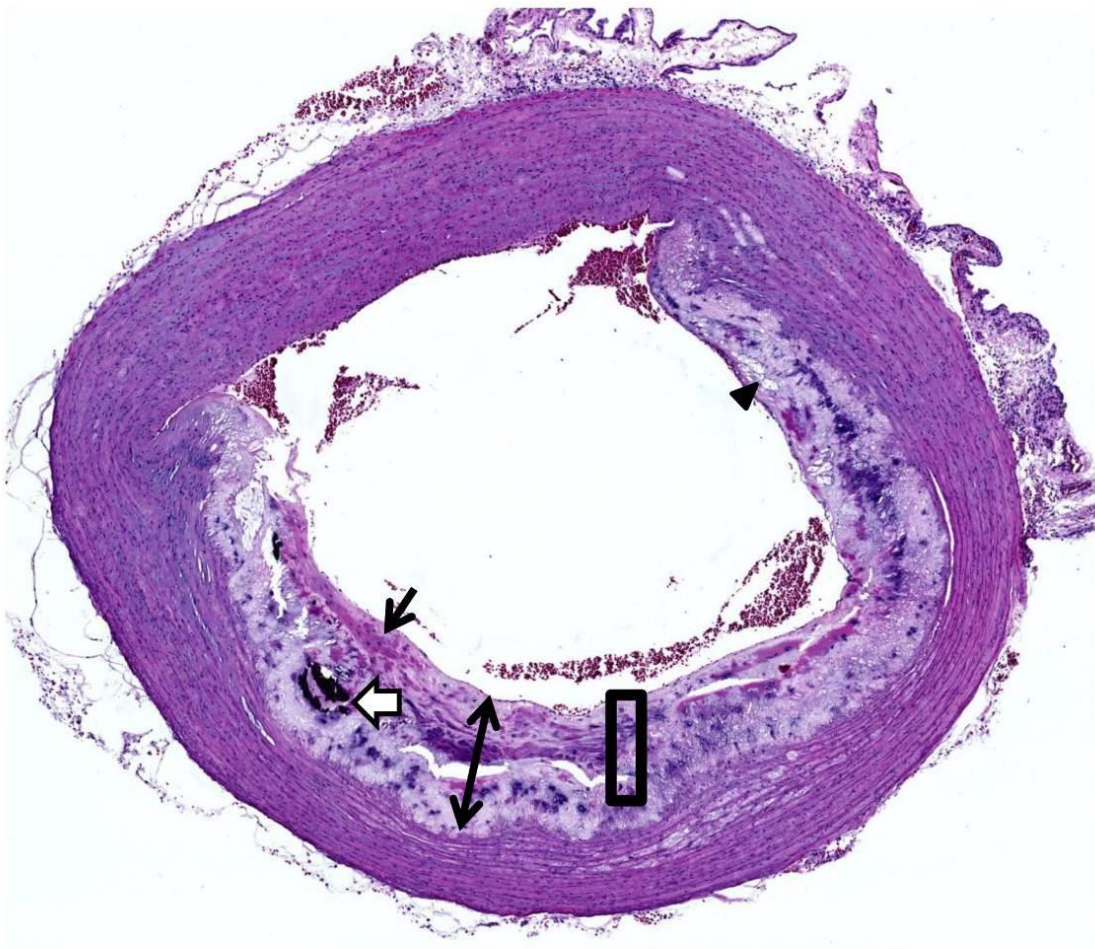
Digital image analysis results are reported in Table 25. The digital analysis of the extracellular matrix was not considered reliable as there was a great variability in the morphometry of the elastic laminae between arteries and the different sizes of arteries. Therefore, it was not included in statistical calculation. There was a low correlation between age of the bird and type of lesions ($\rho=0.38$, $p=0.03$), lesion cross-sectional area ($\rho=0.47$, $p<0.01$), percentage of lipid ($\rho=0.37$, $p<0.01$) and calcium ($\rho=0.4$, $p<0.01$). There was a high correlation between type of lesions and lesion cross-sectional area ($\rho=0.9$, $p<0.01$), percentage of lipid ($\rho=0.96$, $p<0.01$), and calcium ($\rho=0.76$, $p<0.01$).

Table 24: Classification of Psittacine Atherosclerotic Lesions (See also Figure 23)

Lesion Type	Description
Type I	Increased presence of macrophages and isolated foam cells, increased extracellular matrix in the intima, vacuolation of endothelial cells, presence of lipid in the intima, presence of RER-rich SMC.
Type II	Accumulation of macrophages and SMC foam cells in sheets, small pool of extracellular lipid.
Type III	Preatheroma: increased extracellular lipid and cell remnant forming confluent lipid areas, presence of calcium granules, mild disruption of arterial architecture.
Type IV	Atheroma: large lipid area forming a lipid core, disruption of the arterial wall architecture, atheromatous plaque bulging into the lumen, increased presence of calcium, endothelial surface defects.
Type V	Fibroatheroma: increased presence of fibromuscular tissue forming a fibrous cap over the lipid core. Mild to moderate plaque calcification. Significant luminal stenosis and endothelial surface defects.
Type VI	Complicated lesions: same as type IV, V but with hematoma or fissure.
Type VII	Calcific lesions, osseous metaplasia, large calcium plaques.

Figure 23: Atherosclerotic lesions in arteries of psittacine birds. **A.** A cross section of an artery showing Type V atherosclerotic changes. Expanding tunica intima consistent with a fibroatheroma (double-head arrows), composed of a fibrous cap (arrow) and underlying lipid core containing extracellular lipid (arrowhead), calcium deposits (open arrow), and extracellular matrix. A square showing a representative area in B. Aorta. Hematoxylin and eosin. **B.** Classification of psittacine atherosclerotic lesions described in Table 1 with normal artery (0), early lesions (I and II), intermediate lesions (III), advanced lesions (IV and V), complicated lesions (VI), and calcific lesions (VII). Hematoxylin and eosin.

A



B

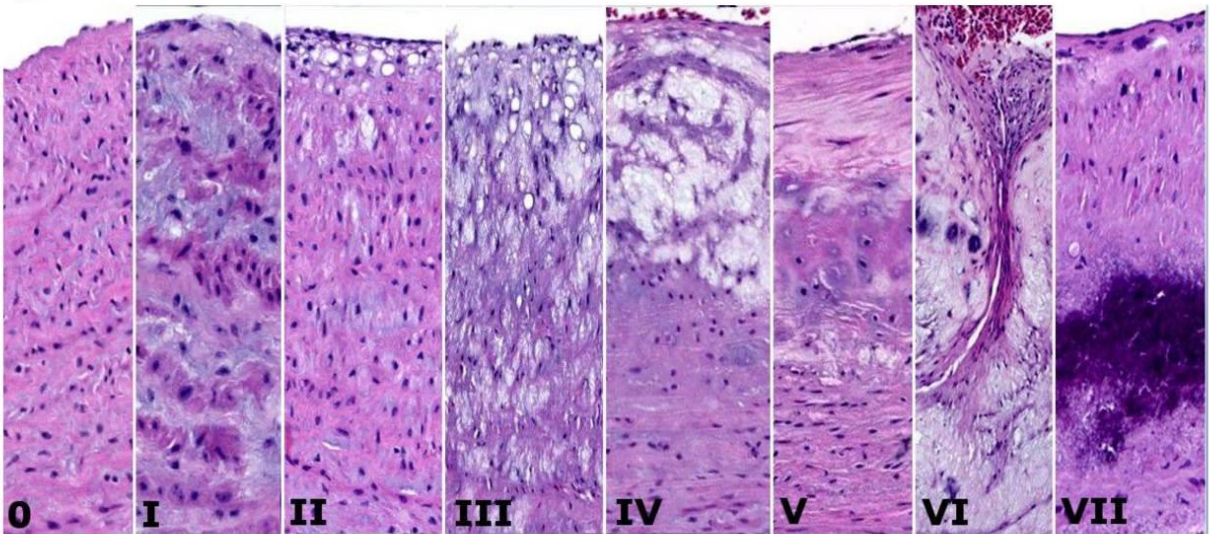


Table 25: Percentage areas obtained by digital image analysis of cross sections of psittacine major arteries

Lesion Type	Lesion			Lipid			Calcium		
	n	median	range	n	median	range	n	median	range
Normal	26	NA	NA	26	NA	NA	26	NA	NA
I	8	0.0	0.0-3.8	6	0.7	0.1-2.5	10	0.0	0.0-0.0
II	4	3.3	0.1-10.2	4	4.2	2.8-10.6	4	0.0	0.0-0.1
III	6	11.2	2.2-21.3	6	7.1	1.9-11.2	6	0.0	0.0-0.1
IV	5	17.6	8.7-45.8	5	11.0	6.8-14.7	5	1.5	0.0-4.9
V	4	44.8	33.8-50.5	4	14.4	9.0-17.0	4	5.4	1.8-7.3
VI	1	31.6	NA	2	30.65	29.5-31.8	1	1.8	NA
VII	3	11.7	4.7-33.8	1	3.2	NA	3	7.2	1.5-8.3

A. The normal intima and arterial wall

No evidence of an atherosclerotic lesion was observed in 28 arteries (44%). The intima was composed of a single layer of flattened elongated endothelial cells. The media was composed of concentric lamellae of elastic fibers and spindle-shaped SMCs embedded in a ground substance composed of collagen, elastic fibers, and extracellular matrix (Figure 24.E). A well-delineated internal elastic lamina, which denotes the border between the intima and the luminal side of the media and is considered part of the media, (H. C. Sary et al. 1992; L. C. Stout & Thorpe 1980) was identified in several birds on Verhoeff van Gieson stain. No lipid or calcium deposits were noted within the intima and media on the histological sections with H&E and histochemical stains (Table 25).

As observed through TEM, endothelial cells measured about 2-4 μm at the level of the nucleus and about 0.1-1 μm at the peripheral cytoplasm (Figure 25.A). The endothelial cells had a limited number of organelles; free ribosome, rough endoplasmic reticulum (RER), mitochondria, and Golgi complexes were rarely noted. Microfilaments measuring 5-7 nm were abundant as well as plasmalemmal vesicles in the cytoplasm and at the luminal side of the cell membrane (caveolae). Weibel-palate bodies were not observed. Microvilli were an infrequent finding on the luminal side of the cellular membrane. A thin basal lamina was present in most instances (Figure 25.A). The subendothelial space was limited to absent and the endothelium in most cases was directly apposed to the media. Occasionally, isolated macrophages, identified by the presence of a round to irregular shaped nucleus, pseudopodal projections, and frequent electron-dense lysosomes, were found in the normal intima. The internal elastic lamina was observed in several birds. In the media, SMCs measured approximately 2-4 μm in diameter and frequently had an undulated nucleus, evidence of their contracted state (Figure 25.A). The SMCs contained an abundant amount of myofilaments of 6-7 nm associated with electron-dense bodies in the sarcoplasm and dense plaques on the inner side of the sarcolemma. Other organelles identified included a few mitochondria preferentially located at the nuclear poles but also found elsewhere in the sarcoplasm, uncommonly RERs, and, regularly, plasmalemmal vesicles and free ribosomes. Smooth muscles cells were connected to each other via various junctional patterns and also appeared anchored on the elastic fibers. A basal lamina was usually not observed on normal SMCs. Ultrastructurally, lipid and calcium deposits were not observed. The endothelium visualized with SEM was relatively smooth and was characterized by well-junctioned elongated

endothelial cells that were orientated in the direction of the blood flow (Figure 26.A). There was an inability to adequately characterize endothelial microvilli most likely due to autolytic changes. On cross-sections, the concentric elastic lamellae were well visualized underneath the endothelial layer (Figure 26.B).

B. Type I lesions

Ten arteries (16%) exhibited changes classified as type I lesions which represent the first evidence of the presence of lipid deposits in the arterial intima and luminal side of the media and, by definition, the first evidence of atherosclerosis. These lesions were difficult to identify without the evaluation of toluidine-stained 0.5 micrometer-thick sections and TEM.

On light microscopy, initial changes were characterized by increased vacuolation of endothelial cells, increased thickness of the intima in some cases as also evidenced through Verhoeff van Gieson stain, mild to moderate fragmentation of elastic fibers, and the first detectable presence of foam cells (Figure 24.A). The increased thickness of the intima was mainly characterized by an increase presence of extracellular matrix and collagen fibers. Macrophages were more numerous, generally isolated and rarely in groups of more than a few cells. Extracellular lipid was not present and the extent of the lesions was minimal with no plaque formation. Extracellular matrix was increased in the luminal side of the media. Mild and scattered positive staining was observed on oil red O stain (Figure 24.B) but no calcium deposits were detected (Table 25).

Ultrastructurally, endothelial cells had an increased numbers of caveolae and appeared more vacuolated (Figure 25.F). As on light microscopy, TEM revealed an increased presence of macrophages in the intima. They frequently contained lipid droplets of approximate 0.5-4 μm diameter. In the intima and luminal side of the media, while most SMCs appeared normal, a varying number of SMCs contained lipid droplets and an increased presence of smooth and rough endoplasmic reticulum and plasmalemmal vesicles (Figure 25.C). A basal lamina was not observed around the SMCs. Extracellular lipid was rare. Overall, when evaluated using the SEM, endothelial architecture did not appear disrupted and was similar to normal endothelium.

C. Type II lesions

Type II lesions, observed in 4 arteries (6%), included the same changes as describe with type I lesions but there was an increased number of foam cells arranged in groups and/or layers (Figure 24.C) and the atherosclerotic lesions occupied a significant portion of the arterial wall (Table 25). Foam cells were also found deeper into the media. Additionally, extracellular lipid droplets were present in moderate quantity. A larger quantity of lipid (Table 25), as visualized by oil red O staining, was present along the endothelium and the luminal side of the media (Figure 24.D). No calcium deposition was detected in these arteries.

The foam cells were also visualized and characterized on TEM. Some cellular fragments and myelin figures were also noted. As the intracellular lipid accumulation and the presence of foam cells increased in the arterial wall, it became more challenging to differentiate macrophage-derived from SMC-derived foam cells. However, the increased presence of myofilaments with large numbers of dense bodies and dense plaques was more characteristic of SMCs and a large number of lysosomes and cytoplasmic granules more compatible with macrophages (Figure 25.D-E). Endothelial changes were similar to type I lesions. On SEM examination, several arteries exhibited mild endothelial changes characterized by an apparent increase in surface roughness, small areas of endothelial denudation which left the basement membranes or the

internal elastic lamina (elastic fibers) exposed, formation of “caves” in the endothelium, and the presence of irregular shaped endothelial cells (Figure 26.C). No collagen fibers and significant lipid and cellular debris deposition were noted in areas devoid of endothelial cells. In some areas, the lack of overlapping and flattened endothelial cells was consistent with abnormal intercellular junctional patterns. Clusters of red blood cells and occasional leukocytes were found adherent to the arterial luminal surface in some arteries.

D. Type III lesions

The increased presence of extracellular lipid and cholesterol clefts formed large confluent lipid areas in the subendothelium and adjacent media in type III lesions. Lipids and foam cells accumulation disrupted the arterial architecture but deformation of the artery was still considered mild. There was also an increased extracellular matrix between the elastic lamellae and an increased fragmentation of the elastin fibers (Figure 24.F). This lesion type could be qualified as preatheromas and was found in 7 arteries (11%). In one artery, lipid deposition was noted primarily in the media. Two arteries had mild positive staining for calcium on von Kossa stain. The preatheromatous lesion was positive for lipid on oil red O staining (Table 24).

Calcium granules were identified on TEM in several arteries (Figure 25.D). Higher degree of cellular degeneration was also noticed along with an increased presence of extracellular lipids and small and large cholesterol crystals measuring 0.1-2.5 μm in diameter. Compared to type II lesions, type III lesions contained a larger proportion of foam cells (Figure 25.E) which appeared to be derived from SMCs. On SEM, changes were similar but more severe to what was observed in type II lesions with small to moderate areas of endothelial surface erosions and clusters of blood cells adherent to the surface and, often, associated with the presence of fine fibrils consistent with fibrin (Figure 26.D). Overall and similar to type II lesions, apart from these small to moderate abnormal areas, the endothelial surface appeared minimally affected.

E. Advanced lesions: type IV and type V lesions

The accumulation of extracellular lipid, cellular debris, and calcium in the arterial wall leads to the formation of the lipid core, that incorporates a significant portion of the arterial circumference, disrupts the arterial architecture, protrudes in the lumen, and substantially narrows it. This advanced type IV lesion is consistent with an atheroma and was seen in 5 arteries (8%). Cells were sparse in the lipid core and were found mainly along the periphery. An increased presence of calcium granules and chondroid metaplasia was noted (Figure 24.G-H). Increased extracellular matrix between elastic laminae was also present and accompanied, in some cases, by lipid deposits.

Advanced lesions of type V, fibroatheromas encountered in four arteries (6%), were characterized by the addition of a fibrous cap over the lipid core and increased disruption of the arterial morphology and narrowing of the lumen (Figure 23.A, Figure 24.I). Extensive calcification and chondroid metaplasia were also present. The cap over the lipid core was mainly composed of collagen fibers. In one instance, a lesion was multilayered with two calcified lipid cores separated by connective fibromuscular tissue. The arterial luminal stenosis became more significant with this type of lesion and often more than 50% of the lumen was obstructed.

Calcification was prominent in advanced lesion types and only one artery was negative on von Kossa stain. The percentage of lipid also continued to increase (Table 25).

Ultrastructurally, the lipid core was composed of a massive amount of extracellular lipid droplets, cholesterol crystals, amorphous debris, disrupted collagen, and elastic fibers, dense

calcium granules, and rare foam cells and degenerating cells (Figure 25.G). Occasionally, some lipid-laden SMCs were found bordered by a thick basal lamina (Figure 25.B). Abundant collagen fibers were observed in the fibrous cap of type V lesions. On SEM, advanced lesions were characterized by wide surface defects and areas completely devoid of endothelial cells with, occasionally, the presence of leukocytes (likely monocytes) and clusters of erythrocytes adherent to the surface (Figure 26.E-F). The endothelial denudation revealed subendothelial structures consistent, depending on the degree of ulceration, with collagen fibers of the fibrous cap and lipid present within the lipid core (Figure 26.E-F).

F. Complicated lesions: type VI lesions

Two arteries (3%) were considered to have lesions complicated by fissures and hematomas (Figure 24.J). In these areas, increased collagen and the presence of erythrocytes, thrombocytes, and macrophages were noted on 0.5-micrometer thick sections and confirmed on TEM. However, thrombus formation could not be clearly identified in any artery. Nevertheless, the composition and organization of these lesions were very similar to type IV-V lesions. On SEM, changes were comparable to what was observed in other advanced lesion types (IV-V) with the presence of large number of fibrin fibers and blood cells in the fissure areas.

G. Type VII lesions

While all lesion types contain various amounts of calcium and chondroid metaplasia, calcification was the predominant feature of 3 arteries (5%), classified as type VII lesions. Lipid deposition was present but was minimal compared to advanced lesions and the amount of calcium identified (Table 25). Calcification resembled calcification in bones rather than being passive and dystrophic with the presence of chondrogenesis and osteogenesis. In one cockatiel, bone marrow formation was observed in the arterial wall (Figure 24.K).

The TEM revealed large amounts of extracellular and occasional intracellular calcium crystals, as well as some disrupted collagen and elastin fibers. Foam cells, extracellular lipids and cholesterol crystals were found but in small quantity.

Only one artery was evaluated by SEM and showed changes similar to those observed in type II-III lesions.

Figure 24: Cross-section of arteries from psittacine birds. (The tops of the figures are the luminal/endothelial sites. **A.** Type I. Polygonal and spindle cells with vacuolated cytoplasm (foam cells) in the tunica intima. Pulmonary artery (PA). Toluidine blue (TB). Bar = 30 μ m. **B.** Type I. Cytoplasmic lipid, stained red, in the foam cells within the tunica intima. PA. Oil red O (ORO). Bar = 30 μ m. **C.** Type II. Large numbers of foam cells within the tunica intima with overlying endothelial cells (arrow). Aorta (AO). TB. Bar = 30 μ m. **D.** Type II. Extracellular and intracellular lipid, stained red, within the tunica intima. AO. ORO. Bar = 30 μ m. **E.** Type 0. Normal media showing the regularly layered pattern of elastic fibers, stained black. Brachiocephalic trunk (BT). Verhoeff van Gieson (VVG). Bar = 100 μ m. **F.** Type III. Elastin fragmentation and formation of areas devoid of elastin (*). BT. Bar = 100 μ m. VVG. **G.** Type IV. An atheroma containing necrosis (*) and lightly basophilic granules indicating calcium deposits (arrow). AO. Bar = 50 μ m. Hematoxylin and eosin (HE). **H.** Type IV. Calcium, stained dark brown to black, within an intimal atheroma and the superficial tunica media. AO. Bar = 50 μ m. von Kossa. **I.** Type V. A fibroatheroma consisting of a fibrous cap (arrows) and underlying lipid core composed of lipid, cellular debris, cholesterol clefts (arrowheads) and extracellular matrix. AO. Bar = 30 μ m. TB. **J.** Type VI. A fissure with fibrous connective tissue (arrows) dissecting an atheroma. AO. Bar = 50 μ m. HE. **K.** Type VII. Ossifying metaplasia consisting of bone with mineralization (arrows) and a marrow cavity (*). AO. Bar = 50 μ m. HE. **L.** Type VII. A fibrous cap (double-head arrows) containing collagen, stained blue, and subjacent extracellular lipid and cartilage (*) indicating chondroid metaplasia. AO. Bar = 50 μ m. Masson's trichrome. *Insert:* Positively stained cells (brown), indicating smooth muscle cells and/or myofibrocytes, in a fibrous cap. Immunohistochemistry for smooth muscle actin. Hematoxylin counterstain.

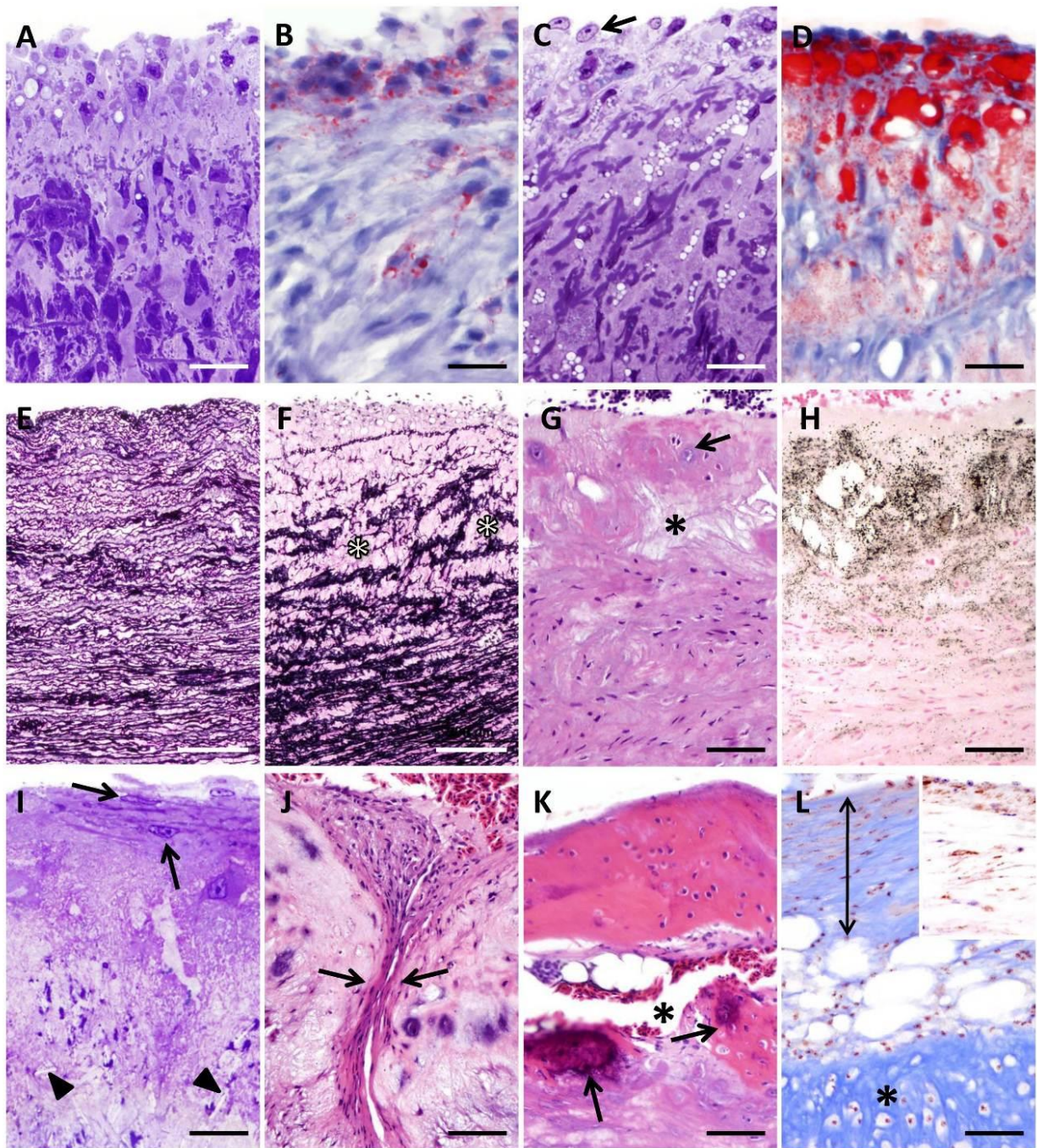


Figure 25: Transmission electronmicrograph of the major arteries of psittacine birds. **A.** Normal arterial wall exhibiting no evidence of atherosclerosis and showing two endothelial cells separated from the media by the internal elastic lamina. The media is composed of smooth muscle cells, elastin, and collagen fibers. X 8 000. Insert : Magnified view of the basement membrane of the endothelial cell (square). X 60 000. **B.** A smooth muscle cell is bordered by a thick basal lamina and contained some lipid droplets. X 12 000. **C.** A SMC exhibiting phenotypic changes with an increase presence of RER and lipid accumulation, X 10 000. Insert : Magnified view of the RERs. X 20 000. Type I lesion. **D.** An active macrophage, with abundant lysosomes and a small number of lipid droplets in the cytoplasm and surrounded by a large amount of extracellular lipid and extracellular matrix composed of various cellular debris, collagen fibrils, and sparse calcium granules. X 10 000. Type III lesion. **E.** Two macrophage-derived foam cells whose cytoplasm is filled with abundant lipid droplets and rare lysosomes. X 8 000. Type III lesion. **F.** A close-up view of the cytoplasmic membrane on the luminal side of an endothelial cells presenting an increase number of caveolae, some of them being coated. X 60 000. Type II lesion. **G.** A large amount of extracellular lipid, cholesterol crystals, calcium granules, and cellular debris with few cells are present. X 10 000. Type IV lesion. Ca, calcium granule; Ch, cholesterol crystal; Co, collagen fibril; db, dense body; Exl, extracellular lipid; Ld, lipid droplet; Ly, lysosome; Mf, microfilaments; My, myelin figure; N, nucleus; RER, rough endoplasmic reticulum. Orcein-uranyl-lead stain.

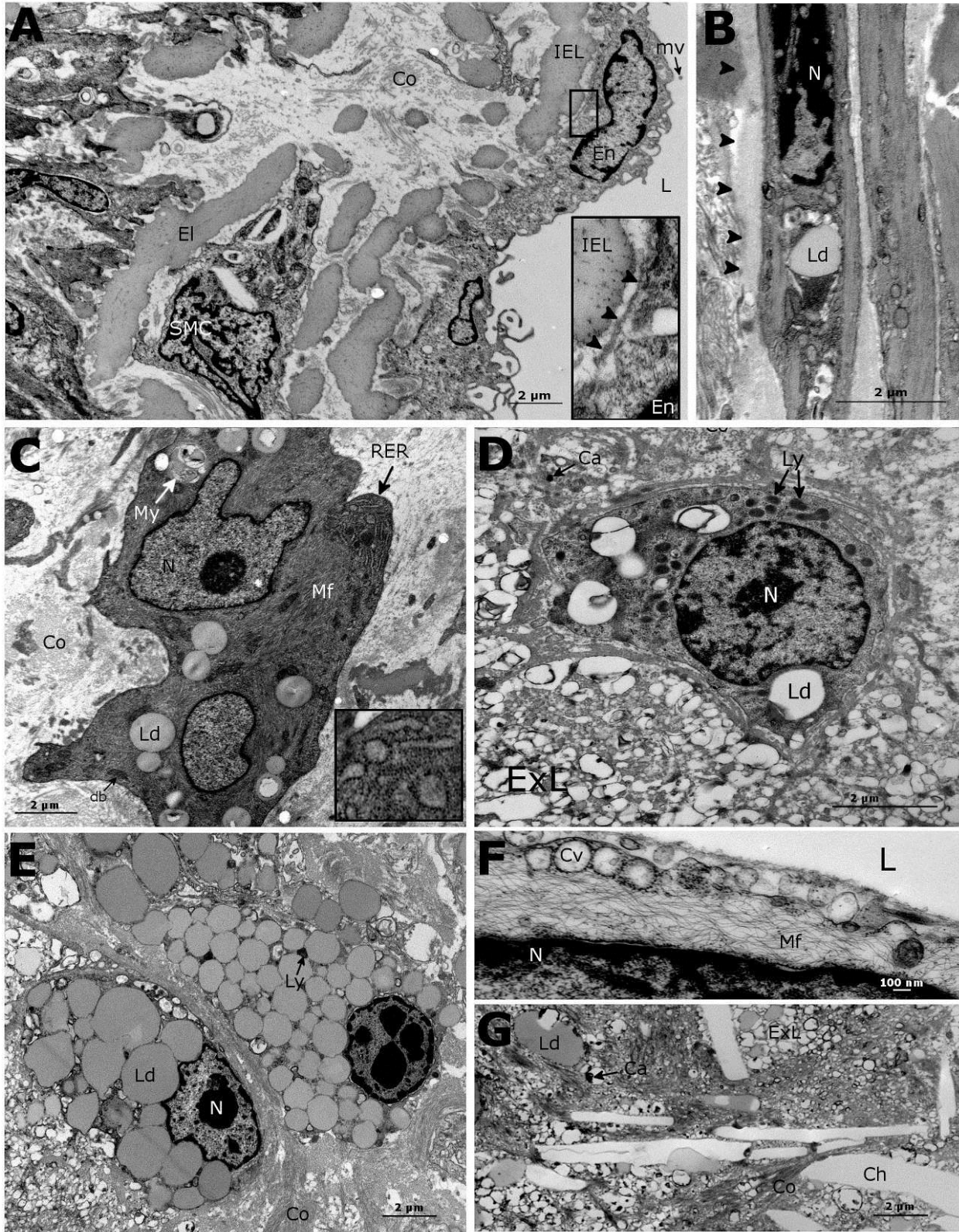





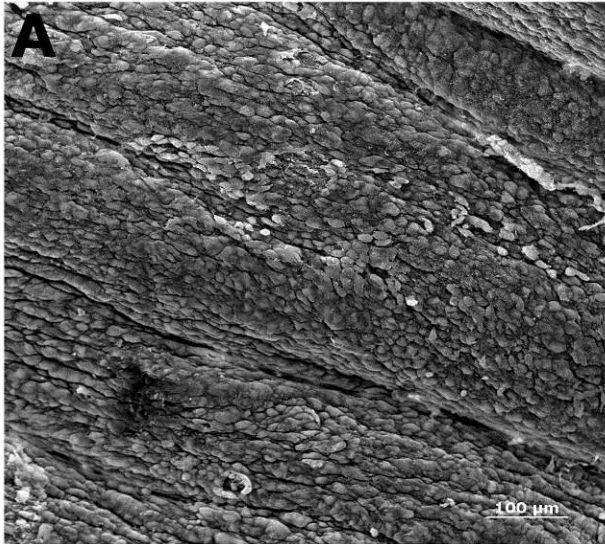


Figure 26: Scanning electronmicrograph of the major arteries of psittacine birds. **A.** Normal endothelial surface of the aorta showing the organization of the endothelial cells oriented in the direction of the blood flow. X 400. **B.** Cross section of a normal aorta where the endothelial cells (En) are overlying the concentric elastic fibers (EF) of the media. X 2 500. **C.** Type II lesion showing a demarcation area between normal endothelium (En) and endothelial denudation (*) where the underlying elastic fibers are seen. X 300. **D.** Type III lesion showing some endothelial cells (arrows) losing their intercellular junctions and detached from the arterial wall with exposed underlying basement membranes (*). X 300. **E.** Type IV lesion depicting an extensive area of endothelial denudation, a leukocyte (arrow) adhered to the surface in leukopedesis. X 2 000. Insert: A close-up view of this leukocyte. X 4 000. **F.** Type V lesion showing several erythrocytes (arrowheads) and leukocytes (arrows) adherent to the luminal surface which is devoid of endothelial cells, fine fibrils of fibrin seen on the surface. X 1 000.



IV. Discussion

In this study, the different atherosclerotic lesions were described and classified based on light microscopy, histochemistry, digital image analysis, and transmission and scanning electron microscopy. While the disease is common in parrots, the description of the lesions including the endothelial surface changes at the ultrastructural levels is presented here for the first time. With light microscopy evaluation of 0.5 micrometer thick sections and the use of electron microscopy, superior details of structure and detailed description of the cellular and extracellular components of the psittacine lesions could be achieved. These results lead to a classification system that better reflects the different steps or pathways of lesion progression, the pathogenesis of psittacine atherosclerosis, and the composition of the atherosclerotic lesions. The AHA human classification system was found to be suitable for the different lesion types found in parrots. While the sample size was small (24 parrots, 63 arteries), the different lesion types could be described in several arteries and the different morphologic variants were well represented. In our report, several psittacine species (11) were used for the lesion description and classification. The use of multiple species was not considered to be a limitation since the study was mainly observational, the location and histopathology of psittacine atherosclerotic lesions are homogenous, and veterinary pathologists do not usually focus on a single species.(Bavelaar & Beynen 2004a; Fricke et al. 2009; Garner & Raymond 2003; Krautwald-Junghanns et al. 2004) Furthermore, in recent studies, no difference was reported between species in lesion description and location.(Bavelaar & Beynen 2004a; Fricke et al. 2009; Garner & Raymond 2003; Krautwald-Junghanns et al. 2004; Pilny 2004) However, the use of different species should not be encouraged in experimental studies when a specific hypothesis is to be tested. Birds were obtained from a diagnostic pathology service and several limitations ensued. Variable degrees of post-mortem autolytic changes were noted, and some changes not detectable on light microscopy were observed at the ultrastructural level. Mitochondria, endothelial cells, and the endothelial surface were primarily affected and some features of endothelial cells could not be thoroughly evaluated. Weibel-palate bodies and anchoring fibrils to the subendothelial matrix were not observed but could still be present in normal psittacine endothelial cells. Moreover, blood monocytes adherent to the endothelium and/or their leukopexis through endothelial intercellular junctions could not be clearly identified, while suspected in some instances on electron microscopy (Figure 26.E). Finally, mitochondrial swelling and disruption combined with plasmalemmal disorganization can, in some instances, be confused with clear lipid droplets. As mitochondria and endothelial cells deteriorate rapidly after death,(Cheville 1994a; Stary et al. 1992) they should be fixed immediately after death for best results, especially in species that have a fast-metabolism such as birds. Additionally, arteries were not fixed under physiological pressure which made the assessment of the thin intimal layer on light microscopy and the morphology of the endothelial surface on SEM challenging. It is reported that collapse and retraction of arteries can cause configurational distortions and tissue disruptions that can lead to improper interpretation.(Stary et al. 1992)

Digital image analysis results show the progressive accumulation of lipid and calcium deposits with the increase severity of the atherosclerotic lesion (Table 25) which presented high correlations. In the proposed classification (Table 24 and Figure 23.B), type I and II lesions constitute phases of minimal changes with an increased accumulation of foam cells but a limited amount of extracellular lipids, calcium, and no disruption of the arterial architecture. Type III lesions are intermediate between mild and advanced lesions and, while mild disruption of the arterial wall is present, this type, with mild lesions, are likely to be clinically silent. Advanced

type IV to VI lesions are characterized by the build-up of lipid and cellular debris forming a fibroatheromatous plaque that can present complications such as fissures and hematoma. Significant calcification begins to occur in advanced lesion types, which was also observed on TEM (Table 25). These lesions are more likely to induce clinical signs and, in humans, are referred to as clinically important lesions.(Stary 2003a; Stary 2005) Type VII lesions are mainly calcific and do not contain a large amount of lipid. They may reflect lesion regression and repair from more advanced lesion types after reduction of risk factors (Figure 23.L).(Stary 2003a; Stary et al. 1995) In humans, calcification is a hallmark of advanced lesion types.(Stary 2003a) Arterial calcification in parrots is almost always caused by atherosclerosis and, consequently could be used as an imaging diagnostic marker and possibly quantified, as it is in human medicine, for the detection of clinically important and advanced lesion types. Calcification in atherosclerotic lesions involves the participation of osteoblasts and osteoclasts and a complex interplay between chronic inflammation and bone biology.(Doherty et al. 2003) Calcification usually progresses with the disease process and the development of complex lesions.(Doherty et al. 2003) The different lesion types indicate the likely sequence of atherosclerosis stages until the type IV lesion. After this stage, different pathways of progression are possible with different morphologic outcomes and potential complications. The equivalent to the human type VIII lesion characterized by reparative fibrotic tissue was not found in the arteries studied.(Stary et al. 1995)

In our study, a weak relationship was found between the age of the birds, the types of lesion, and the lipid and calcium composition of the plaques. This may be due to the confounding effect of other risk factors not evaluated in this observational study knowing that risk factors for atherogenesis have not been clearly identified in parrots. Since the diet was extremely varied across individuals, its relationship with the occurrence of atherosclerotic lesions could not be assessed.

Other published classification systems in parrots, pigeons, quails, and chickens were considered to less completely reflect the differences in lesions versus the AHA classification, as characterized with light and electron microscopy in our study.(Fricke et al. 2009; He et al. 2005; Orita et al. 1994; Santerre et al. 1972; Siegel et al. 1995) Classifications available in pigeons, quails, and chickens were often designed to serve specific experimental objectives and without the use of multiple modalities. Consequently, these classifications do not convey the same information and may not apply readily to the variety of spontaneous lesion types that can be encountered in diagnostic pathology. Nevertheless, these classifications were relatively close to the one determined in this study with usually 3 to 6 stages showing the progressive accumulation of macrophage foam cells and fat beginning in the intima, and ultimately resulting in a plaque composed of a lipid core and a fibrous cap (Figure 23.A).(He et al. 2005; Orita et al. 1994; Santerre et al. 1972) Two recent and comparable classifications of atherosclerotic lesions in psittacine birds have been reported and, based on histochemical and immunohistochemical methods, 4 stages of lesions were described.(Fricke et al. 2009; Schenker & Hoop 2007) In this system, lesion classification was not based on the progressive accumulation of fat, calcification, and cellular events, but was formulated on the successive occurrence of different extracellular compounds. The stage I of this classification depicted lesions characterized by elastin fragmentation but without the presence of fat. Since atherosclerosis is defined by the accumulation of lipids in the arterial intima and, occasionally, the media, an initial lesion without fat or foam cells cannot be considered to be part of this disease process. On the other hand, one may speculate that this lesion type constitutes a pre-atherosclerosis stage. In our proposed

classification and the AHA classification, the lesion type I constitutes the first evidence of detectable lipid and, as such, the first evidence of atherosclerosis.(Stary et al. 1994) Furthermore, in one of these previous studies, based on immunohistochemistry, macrophages could not be demonstrated in psittacine lesions and the authors concluded that the current response-to-injury hypothesis of atherogenesis was unlikely in parrots.(Fricke et al. 2009) However, these results may rather be due to the challenges of immunochemistry in the avian species. The presence of macrophages is the hallmark of atherosclerosis in all species studied and this cell type plays a fundamental role in lesion initiation and progression.(Bobryshev 2006; Cullen et al. 2005; Libby et al. 2002; Moore & Rayner 2010; Takahashi et al. 2002) In our study, macrophages were demonstrated by electron microscopy but no immunohistochemical antibodies with cross-reaction to psittacine macrophages could be found.

The use of TEM allowed the description of the ultrastructural characteristics of psittacine atherosclerotic lesions in details. The ultrastructure of the different types of lesions was invaluable in refining the classification criteria and gives an insight into the pathogenesis of the disease in psittacine species. Lesions were ultrastructurally similar to what has been described in other avian species (specifically the pigeon) and mammalian species including humans suggesting common pathogenetic pathways.(Barr et al. 1991; Chamberlain & Belton 1987; Hansen 1977; Lewis et al. 1985; Jerome & Lewis 1985; Nakamura & Ohtsubo 1992; Still 1963; Toda 1988; Yamamoto & Igawa 1991) Early lesions were mainly characterized by isolated foam cells, phenotypic changes of SMCs, increased extracellular matrix, and endothelial injury. As lesions progressed, there was an increase amount of extracellular lipid droplets and cholesterol crystals along with cellular debris, apoptotic cells, and calcium granules, particularly in the forming atheromatous core (Figure 25.G). Some other cell types that are difficult to identify by purely morphological criteria may also have been present. Foam cells appeared to be mainly derived from macrophages, particularly in early lesions (types I-III). Smooth muscle cell-derived foam cells appeared to increase in proportion with advanced (type IV-VII) lesions. However, the identification of the origin of foam cells can be challenging, particularly in more advanced lesions owing to the cellular degeneration and morphologic distortion caused by lipid accumulation. In pigeons' atherosclerotic lesions, foam cells are found to derive from both macrophages and SMCs and there appears to be a shift in foam cell nature as lesion progresses from macrophages in early lesions to SMCs in mature lesions.(Lewis et al. 1985) It is widely accepted that the three major cell types involved in atherogenesis are the endothelial cell, the SMC, and the macrophage.(Cullen et al. 2005; George & Lyon 2010; Nakamura & Ohtsubo 1992; Stary et al. 1994) Ultrastructural changes, which varied with the lesion types, were found in these three cell types in parrots with vacuolation and edema of endothelial cells, apparition of RER-rich SMCs (different from purely contractile SMCs) in early lesions suggesting an increased metabolic and secretory activity (Figure 25.C), and foam cells formation from SMCs and macrophages (Figure 25.E). Atherosclerosis is thought to be initiated by endothelial activation and dysfunction which is characterized ultrastructurally by an increase in cytoplasmic volume, pinocytotic vesicles (Figure 25.F), filopodia, vacuolation, and blood cells attachment.(Cheville 1994b; Nakamura & Ohtsubo 1992) Changes observed early on in psittacine endothelial cells could have been due to endothelial dysfunction but an accurate interpretation was limited by post-mortem artifacts present at the ultrastructural level. Smooth muscle cells associated with atherosclerosis are known to participate in the synthesis of proteoglycans, collagen, and other components of the extracellular matrix.(Cullen et al. 2005) The SMCs have also been found to proliferate and migrate into the intima, especially during

initial phases.(Cullen et al. 2005) These findings were supported by the changes from a contractile to a synthetic phenotype noted with a number of SMCs found in early lesions but their proliferation and intimal migration could not be assessed.

The characteristics of the endothelial layer were also investigated by SEM. In humans and other mammals, the endothelial surface changes characterized by SEM include surface irregularities, due to the underlying accumulation of foam cells, erythrocytes, and platelets, monocytes adhesion, endothelial cell proliferation, and endothelial erosions.(Terenzio Congiu et al. 2010; Dell'Orbo et al. 2010; Davies et al. 1976; Goode et al. 1977; Kamari et al. 2008; Pasquinelli et al. 1989; Song & Roach 1998; Walski et al. 2002; Weber et al. 1977; Zaikina et al. 1982) Similar changes have been observed in pigeons and Japanese quails.(Casale et al. 1992; Taylor & Lewis 1986) In our study, various stages of surface defects, endothelium denudation, and endothelial disorganization were observed in parrot arteries exhibiting atherosclerosis (Figure 26). Occasionally, blood cells were observed to adhere to the endothelium (Figure 26.E-F). Endothelial denudation was observed starting at type II lesions (Figure 26.C) and was severe in advanced lesions (Figure 26.E-F). Various underlying structures such as the basement membrane, collagen fibers of the fibrous cap, and the lipid core could often be observed depending on the stage and depth of ulceration. Surface irregularities due to atherosclerosis were likely present, but could not be accurately assessed because arteries were not fixed at physiological pressure. It is to be noted that only small areas, corresponding to about 10-15% of the arterial circumference, were evaluated on SEM and more severe endothelial lesions present in other areas of the arterial endothelium may have been missed.

In conclusion, the classification system proposed in this study, adapted from the AHA classification criteria, is supported by the different degrees of pathologic changes observed in the arterial wall by light and electron microscopy and quantified by digital image analysis. It also brings an insight into the pathogenesis of atherosclerosis in parrots and its comparison with other species of animals for which there is a substantial scientific literature foundation. While some mild differences with other species were present, our results suggest that the atherosclerotic lesion composition and pathogenesis in parrots is similar to other species studied including humans. Nevertheless, experimental studies in parrots would be the only means of studying the pathogenesis, the chronology of molecular and cellular events, and the lesion progression associated with psittacine atherosclerosis. Further studies are also needed to correlate the severity of lesion type with clinical signs and diagnostic markers.

CHAPTER II: PREVALENCE AND RISK FACTORS IN PSITTACINE ATHEROSCLEROSIS: A MULTICENTER CASE- CONTROL STUDY*

I. Introduction

Atherosclerosis is a chronic inflammatory fibroproliferative vascular disease characterized by the buildup of atheromatous materials composed of numerous compounds including inflammatory cells, lipid, calcium, and collagen in the luminal aspect of the arteries in response to multiple forms of endothelial injuries. Complications of atherosclerotic lesions lead to well-characterized common diseases in humans, including coronary artery disease, ischemic stroke, and peripheral arterial disease. As in humans, some species of birds seem extremely susceptible to atherosclerosis, therefore, avian models including pigeons, quails, and chickens have been extensively used. Studies on these species have elucidated some important aspects of the pathogenesis and treatment of atherosclerosis.(Bavelaar & Beynen 2004b; Moghadasian 2002; St Clair 1998) Among birds, psittacines seem particularly prone to developing spontaneous lesions principally in the large arteries at the heart base.(Bavelaar & Beynen 2004a; Beaufre, Nevarez, et al. 2011; Fricke et al. 2009; Krautwald-Junghanns et al. 2004) However, scientific investigations are scarce and certainly not of a scale in proportion to the importance of the disease in this taxon. Most studies have focused on prevalence and histopathology.(Bavelaar & Beynen 2004a; Beaufre, Nevarez, et al. 2011; Fricke et al. 2009; Garner & Raymond 2003; Johnson et al. 1992; Pilny 2004; Schenker & Hoop 2007; Krautwald-Junghanns et al. 2004)

The histologic lesions have been well described in psittacines and appear similar to humans and compatible with the classification system developed by the American Heart Association (AHA).(Beaufre, Nevarez, et al. 2011; Fricke et al. 2009; Stary et al. 1994; Stary et al. 1995) Psittacine atherosclerotic lesions consist of the progressive accumulation of inflammatory cells, cholesterol, fat, and cellular debris in the intima and luminal side of the media. In advanced lesions there is also formation of a lipid core (atheroma, type IV lesion) covered by a fibrous cap (fibroatheroma, type V) and complications such as fissures, hematomas, and thrombosis (type VI) may occur.(Beaufre, Nevarez, et al. 2011) In humans, clinically important lesions are defined as type IV-VI lesions based on reports from the AHA Committee on Vascular Lesions.(Stary et al. 1995; Stary 2003b) Human post-mortem and clinical imaging studies have shown that people with clinical signs of atherosclerosis had lesions of type IV or higher.(Stary et al. 1995; Farb et al. 1995; Sanz & Fayad 2008)

The epidemiology of atherosclerotic diseases is well described in humans, but for the most part, unknown in psittacine birds. Few studies have investigated the impact of dietary factors in psittacine birds.(Bavelaar & Beynen 2003; Bavelaar et al. 2005; Bavelaar & Beynen 2003; Petzinger et al. 2011; Bavelaar & Beynen 2003; Stanford 2005) Comparison of the epidemiology of atherosclerosis in humans and psittacines is appropriate as they are both long-lived species and may share common risk factors. The reported prevalence for atherosclerosis in

* This chapter originally appeared as Beaufre, H. et al., Prevalence and risk factors in psittacine atherosclerosis: a multicenter case-control study. *J Am Vet Med Assoc. In Press*. Reprinted with permission of the American Veterinary Medical Association.

psittaciformes varies widely from 1.9 to 92.4% depending on the study and species.(Bavelaar & Beynen 2004a; Fricke et al. 2009; Krautwald-Junghanns et al. 2004; Johnson et al. 1992; Pilny 2004; Garner & Raymond 2003; Bavelaar & Beynen 2003; Kellin 2009) Post-mortem retrospective and prospective studies on the prevalence of atherosclerosis in psittacines often have variable study design, different and/or poorly defined inclusion criteria often encompassing all lesion types, and do not control for confounding factors and covariables such as age and sex. Furthermore, there is a need to model the prevalence of such slowly developing lesions as a function of the age. The prevalence of atherosclerosis in psittacine birds based on age is unknown but appears greater in older animals.(Bavelaar & Beynen 2004a; Fricke et al. 2009; Beaufreere, Nevarez, et al. 2011) Knowing the prevalence of advanced and clinically important atherosclerosis is crucial to the development and interpretation of diagnostic tests (positive and negative predictive values) but also constitutes an invaluable aid in assessing and managing psittacine patients based on their signalment and medical history.

Risk factors are an individual's measurable characteristics which predict his or her probability of developing clinical disease. This definition does not imply a causal relationship but entails that risk factors must occur before the disease.(McGill & McMahan 2005) Risk factors for atherosclerotic diseases in humans include lifestyle (smoking, diet, physical inactivity, stress, alcohol, obesity), biochemical abnormalities (high cholesterol, triglyceride, LDL, low HDL, C-reactive protein, thrombogenic factors, homocysteinemia, lipoprotein(a)), physiological abnormalities (hypertension, diabetes mellitus, metabolic syndrome), and personal factors (age, sex, genetic) categories.(McGill & McMahan 2005; von Eckardstein 2005) In birds, genetic risk factors are present in White-Carneau pigeons and SEA (susceptible to experimental atherosclerosis) quails.(Smith, Smith, et al. 2001; Shih et al. 1983) In psittacines, predisposed species have been suggested and age, diet, and dyslipidemia are also frequently cited as potential risk factors.(Fricke et al. 2009; Beaufreere, Nevarez, et al. 2011; Bavelaar & Beynen 2004a) But to date these simple, yet primordial, potential risk factors have not been confirmed by studies that used a large representative parrot sample and robust statistical methods.

Atherosclerotic lesions can remain silent for a long time until the accumulation of atheromatous materials leads to pathologic complications and subsequent clinical signs in birds caused by ischemia, arterial aneurysm, stenosis, and cardiac consequences.(Johnson et al. 1992; Beaufreere, Holder, et al. 2011; Mans & Brown 2007; Phalen et al. 1996; Pilny 2004; Sedacca et al. 2009; Shrubsole-Cockwill et al. 2008; Simone-Freilicher 2007; Vink-Nooteboom et al. 1998) Therefore, the simple report of the prevalence of lesions of atherosclerosis and their associations with several variables (that cannot be risk factors) is of modest immediate clinical interest. Considering the implications in the definition of a risk factor, we suggest that veterinary clinicians would be better served by knowing risk factors for advanced atherosclerotic lesions rather than for lesions of various severities that may remain silent for decades. Atherosclerosis-induced avian diseases are challenging to diagnose and a better knowledge of their epidemiology and association with other diseases in psittacine species would undoubtedly improve their medical care in captivity.

With these goals in mind, we report a large multicenter retrospective case-control study on 5 psittacine genera aiming to determine associations between specific variables and advanced atherosclerotic lesions. Our hypothesis was that the prevalence of atherosclerosis would increase with age and that sex and some genera would show a higher prevalence than others. We also hypothesize an association with cardiac, hepatic, reproductive, and renal diseases.

II. Materials and methods

A. Study design and case-control selection

The available databases of 5 pathology centers were reviewed for all necropsy cases (excluding biopsy and cytology cases) for which the heart was evaluated for the following five genera of psittaciformes: *Psittacus* (African grey parrots), *Amazona* (Amazon parrots), *Cacatua* (cockatoos), *Ara* (macaws), and *Nymphicus* (cockatiels). Databases included the School of Veterinary Medicine at the Louisiana State University, Baton Rouge, LA, USA (2008-2010); the Ontario Veterinary College at the University of Guelph, Guelph, ON, Canada (2001-2011); the Schubot Center at the Texas A&M University, College Station, TX, USA (1988-1998); the Zoo/Exotic Pathology Service, Sacramento, CA, USA (1998-2011); and Northwest ZooPath, Monroe, WA, USA (1997-2012). Species, age, and sex were recorded for all subjects when available. Information from all submissions was reviewed to ensure they were necropsy submissions and not biopsy submissions.

Psittacine birds diagnosed with atherosclerosis were searched in the databases using the words “atherosclerosis” or “arteriosclerosis” and their misspelled variants. All the histopathology slides of these cases were retrieved and reviewed for the inclusion criteria. Only subjects presenting advanced atherosclerotic lesions of type IV-VI, according to a previously described classification system in psittacines (Table 24), in the brachiocephalic, pulmonary, carotid, coronary arteries or the aorta were included as cases in the study.(Beaufriere, Nevarez, et al. 2011) These types of lesions are defined as the clinically important lesions and prone to induce clinical signs in humans.(Stary et al. 1995; Stary 2003b) Parrots presenting other types of atherosclerotic lesions (I-III, VII) or in other locations were not included as cases.

For the second and third logistic models, a subset of the remaining birds was randomly sampled using a statistical software (R, “sample” statement) and included as controls. The number of controls selected was equal to the number of cases (ratio control/case=1). Criteria for control selection were limited to the patient failing to exhibit advanced atherosclerotic lesions on histopathology. Availability of patient information and completeness of pathology records were not required for selection to prevent potential selection bias. Furthermore, to address bias associated with centers, locations, databases, and pathologists, controls were matched with cases at each institution.

A more detailed history was then recorded for all cases and controls including species, age, sex, types of histologic lesions found (inflammatory, infectious, neoplastic, degenerative, traumatic, metabolic, and other), and organ systems affected (hepatic, gastroenteral, reproductive, musculoskeletal, respiratory, neurologic, cardiovascular (other than atherosclerosis), integumentary, endocrine, systemic, lymphoid (splenic/bursal), and renal). Lesions qualified as mild by the pathologists were not included in the analysis. The occurrence of specific diseases, potentially associated or concomitant with atherosclerosis, was recorded and comprised *Chlamydophila psittaci* infection, potential herpesvirus infection (internal papillomatosis, Pacheco's disease), vacuolar hepatopathy, hepatic fibrosis, renal glomerulopathy, nephrosis, myocardial fibrosis, myocardial degeneration, and myocarditis.

B. Statistical analysis

Missing data accounted for 26.6%, 25.2%, and 7.3% of age, sex, or both (unknown or unreported on submission sheets), respectively, and was assumed to be missing at random. To limit the loss of information and bias associated with list-wise deletion (default for statistical software), the missing values were dealt with multiple imputations.(Honaker et al. 2011) A

bootstrap based Expectation-Maximization-Bayesian (EMB) algorithm was used to perform 5 multiple imputations by missing value creating 5 different datasets.(Honaker et al. 2011) Age was included in the imputation algorithm with a log transformation to achieve normality, one assumption of the method.

Results were used to first construct a multiple logistic model to predict the prevalence of advanced atherosclerosis based on age, sex, and genus and to quantify the effects of these potential risk factors. This multiple logistic regression model was fitted simultaneously with the combination of each of the 5 entire datasets corresponding to the 5 imputations with the presence of severe atherosclerosis as the binary outcome variable with age, sex, and genera (dummy variables) as explanatory variables. Final model parameters were combined using Rubin's rules either manually or automatically by the statistical software.(Rubin 2004; Honaker et al. 2011) To compare the difference in prevalence between genera, the reference level for genera was accordingly changed in the model. To obtain odds ratio for each genus, a separate model with only one of the 5 genera dummy variables was run for each genus. To assess the validity of the imputation procedure, imputation diagnostics were performed by comparing the distribution of the imputed data to the complete data and by comparing the odds ratio obtained using the model with the complete-cases dataset (4264 birds) to the model using multiple imputations.

To investigate further associations, a more complex second multiple logistic model was subsequently fitted with only the cases and randomly sampled controls and with the addition of types of diseases and organ systems affected as explanatory variables. Only a few interaction terms corresponding to specific research hypothesis were part of the models (e.g. degenerative x cardiac). For this model, due to the high number of variables, a backward stepwise selection process was performed to find the best model (alpha to drop=0.15, alpha to enter=0.10). This was done manually not to remove variables that were part of an included interaction term. Different models were compared using the Akaike information criterion. Multicollinearity was checked with variance inflation factors prior to performing stepwise procedures.

Finally, a third logistic model investigating the association between severe atherosclerosis and specific lesions or diseases [*Chlamydophila psittaci* infection, herpesvirus infection (internal papillomatosis, Pacheco's disease), vacuolar hepatopathy, hepatic fibrosis, renal glomerulopathy, nephrosis, myocardial fibrosis, myocardial degeneration, and myocarditis] was fitted controlling for age, sex, and genus. The explanatory variables in the second and third models were not combined as they were assumed to be multicollinear.

Assumptions of the models and the presence of outliers were checked based on model fit and residual plots. Fit and predictive power of the models were assessed based on the area under the receiver operator curve (ROC). Odds ratio were obtained by exponentiation of the parameter estimates and were reported with their 95% confidence intervals (CI). A type I error rate of 0.05 was used for statistical significance. R (R development core team (2012). R foundation for statistical computing, Vienna, Austria. <http://www.R-project.org/>) was used for statistical analysis and the R-packages “Amelia II” (Honaker J, King G, Blackwell M (2011). Amelia II: a program for missing data. R package version 1.5-4. <http://CRAN.R-project.org/package=Amelia>) and “Zelig” (Imai K, King G, Lau O (2012). Zelig: everyone's statistical software. R package version 3.5.5. <http://CRAN.R-project.org/package=Zelig>) were used for multiple imputations and combinatory logistic models, respectively.

III. Results

A total of 7683 parrots were included in this study with 525 confirmed advanced atherosclerosis cases (IV-VI), which represented an overall prevalence of 6.8% (95% CI: 6.2-7.4) when not controlling for age, sex, and genus. Figure 27 shows the distribution of age in birds with known age (5640 birds). Of the parrots with known sex (5750 birds), there was 51.5% of females and 48.5% of males. The studied population included 17.9% of *Psittacus*, 14.9% of *Amazona*, 26.4% of *Nymphicus*, 16.1% of *Cacatua*, and 24.7% of *Ara*. The control to case ratio for the first logistic model was 13.6. There was only a mild difference in the point estimates of the odds ratios between the analysis using complete information and the larger analysis using multiple imputations (Table 26).

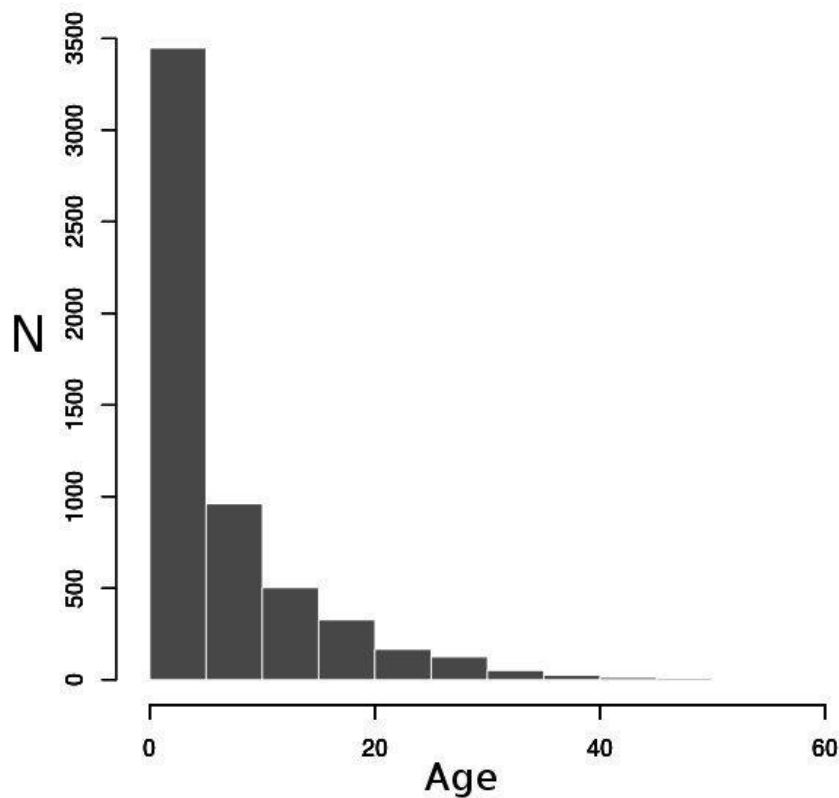


Figure 27: Distribution of ages of 5640 psittacine birds used in this study for which sex was known. N: number of birds, Age is in years.

Age, sex, and genera had a significant association with the prevalence of advanced atherosclerotic lesions on necropsy when holding other variables in the models constant (Figure 28, 29, 30, and Table 25). Older parrots and female parrots had increased odds of developing advanced lesions (Figure 28 and 29, Table 26). Males showed an estimated 31% decrease in odds compared to females.

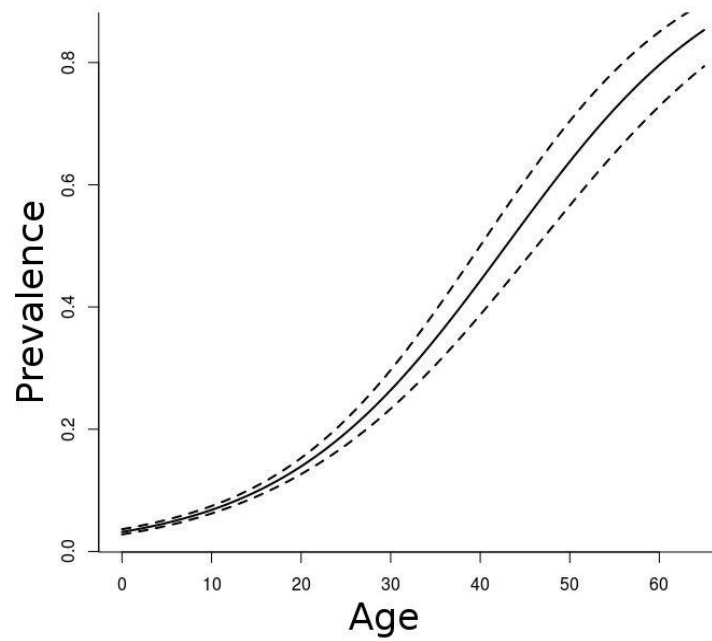


Figure 28: Estimated prevalence of advanced atherosclerotic lesions as a function of age from a population of 7683 psittacine birds. Dotted lines represent 95% confidence bands. Age is in years.

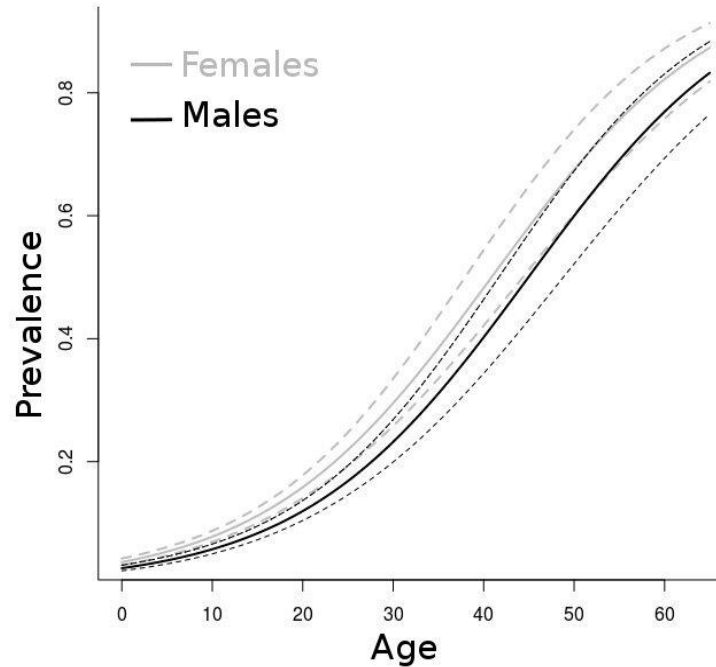


Figure 29: Estimated prevalence of advanced atherosclerotic lesions as a function of age and sex from a population of 7683 psittacine birds. Dotted lines represent 95% confidence bands. Age is in years.

Table 26: Odds ratio of age, sex, and genus with the presence of advanced atherosclerosis on necropsy in 7683 psittacine birds

Variable	OR	95% CI	p-value	ORcc
Age (1 year increase)	1.08	1.07-1.10	<0.001	1.10
Age (10-year increase)	2.22	1.93-2.57	<0.001	2.59
Sex (male/female)	0.69	0.56-0.85	0.007	0.66
<i>Psittacus</i>	2.75	2.23-3.45	<0.001	2.54
<i>Amazona</i>	1.83	1.45-2.30	<0.001	1.75
<i>Nymphicus</i>	1.46	1.14-1.87	<0.001	2.02
<i>Cacatua</i>	0.25	0.16-0.38	<0.001	0.20
<i>Ara</i>	0.13	0.08-0.20	<0.001	0.13

OR: odds ratio, CI: confidence interval, p-value for genera is for comparison with the overall mean response, ORcc: odds ratio for complete-case dataset on 4264 birds (without use of multiple imputation procedures)

Among genera, in descending order, African grey parrots, Amazon parrots, and cockatiels were particularly susceptible to atherosclerosis and had increased odds of having severe lesions compared to the other genera in the model and had a higher prevalence than psittacines overall (Table 25, Figure 28 and 30). Cockatoos and macaws seemed relatively less susceptible than average with a decrease in odds by 75% and 87%, respectively. Genera differed significantly from each other (*Psittacus-Amazona* comparison: $p=0.017$, all other $p<0.01$) except for *Amazona* that did not differ significantly in prevalence from *Nymphicus* ($p=0.38$) as well as *Cacatua* from *Ara* ($p=0.11$). The median effect level was reported as age for which a 50% probability of experiencing advanced atherosclerosis was observed (50% prevalence), which is equal to $(-\text{intercept} - \sum \text{dummy variables parameters}) / \text{age parameter}$ (because $\text{logit}[0.5]=0$) (Table 26). The area under the ROC was 0.83 for these models indicating a good fit. No outlying data were detected and the interaction between sex and age was not significant.

The second logistic model investigating association with disease revealed that birds exhibiting reproductive and/or hepatic disease were at increased odds of advanced atherosclerosis on post-mortem examination when controlling for age, sex, and genus (Table 28). This association appears to only be mild with hepatic disease. Most birds diagnosed with reproductive diseases were females (49/50). Birds with cardiac degenerative disease were at increased odds but this was not significant at the 0.05 level (but was at the 0.1 level of significance with a 90% CI of 1.06-5.90). The third logistic model showed only a significant increase in odds with myocardial fibrosis diagnosed along with atherosclerosis controlling for age, sex, and genus (Table 28). Only the odds ratio for positive parameter estimates with $p<0.10$ of the final selected models are reported. The area under the ROC curve was 0.86 and 0.85 for the second and third logistic models, respectively.

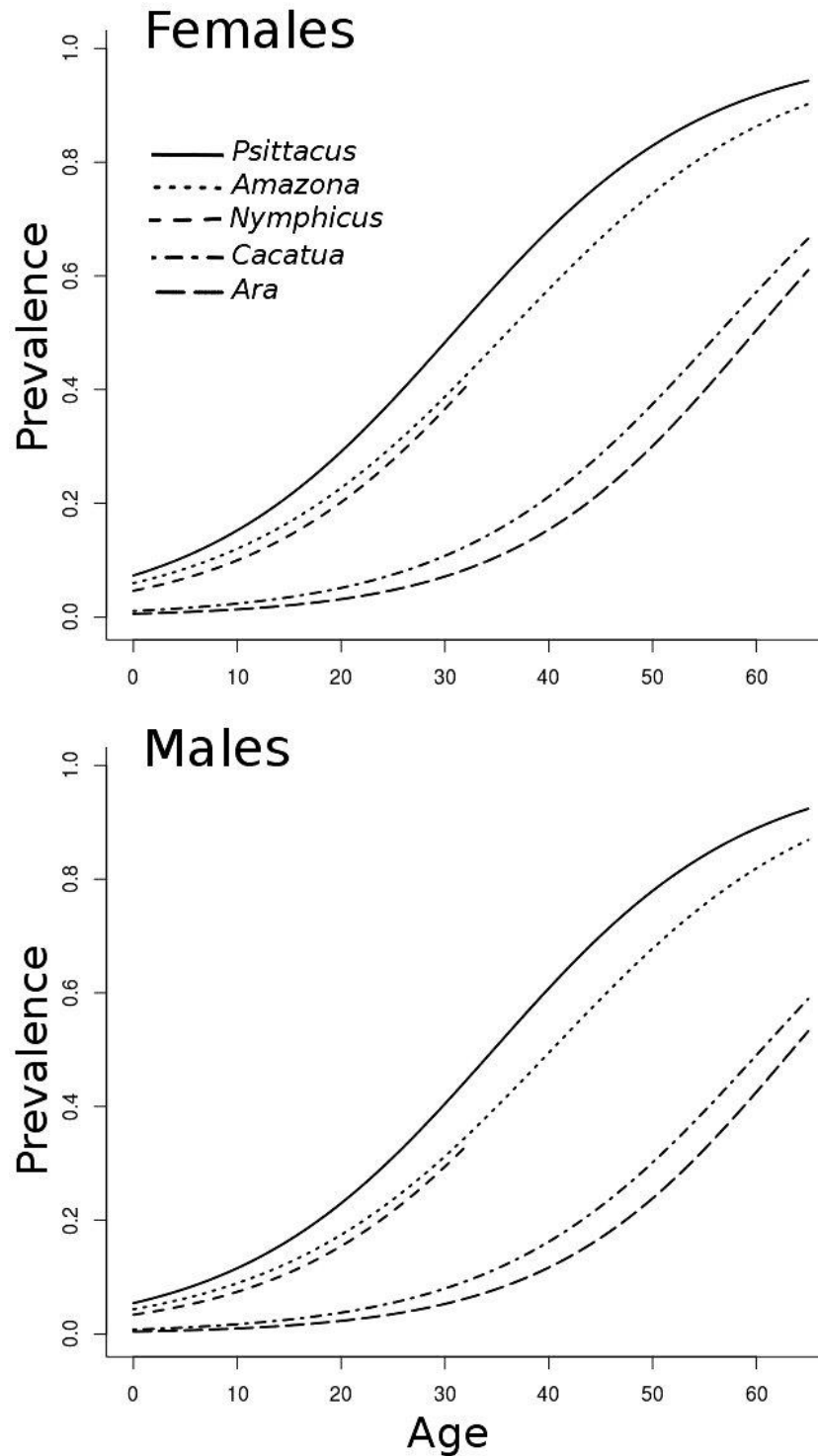


Figure 30: Estimated prevalence of advanced atherosclerotic lesions as a function of age, sex, and genus from a population of 7683 psittacine birds. Age is in years.

Table 27: Median age effect level (50% prevalence) for genus and sex in years in 7683 psittacine birds.

Genus	Male	Female
<i>Psittacus</i>	34.7	30.8
<i>Amazona</i>	40.3	36.0
<i>Nymphicus</i> ^a	40.6	36.7
<i>Cacatua</i>	60.5	56.4
<i>Ara</i>	63.5	59.8

^a the oldest cockatiel in the study was 30 year old but the median age effect level may still be a useful value to report in this species for comparison purposes

Table 28: Odds ratio for presence of diseases and lesions association with the presence of advanced atherosclerosis on necropsy in case-control logistic models with 525 cases controlling for age, sex and genus

Variable	OR	95% CI	p-value
<i>Second logistic model</i>			
Reproductive diseases	3.09	1.39-6.88	0.007
Hepatic diseases	1.58	1.05-2.39	0.030
Degenerative cardiac diseases	2.62	0.90-6.95	0.080
<i>Third logistic model</i>			
Myocardial fibrosis	4.68	1.83-12.00	0.001

Only variables with positive parameter estimates and $p < 0.10$ are reported. See Table 2 for the remainder of the keys

Atherothrombotic lesions, aortic rupture, aortic dissection, and plaque hemorrhage (atherosclerotic lesion type VI) were rarely diagnosed, in only 1.9% (10/525) of cases but always considered contributed to the death of the animal, based on pathologist comments (Figure 31.A). While difficult to objectively assess due to post-mortem arterial collapse and contraction, severe stenosis sometimes progressing to near complete occlusion seemed a relatively common finding with advanced lesion types (Figure 31.B) and always contributed to the death of the animal based on pathologists opinions. Only one case with advanced atherosclerosis was concomitantly diagnosed with *Chlamydophila psittaci* infection.

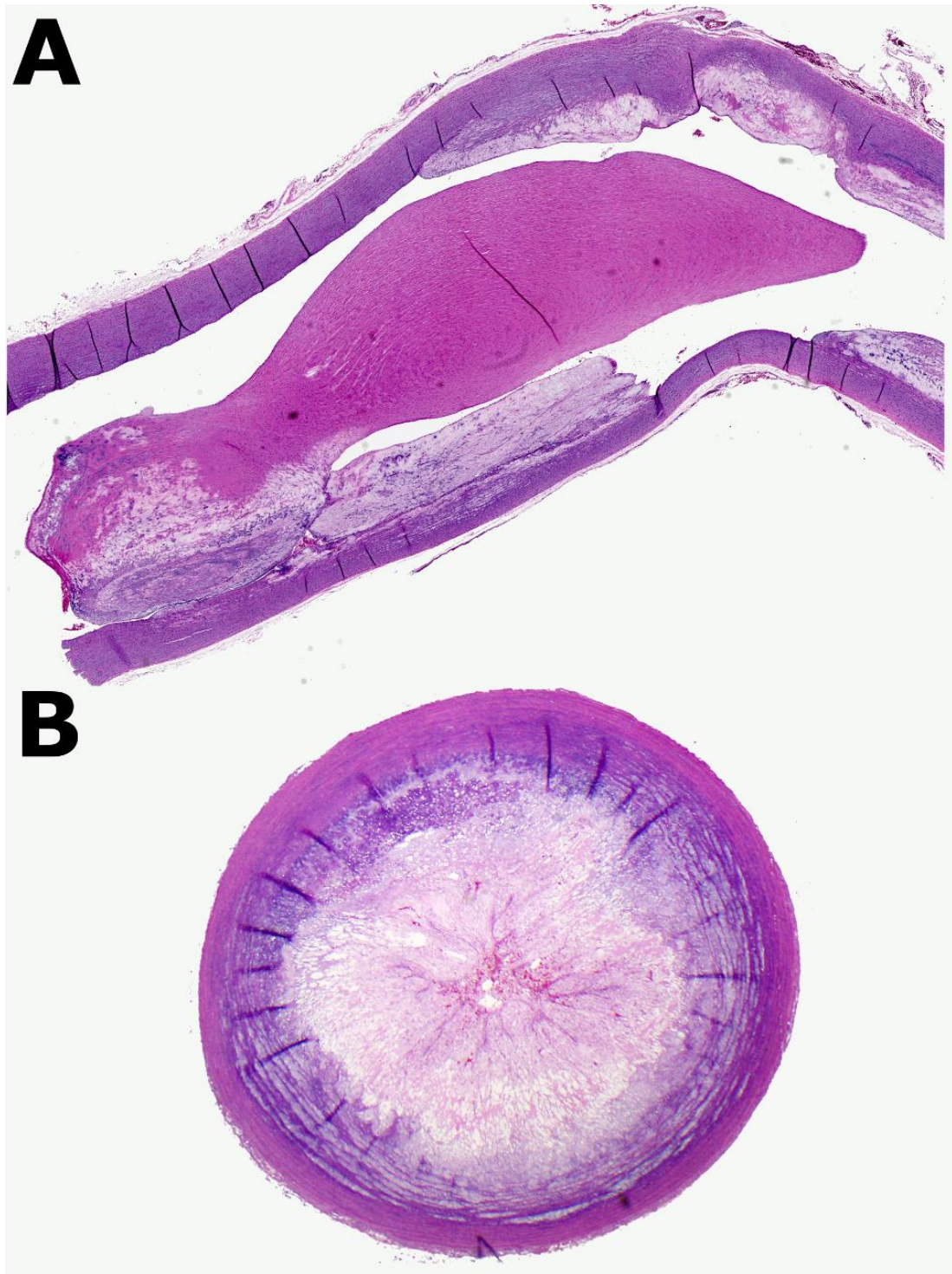


Figure 31: A: Atherosclerotic lesion type VI in a 13-year-old female African grey parrot (*Psittacus erithacus*) in a longitudinal section of the aorta. The lesion is composed of a large atheromatous plaque in the intima showing erosion and connected to an organized fibrin thrombus nearly obstructing the lumen. B: Atherosclerotic lesion type IV in an Amazon parrot (*Amazona* spp.) in a brachiocephalic artery in cross section. The lesion is composed of a large circumferential atheromatous plaque nearly completely obstructing the arterial lumen. No fibrous cap overlying the lesion is evident. (Hematoxylin and eosin, x100)

IV. Discussion

This observational retrospective study reports the prevalence and association of advanced lesions of atherosclerosis and selected epidemiological factors and concurrent diseases on necropsy in a large sample of parrots from 5 centers and for 5 of the most commonly seen genera by avian practitioners. This study is one of the largest epidemiological studies conducted in psittacine birds to date and showed, through multiple logistic modeling, that age, female sex, and *Psittacus*, *Nymphicus*, and *Amazona* genera were at increased odds of developing clinically important atherosclerotic lesions. Our large sample size allowed us to estimate this prevalence by age, sex, and genus with high precision. Atheromatous lesions were also found to be significantly and positively associated with reproductive disease, and mildly associated with hepatic disease, and concurrent myocardial fibrosis.

One can assert that the inclusion criteria for our cases were too stringent leaving some types of atherosclerotic lesions in the control population, or that the association between advanced lesion types and clinical signs remain to be proven in psittacine birds. While we concur with these arguments, several factors support that our approach is valid. The advanced type lesions (IV-VI) are qualified as clinically important in the AHA classification scheme and include lesions that produce clinical signs and silent lesions that have not yet caused disease by vascular occlusion or thromboemboli.(Stary 2003b; Stary et al. 1995) This lesion classification derived from human pathology seems to be supported in avian patients based on our study findings; stenosis was common, and also by a number of case reports where clinical signs could clearly be associated with arterial luminal narrowing and ensuing tissue hypoperfusion but not with atherothrombosis, plaque rupture, or pre-atheromatous lesions (type I-III).(Beaufreere, Holder, et al. 2011; Phalen et al. 1996; Pilny 2004; Sedacca et al. 2009; Shrubsole-Cockwill et al. 2008; Johnson et al. 1992) Complicated lesions (type VI) appeared rare in parrots as could be estimated in our study (1.9% of advanced lesions, 0.1% overall raw prevalence), which is consistent with previous reports.(Bavelaar & Beynen 2004a) However, clinical signs are not always caused by atherothrombosis and, in fact, humans experience a high rate of lesions, up to 26% in one study, associated with sudden coronary death for which thrombosis or other causes of death cannot be found on autopsy.(Virmani et al. 2000) In these cases, symptoms and deaths are suspected to be due to arterial stenosis leading to chronic myocardial ischemia and lethal arrhythmia.(Virmani et al. 2000) Furthermore, atherosclerotic diseases are challenging to diagnose in birds and a diagnosis is often, if not always, made on post-mortem examination.(Beaufreere, Pariaut, et al. 2010; Bavelaar & Beynen 2004a) Thus, in absence of a more valid and better alternative, studying the prevalence of type IV-VI atherosclerotic lesions as a surrogate for estimating the prevalence of atherosclerotic disease seems an acceptable strategy for parrots.

Our results must be interpreted in the context of the study limitations. The retrospective nature of this work presents several drawbacks: incomplete information, difficulties in extraction of valuable information from large databases, inability to show causal relationships, susceptibility to bias, and assessment of risk factors after the outcome of interest has occurred.(Schulz & Grimes 2002) The prevalence and severity found on necropsy may also be different from the true prevalence of the live population and advanced atherosclerotic lesions may have still been present but not represented in the available histopathologic sections. Sophisticated methods to deal with missing values such as multiple imputations reduce bias and increase efficiency compared to, for instance, performing statistical analysis on only complete data or imputing the overall mean; imputations incorporate the uncertainty associated with the missing values and limit information loss.(Donders et al. 2006; Harel & Zhou 2007; Honaker et al. 2011) In

addition, all organs were not always assessed by histopathology, which may have introduced some bias and limit the validity of our assessment on the association of general and specific lesions of other organ systems with advanced atherosclerosis. Control selection and sampling are important sources of bias and proper methods are crucial to interpret study results.(K. Schulz & Grimes 2002) For this reason, investigation of age, sex, and genus risk factors was performed by using the entire available population. Controls were sampled from this population for practical reasons to investigate more specific associations and examination of new hypotheses to be confirmed by future observations. Nevertheless, case-control studies are easier to perform than cohort studies, are inexpensive, can be performed in a relatively short time period, and may reveal important findings.(Schulz & Grimes 2002) The lengthy development of atherosclerotic lesions in long lifespan species do not easily lend itself to cohort studies and case control studies are an efficient alternative for such diseases with a long latency period.(Schulz & Grimes 2002)

Only five psittacine genera were included in this study and our results may not apply to other psittacine species. There are roughly 84 genera including 353 species within the order psittaciformes and it would have been challenging to account for all of them in a balanced and meaningful statistical model especially since some species are kept in captivity in relatively low numbers. For this reason, we decided to focus on only the most commonly seen genera by avian practitioners and pathologists.

The prevalence of advanced atherosclerotic lesions in psittacine birds is comparable to the human prevalence in North America keeping in mind the longer lifespan of humans with, for instance, a 30-50% prevalence in 45-75 years old humans.(Roger et al. 2011)

Age was found to be a significant and important risk factor of advanced atherosclerosis in the studied psittacine genera. This risk increases dramatically at about age 20-30 years (Figure 4). While this effect was demonstrated in previous psittacine studies, our study provides a more precise estimation of magnitude and a wider range of ages. A recent small case-control study showed a significant effect of age in preliminary analysis that failed to be significant in a multivariable model, but this may have been due to the small sample size.(Pilny et al. 2012) Interestingly, the odds ratio for age, obtained on a smaller sample, was nearly identical to ours (1.08 vs. 1.09 per year).(Pilny et al. 2012) Age is also an important predictor of atherosclerotic diseases in humans.(Roger et al. 2011; von Eckardstein 2005) The effect of age is explained by the increased exposure time to risk factors, the slow accumulation of atheromatous materials in the arteries over time, the physiologic effects of aging, and the rising prevalence and severity of specific cardiovascular risk factors with age such as dyslipidemias and hypertension.(von Eckardstein 2005) The number of older psittacine birds seen by avian veterinarians is expected to increase with the improvement of captive conditions and advancement of avian medicine, so the number of parrots presented with disease processes linked to atherosclerosis will likely increase.

Another important finding of our models is the significant effect of female sex on the probability of finding advanced lesions on necropsy. A female predisposition was noted by two previous investigators based on raw percentages.(Garner & Raymond 2003; Nichols & Montali 1995) However, this effect was not detected in the majority of previous studies, probably based on low sample size and statistical power.(Pilny et al. 2012; Fricke et al. 2009; Johnson et al. 1992; Bavelaar & Beynen 2004a; Bavelaar & Beynen 2003) In one report with over 1000 parrots, males had four times higher prevalence than females but the dataset was skewed toward male sex and the analysis was not controlled for confounding variables.(Fox 1933) Interestingly, SEA Japanese quails showed a male susceptibility for diet-induced atherosclerosis but this may not be comparable to spontaneous lesions.(Godin et al. 1995) In our report, males seem to lag

about 4 years behind females to reach similar prevalence (Figures 3 and 4, Table 2). This is a reversal from mammals and humans for whom males less than 55 years have 2-3 times more coronary heart disease events, strokes, or peripheral arterial disease than females and have a 50% increased lifetime risk of developing coronary artery disease.(von Eckardstein 2005; Roger et al. 2011) This sex difference diminishes after menopause but the risk in women lags by 10-15 years behind that of men.(von Eckardstein 2005; Roger et al. 2011) This effect is not completely understood but is thought to be related to sex hormones and environmental/lifestyle factors that varied between sexes.(von Eckardstein 2005; Mosca 2005) Protective action of estrogens may be directed at the cardiac and vascular levels but also through beneficial effects on blood pressure, hemostasis, inflammation and lipoprotein metabolism(Mosca 2005; Mendelsohn 2009) In fact, these effects could well be reversed in female birds for which estrogens have tremendous physiologic effects on lipid, protein, and calcium metabolism related to reproduction and egg formation.(Alvarenga et al. 2011; St Clair 1998) In reproductively active females, estrogen induce increases in plasma total calcium, proteins, cholesterol and triglycerides and hepatic synthesis of two specific lipoproteins, vitellogenin and VLDL_y (yolk labeled), which target the developing oocyte and are protected against the normal degradation of plasma lipoprotein lipase.(Alvarenga et al. 2011; Walzem et al. 1999) Increased plasma cholesterol, VLDL, VLDL remnants, and non-HDL cholesterol promote atherogenesis, providing a plausible explanation for the enhanced predisposition found in female psittacine birds.(von Eckardstein 2005; Zannis et al. 2005) Moreover, dietary supplementation of estrogens exacerbated lipid deposition in the aorta of 5-day-old female chicks.(Toda et al. 1981)

The genera predisposition found here is a confirmation of previously suspected or demonstrated species susceptibility.(Bavelaar & Beynen 2004a; Fricke et al. 2009; Pilny et al. 2012; Bavelaar & Beynen 2003) The reasons for this are unknown but one can speculate that these genera may have physiological and genetic differences or different captive lifestyle and stress levels that could influence atherogenesis. Also, these species have evolved with different dietary and lifestyle habits which have changed drastically in captivity.(Cornejo et al. 2011)

In the model investigating organ system and types of diseases, the highest effect was observed for reproductive disease, which further supports our finding of a female sex effect. These findings may reflect a more general and frequent dysregulation of the reproductive system occurring in captive psittacine birds which may subsequently promote chronic diseases in other organ systems.(Van Sant 2006; Bowles 2006) Only a mild association was found with hepatic disease and no association was found with vacuolar hepatopathy or hepatic fibrosis when controlling for other variables. These lesions were prevalent in both cases and controls. Human patients with hepatic lipidosis are at increased risk of cardiovascular diseases through a variety of mechanisms.(Bhatia et al. 2012; Kim et al. 2012) Therefore, our findings may be explained by differing pathophysiology of hepatic lipidosis in psittacine species than in humans, the multiplicity of causes, an incorrect disease classification, or some unidentified bias affecting these parameters such as incomplete histologic evaluation of all organs. Also, only moderate to severe lesions were included in the study. A previous study failed to find any association between atherosclerosis and illness types but some psittacine cases were concurrently reported with hepatic lipidosis and fibrosis.(Pilny et al. 2012; Phalen et al. 1996; Shrubsole-Cockwill et al. 2008)

Contrary to a recent case-control study using immunohistochemistry on arteries from 62 psittacine birds and in accordance with another report using PCR and immunohistochemistry in 103 birds, we did not find any association between avian chlamydiosis and atherosclerosis as

only 1/525 cases was confirmed to be infected on necropsy.(Pilny et al. 2012; Schenker & Hoop 2007) However, we did not attempt to detect *C. psittaci* antigens in arteries. Association with *C. pneumoniae* infection in humans remains controversial after decades of research.(Dugan et al. 2002; Hoymans et al. 2007; Sessa et al. 2009; C. Watson & Alp 2008)

Myocardial fibrosis was significantly related to the presence of advanced atherosclerotic lesions suggesting that these vascular lesions may induce cardiac pathologic changes that could lead to myocardial dysfunction, cardiac arrhythmia, or further degenerative changes. Myocardial fibrosis is a frequent finding in humans with coronary artery disease, is caused by chronic myocardial ischemia and systemic hypertension, and can lead to congestive heart failure and sudden death.(Wheeler & McNally 2005; Frohlich 2001; Liebson 2008) Severe myocardial fibrosis was diagnosed in several avian case reports diagnosed with advanced atherosclerotic lesions and in a high percentage of Amazon and African grey parrots in a previous study.(Fricke et al. 2009; Shrubsole-Cockwill et al. 2008; Sedacca et al. 2009)

Several major risk factors could not be assessed retrospectively. The diet, which is probably one of the most important modifiable risk factors, could not be investigated because it was rarely reported on submission sheets or the information was too scant to be of use. Clinicopathologic parameters could not be investigated. Total cholesterol was significantly higher in parrots diagnosed with atherosclerosis in a previous retrospective study.(Pilny et al. 2012) Total cholesterol and LDL rise in response to 1-2% cholesterol feeding and experimental induction of atherosclerosis in Quaker parrots (*Myiopsitta monachus*), budgerigars (*Melopsittacus undulatus*), and other avian models.(Pilny et al. 2012; Bavelaar & Beynen 2004b; Pilny 2004; Finlayson & Hirschinson 1961) (Beaufrère *et al*, in preparation) Moreover, Amazon and African grey parrots have higher plasma levels of cholesterol and the latter showed an increased plasma cholesterol when fed high-fat diet in feed trials.(Bavelaar & Beynen 2004a; Bavelaar & Beynen 2003; Bavelaar & A. Beynen 2003)

In conclusion, this large multicenter study provides avian veterinarians with useful information on prevalence and risk factors for advanced lesions of atherosclerosis in captive psittacine birds, and these may be of value in cardiovascular disease assessment and patient management. Reproductive diseases were the only identified potentially modifiable risk factor. There is no prospective information to definitely confirm this association, we suspect that reproductive diseases are likely to be true risk factors based on three elements: presence of a significant female susceptibility, significant association found with reproductive diseases, and the common occurrence of chronic reproductive disorders in captive psittacine pets. Therefore, prevention and management of reproduction dysfunction in captivity and salpingohysterectomy in females may show some benefit in lowering the prevalence of atherosclerosis in psittacine birds.

CHAPTER III: EXPERIMENTAL DIET-INDUCED ATHEROSCLEROSIS IN QUAKER PARROTS (*MYIOPSITTA MONACHUS*)*

I. Introduction

Similar to humans, birds have a high susceptibility to atherosclerosis and probably show the highest prevalence and severity of atherosclerotic lesions among vertebrate animals under standard captive conditions.(F. J. Bavelaar & A. C. Beynen 2004a; Beaufrere et al. *in press*) Non-psittacine avian models have been extensively used for the experimental investigations of atherosclerotic lesions and their associated physiologic complications in species such as the white Carneau pigeon, Japanese quail, and chicken.(Xiangdong et al. 2011; St Clair 1998; Singh et al. 2009; Shih et al. 1983)

Birds of the order psittaciformes (e.g. parrots, cockatoos) are long-lived species and seem especially prone to atherosclerosis with a high prevalence of lesions in the captive population.(Bavelaar & Beynen 2004a; Beaufrere, Nevarez, et al. 2011; Beaufrere et al. *in press*; Fricke et al. 2009) In psittacines, atherosclerotic lesions occur spontaneously and on cholesterol-free diet but, unlike in pigeons, which develop them in the thoracic aorta, they are predominantly located in the main elastic arteries at the base of the heart and in the carotid arteries. Although identified less often in psittacine species than in humans, coronary and other peripheral arterial lesions are also diagnosed on a regular basis through histopathologic examination. In addition, parrots show clinical manifestations of advanced atherosclerotic lesions caused mainly by arterial luminal stenosis (e.g. ischemia, claudication, stroke) with the histologic characteristics of the lesions being similar to those associated with human disease.(Sedacca et al. 2009; Beaufrere, Holder, et al. 2011; Bavelaar & Beynen 2004a; Vink-Nooteboom et al. 1998; Phalen et al. 1996; Simone-Freilicher 2007; Mans & Brown 2007; Beaufrère et al. 2011) However, atherothrombosis, plaque rupture, and myocardial infarction are considered infrequent in psittaciformes. A recent large multicenter case-control study on over 7600 captive psittacine patients has shown that age, female sex, some genera, and concurrent reproductive diseases were potential risk factors for the development of advanced atherosclerotic lesions of type IV-VI of the American Heart Association (AHA) classification.(Beaufrere et al. *in press*) Furthermore, the prevalence of atherosclerotic lesions by age groups was comparable to humans. The pathophysiology and risk factors of psittacine atherosclerosis are still poorly understood. Also, the ante-mortem diagnosis is challenging and the correlation between clinical signs and the degree of histological changes is unclear with current scientific knowledge.(Beaufrere, Pariaut, et al. 2010; Beaufrere et al. *in press*) Therefore, a psittacine model is highly needed to investigate diagnostic tests, explore pathogenesis and risk factors, and test potential treatments of this common disease of parrots. One report published in 1962 documented significant atherosclerosis and hypercholesterolemia in budgerigars (*Melopsittacus undulatus*) fed a diet composed of 2% cholesterol and 15% lard, but since that study, an experimental psittacine model of

* This chapter originally appeared as Beaufrere, H. et al., Experimental diet-induced atherosclerosis in Quaker parrots (*Myiopsitta monachus*). *Vet Pathol. In Press*. Reprinted with permission of Veterinary Pathology.

atherosclerosis has not been established and used for atherosclerosis research investigation.(Finlayson & Hirschinson 1961)

Other atherosclerosis animal models involve mainly mammalian species such as mice, rats, hamsters, rabbits, swines, guinea pigs, dogs, and non-human primates.(Xiangdong et al. 2011; Singh et al. 2009) Among these, genetically engineered mice are currently the most popular.(Xiangdong et al. 2011; Singh et al. 2009) While mammals share similar lipid physiology and are closer to humans than birds, mammalian species used as models rarely develop spontaneous advanced lesions under normal circumstances while being fed a standard diet with the exception of primates. Therefore, the results obtained from experiments using inbred and genetically modified animals cannot easily be translated to spontaneous-occurring lesions in the same species.

Here, we report the experimental dietary induction of advanced atherosclerotic lesions in Quaker parrots (*Myiopsitta monachus*), a small psittacine species susceptible to spontaneous atherosclerosis.

II. Materials and methods

A. Experimental design

Sixteen captive-bred Quaker parrots (*Myiopsitta monachus*) of unknown sex ranging in age from 6 months to 2 years were used in this study. The birds were housed in pairs and kept in stainless steel cages in a laboratory animal facility. The research protocol was approved by the Louisiana State University – Institutional Animal Care and Use Committee. The parrots were acclimatized for 6 months and converted to a commercial pelletized psittacine diet (Kaytee Exact Natural, Kaytee). The birds were randomized to one control group of 4 birds and one treatment group of 12 birds with differing lengths of treatment using statistical software (R). A psittacine atherogenic diet was formulated and manufactured by Kaytee from the company's maintenance parrot pellets formula (Exact Natural) with the addition of 1% cholesterol keeping a similar calorie and micronutrients to protein ratio with the control diet to obtain similar daily caloric and protein intake among groups. The cholesterol was obtained as 92.5% cholesterol from sheep wool (Sigma, C8503). Both the atherogenic and control diets were submitted for nutritional analysis to an independent A2LA accredited laboratory (Eurofins Scientific Inc., Nutrition Analysis Center, Des Moines, IA) (Table 29). The atherogenic diet was fed for 2, 4, 6, 8 months with 3 birds allotted to each time period. Each group of birds was euthanized at the end of their specific period by intravenous injection of potassium chloride under isoflurane anesthesia. The control group was fed the control diet. Two birds from the control group were euthanized before the study was initiated to ensure the lack of any detectable atherosclerotic lesions and the 2 remaining birds at the end of the study period at 8 months. Food consumption was monitored daily by providing 18g of pellets per bird per day and weighing unconsumed food and food waste at the cage bottom before the subsequent feeding. All birds were weighted on a monthly basis until they were euthanized.

Table 29: Nutritional analysis on the atherogenic and control diets used in an experiment on diet-induced atherosclerosis in Quaker parrots (% dry weight).

Nutrient	Atherogenic diet	Control diet
Moisture (%)	11.77	10.65
Protein (%)	17.17	15.70
Calories (kcal/100g)	455	435
Protein/calorie ratio	0.038	0.036
Ash (%)	4.13	4.44
Crude fiber (%)	2.72	2.69
Calcium (%)	0.35	0.35
Chloride (%)	0.31	0.47
Potassium (%)	2.49	2.43
Sodium (%)	<0.025	<0.025
Crude fat (%)	14.17	10.63
Cholesterol (%)	0.9951	0.0036
Fatty acids (%)	10.68	8.70
Caprylic acid (%)	<0.01	<0.01
Capric acid (%)	<0.01	<0.01
Lauric acid (%)	0.01	0.02
Myristic acid (%)	0.02	0.02
Palmitic acid (%)	1.37	1.15
Margaric acid (%)	0.01	<0.01
Stearic acid (%)	0.36	0.29
Oleic acid (%)	2.47	2.05
Linoleic acid (%)	5.60	4.52
Linolenic acid (%)	0.60	0.46
Arachidic acid (%)	0.03	0.03
Arachidonic acid (%)	<0.01	<0.01

B. Samples collection and analysis

A 1 mL blood sample was obtained monthly from each bird and was used to measure packed cell volume, avian plasma biochemistry profile (Avian/Reptile rotor, Abaxis Vetscan), cholesterol, triglycerides, total cholesterol and HDL (Ortho Vitros 250 Chemistry Analyzer). The VLDL and LDL were obtained using the Friedewald formula.(Friedewald et al. 1972) A larger

blood sample (3 mL) was obtained under anesthesia prior to euthanasia. Plasma cholesteryl ester transfer protein (CETP) activity was measured using a commercial assay according to the manufacturer instructions (ab65383, Abcam Inc.) and a complete blood count performed using the Leukopette technique. Plasma was stored at -80 C until analysis.

The ascending aorta, brachiocephalic and pulmonary arteries were collected within 15 minutes of euthanasia and sections were fixed in 10% neutral formalin for histopathology and in 2% paraformaldehyde and 1.25% glutaraldehyde in a 0.1 M cacodylate buffer for transmission electron microscopy (TEM). The heart and liver were also collected and fixed in formalin. Additional fresh sections were stored at -80°C for cholesterol measurement. Sex was determined at necropsy. Formalin-fixed tissues were routinely processed into paraffin. Five-micrometer sections were cut and stained with hematoxylin and eosin, von Kossa for calcium salts, and Masson's trichrome for collagen. Frozen formalin-fixed sections were also stained with oil red O (ORO) for lipid. Arterial tissues fixed for electron microscopy were processed, sectioned, and stained using standard techniques. They were rinsed 5 times in 0.1 M cacodylate buffer containing 0.02 M glycine over a 12h period. Samples were post-fixed in 2% osmium tetroxide for 1h, rinsed in water, *en bloc* stained in 0.5% uranyl acetate in the dark for 1h, rinsed in water twice, dehydrated in ethanol series, infiltrated with LR White (Electron Microscopy Sciences, Hatfield, PA, USA) resin series for 12h periods, and embedded in LR White overnight at 60°C. Sections with 0.5 µm thickness were cut with a Dupont Sorvall MT-2 microtome and stained with 0.5% toluidine blue O in 2% sodium borate. Samples were then sectioned at 70 nm thickness for transmission electron microscopy (TEM) using the same microtome. TEM sections were mounted on collodion-coated copper grids, stained with Reynolds lead citrate, and imaged with a JEM-1011 transmission electron microscope (JEOL, Tokyo, Japan). Atherosclerotic lesion types were categorized according to a published classification system in parrots that mirrors the AHA classification.(Beaufre, J G Nevarez, et al. 2011) Total cholesterol was measured in fresh arterial samples using a commercial assay according to the manufacturer instructions (ab65359, Abcam Inc.).

Lesions were also qualitatively compared to spontaneous lesions in 16 Quaker parrots obtained from a veterinary pathology laboratory (Zoo/Exotic Pathology Service, Sacramento).

C. Statistical analysis

Hepatic cholesterol content and CETP plasma activity between groups were compared using a Kruskal-Wallis test. Repeated measures over time were analyzed using linear mixed models with parrots as random variable and treatment, time, and polynomial terms as fixed variables when appropriate. Arterial cholesterol content was similarly analyzed but with time and artery as fixed effects. Variance heterogeneity and dependence among observations were modeled using variance functions and serial correlation structures when appropriate. Competing models were evaluated based on Aikake information criterion and model assumptions were evaluated on residual and quantile plots. Parametric and non-parametric post-hoc comparisons were performed with a Tukey adjustment. Correlations between lesion types in aorta and brachiocephalic arteries and plasma cholesterol at euthanasia or arterial cholesterol were assessed using a Kendall tau correlation coefficient. Correlations between plasma cholesterol at euthanasia and arterial and liver cholesterol concentrations were assessed using a Spearman correlation coefficient. A $p < 0.05$ was used for statistical significance. R (R development core team (2012). R foundation for statistical computing, Vienna, Austria. <http://www.R-project.org/>)

was used for statistical analysis and the R package “nlme” for mixed modeling.(Pinheiro & Bates 2000)

III. Results

Four out of sixteen Quaker parrots were females and one female was in each group except for the 8 months group. The Quaker parrots consumed an average of 9.9 g (95% CI: 9.4-10.3) of pellets daily (intercept only mixed models). There was a significant time*treatment interaction effect on the daily food consumption ($t=15.6$, $p<0.001$). The control parrots had a food consumption that increased with time (approximately 20% in 8 months, $t=17.5$, $p<0.001$) and was, overall, greater than the parrots in the treatment groups (approximately 15%, $t=2.55$, $p=0.025$). Parrots in the treatment groups had a stable food consumption over time of 9.6 g (95% CI: 9.5-9.6) daily corresponding to 84.3 mg (788.6mg/kg) of cholesterol daily. The mean \pm SD weight of the parrots was 106.9 \pm 10.1 g, which did not change over time ($t=-0.6$, $p=0.55$) or with treatments ($t=-0.8$, $p=0.86$). No bird displayed any abnormal clinical signs during the study.

Overall there was a high interindividual variability for all measurements that frequently accounted for close to 70% of the total variance of the mixed models.

The mean plasma total cholesterol concentration in control birds was constant over time with a mean \pm SD of 6.5 \pm 1.6 mmol/L and overall lower than the treatment group parrots ($p<0.001$). The mean plasma cholesterol concentration in treatment groups increased significantly overtime as well as the variance. It was best modeled using a cubic polynomial (cholesterol(mmol/L)=3.3+27.3*time-5.9*time²+0.4*time³, $p<0.001$, $p<0.001$, $p=0.03$, $p=0.19$, respectively) with a power of variance covariate for the variance structure ($\text{Var}=\sigma^2(\text{time})^{2*0.87}$). Even if the cubic term was not significant, it brought substantial smoothing of the curve and an overall better fit to the data. The mean cholesterol concentration reached a plateau at about 3-4 months (Figure 32).

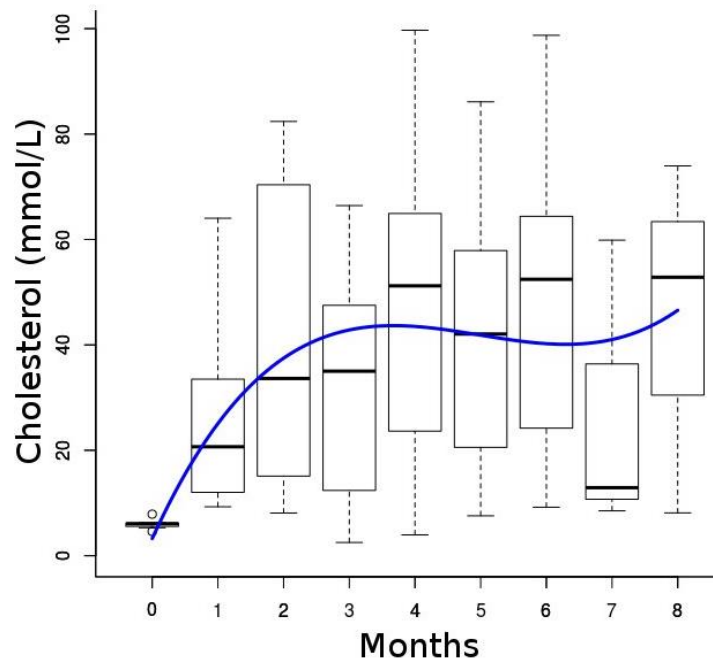


Figure 32: Plasma cholesterol concentration over time with a polynomial regression line.

The mean plasma LDL cholesterol concentration in control birds was constant over time with a mean \pm SD of 0.5 ± 0.4 mmol/L and overall lower than in parrots in treatment groups ($p < 0.001$). The rising total cholesterol concentrations in treatment groups was explained by the LDL cholesterol, thus it followed a similar trend ($\text{LDL}(\text{mmol/L}) = -0.6 + 22.6 \cdot \text{time} - 4.0 \cdot \text{time}^2 + 0.2 \cdot \text{time}^3$, $p = 0.3$, $p < 0.001$, $p = 0.04$, $p = 0.34$, respectively, variance structure: $\text{Var} = \sigma^2(\text{time})^{2 \cdot 0.89}$). Likewise, the mean LDL concentration reached a plateau at about 3-4 months (Figure 33).

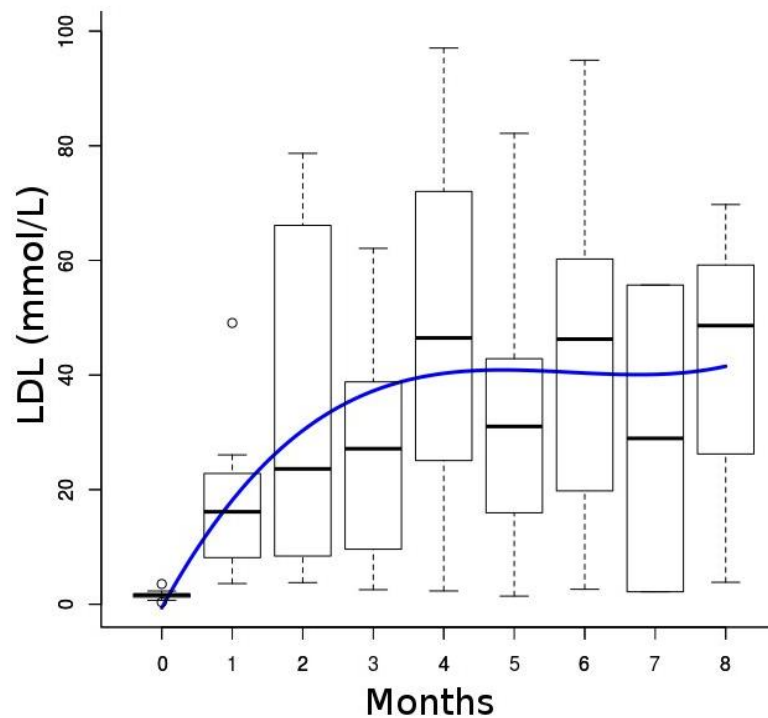


Figure 33: LDL cholesterol concentration over time with a polynomial regression line.

The HDL cholesterol plasma concentrations did not change significantly over time ($t = -0.5$, $p = 0.61$) or between treatment and control groups ($t = 0.19$, $p = 0.85$) with a median (interquartile range) of 3.8 (2.7) mmol/L (Figure 34). Mean triglycerides and VLDL cholesterol plasma concentrations did not change significantly between treatment and control groups ($t = -4.8$, $p = 0.39$) but slightly decreased overtime ($\text{triglycerides}(\text{mmol/L}) = 1.58 - 0.05 \cdot \text{time}$, all $p < 0.001$) (Figure 35). HDL was the predominant cholesterol type in plasma before starting the feed trial but LDL became preponderant on the atherogenic diet.

No other biochemical and hematologic parameters showed any significant difference over time between control and treatment groups (all $p > 0.05$).

Cholesteryl ester transfer protein activity was detected in all Quaker parrots' plasma samples. While CETP activity was generally greater in parrots on the atherogenic diet than on the control diet, the difference was not significant (Kruskal Wallis test, $p = 0.298$) (Figure 36). The median (interquartile range) was 45.80 (38.9 - 65.0) nmol/mL/h and 99.40 (46.10 - 148) nmol/mL/h in the control and treatment groups, respectively.

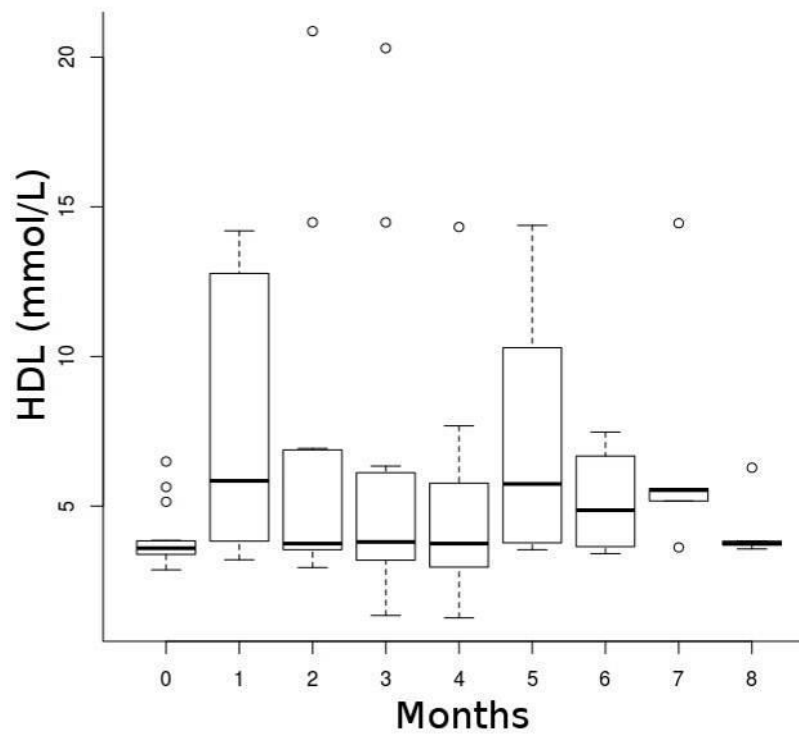


Figure 34: HDL cholesterol concentration over time.

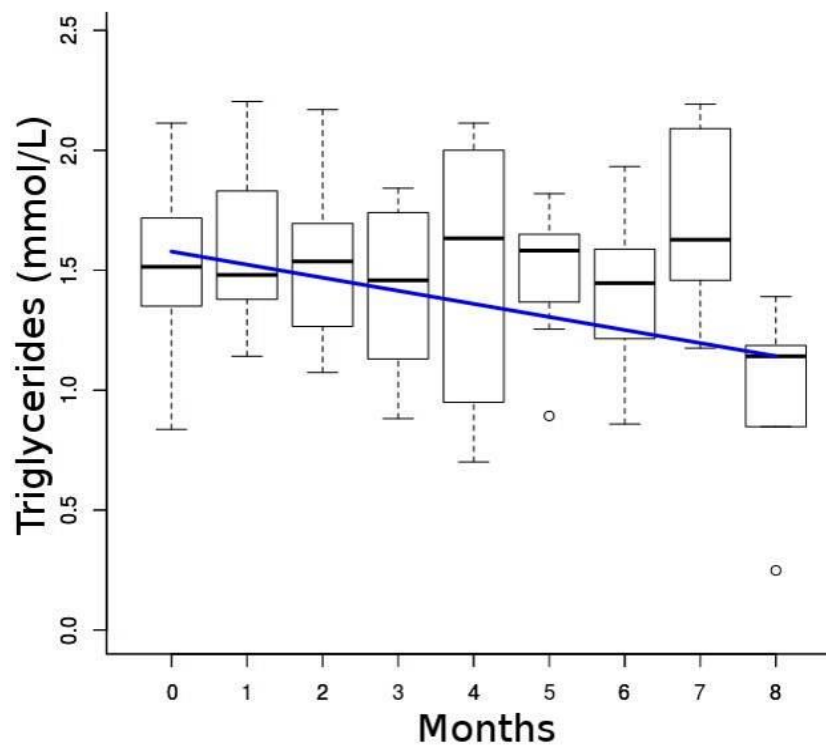


Figure 35: Triglycerides concentration over time with a linear regression line.

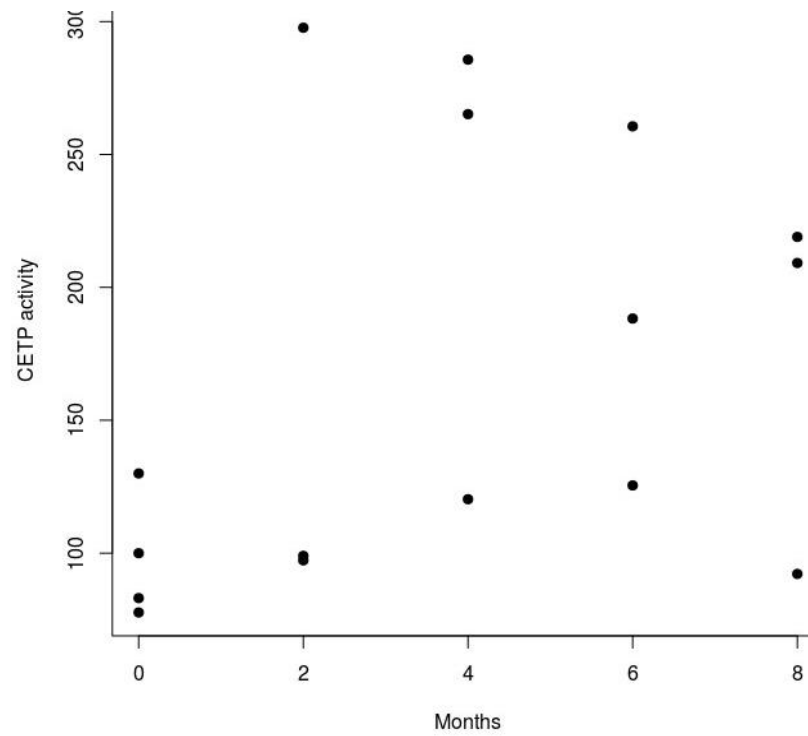


Figure 36: Plasma CETP activity over time.

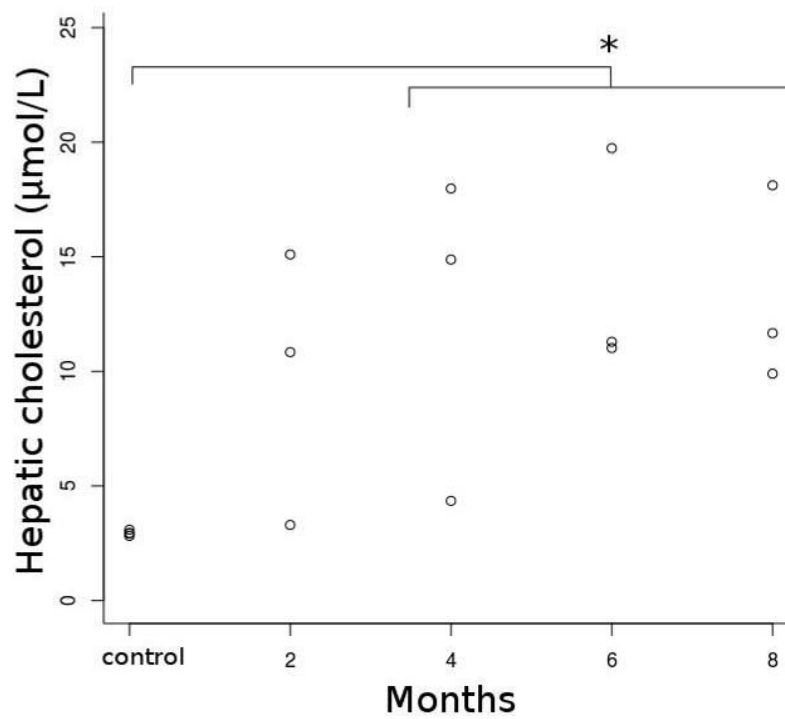


Figure 37: Hepatic cholesterol concentration over time, 4-8 months group significantly differed from controls (*).

For hepatic cholesterol concentrations, there were only significant differences between the control group and 4-8 months groups (Kruskal-Wallis test, $p<0.001$) (Figure 37). Arterial cholesterol concentrations linearly increased from control birds to the 8-month group (Figure 38) with a significant treatment effect ($F=31.74$, $p<0.001$) but no difference between arteries ($F=0.72$, $p=0.41$). One outlier was removed to have an adequate fit and validate model assumptions. The outlier was an aortic sample in the 6-month group that differed markedly from the brachiocephalic sample within the same bird (Figure 38). The variability in the pulmonary arterial samples was high due to the small quantity of artery that could be harvested and used in the assay and the values were not considered reliable, thus not included in the analysis. However, pulmonary arterial samples appeared to have less cholesterol than other elastic arteries with a median (interquartile range) of 23.17 (18.16) $\mu\text{mol/g}$. There was a significant moderate correlation between plasma cholesterol at euthanasia and atherosclerotic lesion type ($\tau=0.50$, $p<0.001$), arterial cholesterol ($\rho=0.64$, $p<0.001$) and a high correlation with liver cholesterol ($\rho=0.81$, $p<0.001$). Arterial cholesterol was highly correlated to the type of lesions ($\tau=0.80$, $p<0.001$).

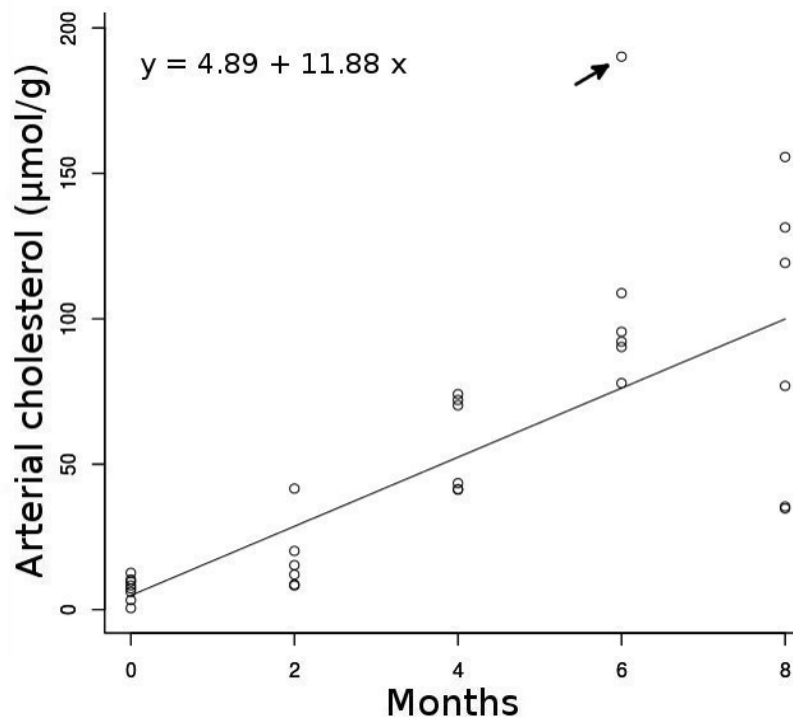


Figure 38: Arterial cholesterol concentration over time with a linear regression line (arrow: outlier).

On histopathologic examination of harvested arterial samples, the 4 control birds did not have any evidence of atherosclerotic changes in any artery. At 2 months on 1% cholesterol diet, one bird had atherosclerotic lesions of type III in the aorta and brachiocephalic arteries and type I lesion in the pulmonary arteries. The type III lesions were extensive, proliferative, diffuse,

encompassed the full circumference of the arteries, and displayed significant fibrosis as evidenced by the trichrome stain (Figure 39.A). The 2 remaining birds had type I lesions in the aorta and brachiocephalic arteries mainly characterized by mild ORO positive staining and scattered lipid vacuoles on toluidine blue stain but no evidence of lesion or lipid in the pulmonary arteries. At 4 months, all birds exhibited advanced lesions of type IV extending on the whole circumference of the aorta and brachiocephalic arteries and characterized by fatty proliferation, intense ORO staining, stenosis of the lumen, mild calcification (on von Kossa stain), and high but diffuse collagen expression (Figure 39.B and 39.C). Pulmonary arteries only displayed none to mild lesions of type 0-II. At 6 months, all birds had type IV-V lesions in the aorta and brachiocephalic arteries with a well-delimited lipid core, mild calcification, and the presence of a thin fibrous cap overlying the atheroma in one bird. Pulmonary arteries exhibited type II lesions in two birds and type I in one bird. At 8 months, 2 birds developed advanced lesions of type V with a fibrous cap and moderate calcification in some areas of the atheroma (Figure 39.D). Only the pulmonary arteries had mild lesions of type II. However, one bird only developed mild lesions despite 8 months on the atherogenic diet with type I-II lesions in the aorta and brachiocephalic arteries and no lesion in the pulmonary arteries.

Spontaneously-occurring lesions in 16 other Quaker parrots appeared more organized and the different areas of the fibroatheromas were better defined when compared to experimental lesions. Also, experimental lesions of type III-IV were more diffuse, vacuolated, and typically involved the entire circumference of the arteries whereas spontaneous lesions of these types were usually more circumscribed and less vacuolated. Finally, calcification was often more advanced in spontaneous lesions than in experimental lesions and chondroid metaplasia and ossification were not observed in the latter. Advanced lesions characterized as type V appeared histologically similar between spontaneous and experimental atherosclerosis in Quaker parrots.

No histological abnormalities, except coronary atherosclerotic lesions, were evident in the hearts of all 16 birds. Intramyocardial coronary arteries (15-20 per heart of approximately 40-250 μm in diameter) were evaluated. The birds in the control and 2 month groups did not develop any atherosclerosis in the coronary arteries. At 4 months, all birds had atherosclerotic changes mainly type III lesions but with complete obstruction of the arterial lumen in some coronary arteries by some type III-IV lesions. At 6 months, 2 birds had advanced type IV lesions, characterized by segmental arterial walls almost transmurally replaced by foamy cells and extracellular lipid, but no atherosclerotic lesions were observed in one bird. At 8 months, only one bird demonstrated coronary atherosclerotic lesions of type III. In the hepatic sections, prominent hepatocellular vacuolization was observed in two birds, one at 6 and one at 8 months.

On transmission electron microscopy, the normal intima showed a single layer of endothelial cells with various organelles, plasmalemmal vesicles, and short microvilli. The media was mainly composed of two types of cells: smooth muscle cells and fibroblast-like cells with an interlamellar location. Overall, extracellular fat accumulation seemed to precede the presence of foam cells. In type I lesions, foam cells were rare but extracellular lipid vacuoles were present throughout the intima and media. Some endothelial cells seemed to have more cytoplasm, filopodia, vacuoles, and Weibel-Palade bodies (that are spherical and granular in birds) than in control birds (Figure 40.A). In addition, a few monocytes were seen to adhere to endothelial cells in some sections. Some smooth muscle cells (SMC) showed phenotypic changes to a more synthetic state. There also seemed to be an increased number of fibroblasts. In type II-III lesions, there were moderate to large pools of extracellular lipid containing small and large lipid droplets, cholesterol crystals, cellular debris, myelin figures with disorganization of elastin and collagen

fibers and increased extracellular matrix. While lipid remained primarily extracellular, characteristic foam cells were present, mainly in type III lesions (Figure 40.B). The cellular origin of foam cells was difficult to determine based on morphology alone but both SMC and macrophage-derived foam cells were present. In the type IV-V atherosclerotic lesions, there was major disorganization of the arterial ultrastructure with large areas devoid of cells filled with lipid and extracellular matrix components, cellular debris and foam cells (Figure 40.C). The fibrous cap was composed of collagen, elastin fibers, and fibroblast-like cells (Figure 40.D). Large numbers of foam cells were present immediately underneath the fibrous cap.

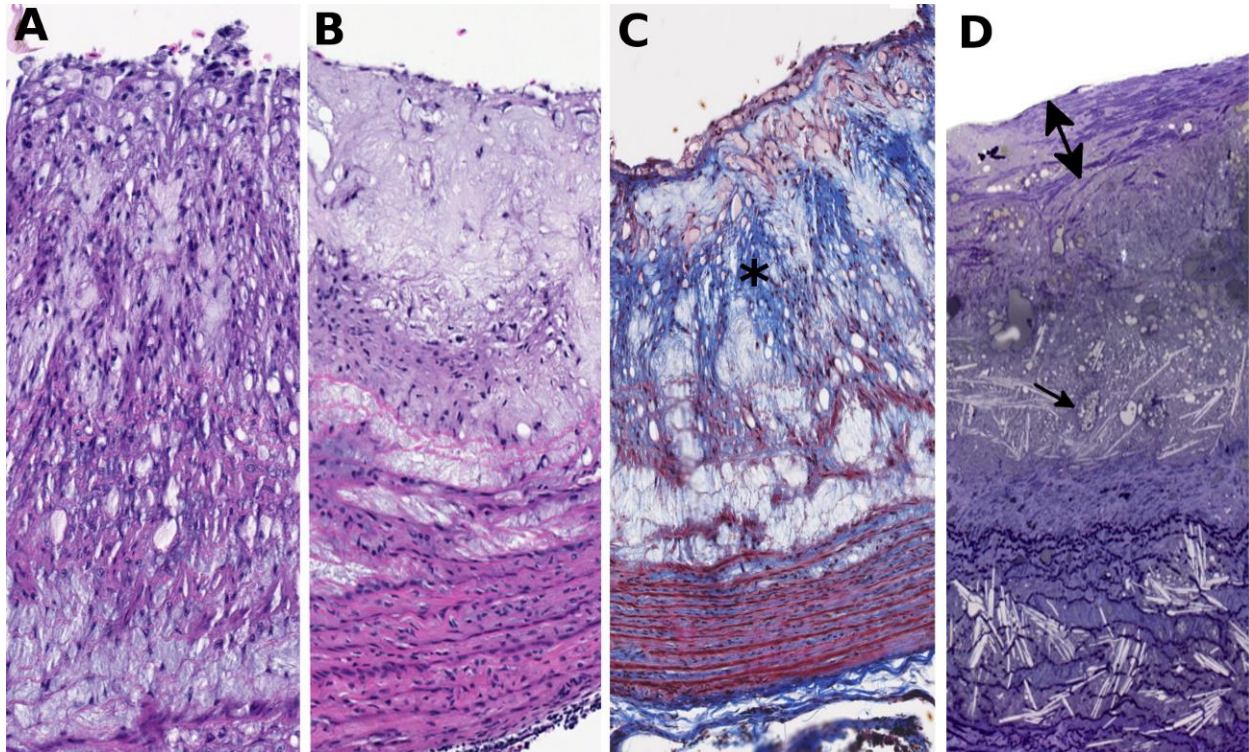


Figure 39: **A.** Photomicrograph of diet-induced atherosclerotic lesions in the brachiocephalic arteries in Quaker parrots. Proliferative type III lesions at 2 months (Hematoxylin and eosin, X 100). **B.** type IV lesion exhibiting a lipid core but not covered by a fibrous cap at 4 months. (Hematoxylin and eosin, X 100). **C.** type IV lesion showing blue staining for collagen (*) in the lipid core (Masson's trichrome, X 100). **D.** type V lesion similar to B and C but covered by a fibrous cap (double-headed arrow), cholesterol clefts are visible as well as foam cells (arrow) (Toluidine blue, X 100).

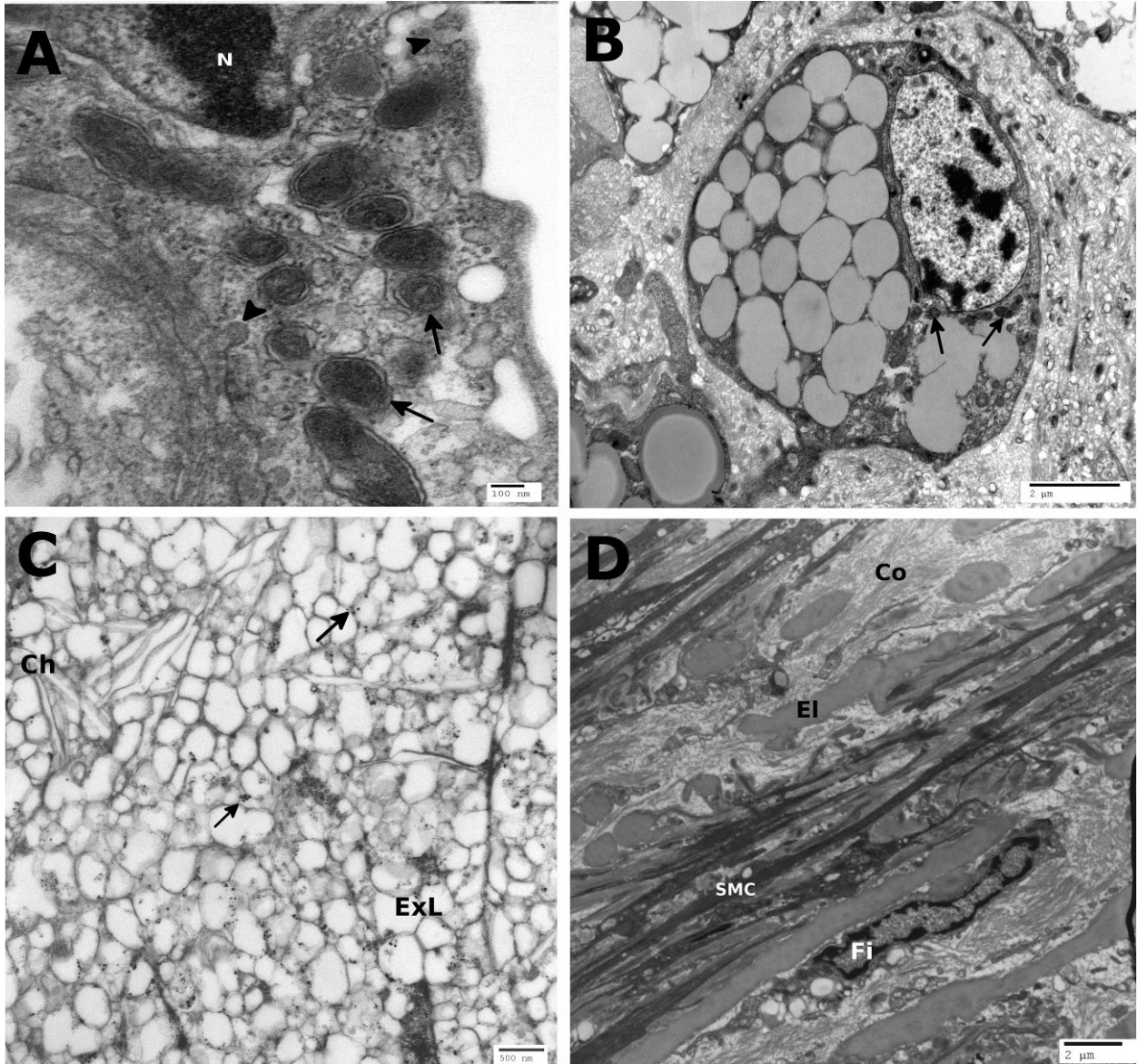


Figure 40: **A.** Electron-micrographs (Orcein-uranyl-lead stain). Cytoplasm of an endothelial cell exhibiting an increased number of Weibel-Palate bodies (arrows) and pinocytotic vesicles (arrowheads), type I lesion at 2 months. N, nucleus (X 80000). **B.** macrophage-derived foam cells with a few lysosomes (arrows), type V lesion at 6 months (X 9400). **C.** lipid core of a type IV lesion at 4 months composed of extracellular lipid (ExL), cholesterol crystals (Ch), and small calcium granules (arrows) (X 29000). **D.** fibrous cap in a type V lesion at 6 months composed of elongated smooth muscle cells (SMC), collagen (Co) and elastin (El) fibers, a fibroblast-like cell (Fi) is also visible (X 14000).

IV. Discussion

This study showed that atherosclerosis could be induced in Quaker parrots as early as 2 months with a 1% cholesterol diet. Moreover, advanced atherosclerotic lesions developed at 4 months and were characterized by a large circumferential lipid core and a fibrous cap. At 6

months, lesions appeared histologically analogous to spontaneous advanced lesions in the same parrot species and showed significant luminal stenosis. The chronology of lesion progression in the aorta and brachiocephalic arteries seemed to follow the previously established psittacine classification system with the type V lesions being only present at 6 and 8 months.(Beaufreire, Nevarez, et al. 2011) Coronary lesions also developed at 4 months but owing to the small sizes of these arteries (about 40-250 μm) in Quaker parrots, categorization of the lesions was less precise. Lesion severity and arterial cholesterol content increased linearly with time and both were significantly correlated to plasma cholesterol concentration. Pulmonary arteries displayed only mild to moderate lesions that never progressed to advanced lesions. This may have been influenced by the lower blood pressure of the vascular pulmonary system, but severe pulmonary lesions have been described in association with clinical signs in psittacine birds.(Sedacca et al. 2009) Spontaneous lesions appeared more organized, more calcified, and less diffuse than experimental lesions possibly reflecting the slow development of spontaneous lesions compared to the accelerated rate of experimental lesion formation. Different appearance of atherosclerotic lesions have also been noted in pigeons fed with different concentration of cholesterol.(Jerome & Lewis 1984) Atherothrombosis, plaque rupture, and cardiac ischemia were not encountered but it is possible that complicated lesions would have developed several months later. On the other hand, these complications are common in White Carneau pigeons.(Prichard et al. 1964; St Clair 1998) A recent experiment in budgerigars (*Melopsittacus undulatus*) revealed that in vivo carotid artery injury did not lead to the formation of occlusive thrombi contrary to mice in which carotid diameter and blood flow are similar to budgerigars.(Schmaier et al. 2011) Avian thrombocytes seem less capable of forming shear-resistant arterial thrombi and do not usually form 3-dimensional aggregates. The physiologic differences between avian thrombocytes and mammalian platelets may partly explain the clinical differences observed in the nature and prevalence of atherothrombotic diseases.

During this research investigation, the Quaker parrots also exhibited dyslipidemia with a shift from HDL to LDL as their main cholesterol-carrier lipoproteins. The dyslipidemia developed quickly and stabilized at about 3-4 months at which total and LDL cholesterol reached a plateau. This shift from lipoprotein profiles and similar levels of cholesterol were also observed in quails and pigeons after cholesterol feeding.(Ojerio et al. 1972; Barakat & St Clair 1985; Bavelaar & Beynen 2004b; Hammad et al. 1998; Inoue et al. 1995; Morrissey & Donaldson 1977) As with these parrots, change in plasma HDL is usually not observed in birds during cholesterol feeding.(Bavelaar & Beynen 2004b; Hammad et al. 1998; Barakat & St Clair 1985; Hermier & Dillon 1992; Radcliffe & Liebsch 1985; Jerome & Lewis 1985) Furthermore, the Quaker parrots displayed a high plasma CETP activity which, while not statistically significant, increased on the atherogenic diet. This enzyme transfers cholesteryl esters to LDL from HDL and an increase in its activity has been described with atherogenic dyslipidemia both in humans and animal experimental models.(Tall et al. 1987) The response to dietary cholesterol varies among species and individuals and different concentrations of this compound have been used (0.05-5%) in formulated bird diets to induce atherosclerotic lesions with variable severity, prevalence, and rate of development.(Bavelaar & Beynen 2004b; Inoue et al. 1995; Prichard et al. 1962; Shih et al. 1983) Within a same species, the induction of atherosclerosis depends on the line of birds, the level of dietary cholesterol, and the duration of the feeding period.(Shih et al. 1983; Bavelaar & Beynen 2004b; Inoue et al. 1995; Prichard et al. 1962) It appears from our study that advanced atherosclerotic lesions can be induced relatively quickly in Quaker parrots with 1% dietary cholesterol as all birds in the 2 months group had significant arterial lesions. In a previous study

in which another psittacine species was used, the budgerigar, significant atherosclerotic lesions were induced by feeding a diet that contained 2% cholesterol and 15% lard for 6 months. Not only did the budgerigar plasma cholesterol increase, but there was concurrent development of hepatic lipidosis.(Finlayson & Hirschinson 1961) A concentration of 0.5-1% is usually required to generate significant atherosclerotic lesions in a short timespan (months) but more physiological levels (0.15% cholesterol, Western-type diet) are also being used to better mimic the slow progression of the disease when time is not a constraint. Japanese quails have been particularly bred and selected to produce atherosclerosis rapidly with less dietary cholesterol.(Bavelaar & Beynen 2004b; Radcliffe & Liebsch 1985; Shih et al. 1983) Similar results may be achievable in Quaker parrots through selection to obtain a more homogenous population (variability was high here) which would allow the investigator to reduce the number of animals required to achieve statistically relevant results, cholesterol level, and time to induce atherosclerotic lesions. Other dietary modifications have been used in conjunction to cholesterol in avian models including increased saturated fat level and cholic acid supplementation, which induces an inflammatory state and aids in cholesterol absorption.(Bavelaar & Beynen 2004b; Radcliffe & Liebsch 1985) In our study, only the cholesterol content of the diet was altered and the formula was controlled for caloric and micronutrients intake to limit potential confounding factors of increased weight and fat reserve on metabolism, dilution of other nutrients, and to provide more reproducible dietary modifications. In addition, the inflammation induced by cholic acid can also be a confounding factor in itself.

Among avian models of atherosclerosis, histopathology and ultrastructural pathology have mainly been reported in white-Carneau pigeons and Japanese quails.(Jerome & Lewis 1984; Jerome & Lewis 1985; Lewis et al. 1985; Barr et al. 1991; Hansen 1977; Inoue et al. 1995; Shih et al. 1983) While parrots and quails principally develop lesions in the ascending aorta and brachiocephalic arteries, pigeons preferentially acquire lesions in the lower thoracic aorta, especially at the celiac bifurcation.(Bavelaar & Beynen 2004a; Jerome & Lewis 1984; Inoue et al. 1995) Spontaneous and experimental lesions in parrots, pigeons, and quails are similar to human lesions with the presence of foam cells, extra and intracellular lipid, a lipid core, a fibrous cap, and calcification.(Beaufriere, Nevarez, et al. 2011; St Clair 1998) Early lesions in pigeons are characterized by endothelial activation and monocyte adherence to the endothelium.(Jerome & Lewis 1984; Lewis et al. 1982; Lewis & Kottke 1977; Taylor & Lewis 1986) Endothelial changes noted in this study suggested endothelial activation and degeneration with adherent monocytes being observed in a few instances. In parrots, as in pigeons, SMC- and macrophage-derived foam cells are present in spontaneous and experimental lesions.(Beaufriere, Nevarez, et al. 2011; Hansen 1977; Lewis et al. 1985; Jerome & Lewis 1985) The large amount of extracellular lipid present in early lesions (type I-II) in the Quaker parrots contrasts with spontaneous early lesions in the same species of parrots that are primarily characterized by foam cells and intracellular lipids.(Beaufriere, Nevarez, et al. 2011) More characteristic foam cells were present in more advanced experimental lesions. Similar to pigeons, quails, and other birds but in contrast to mammalian species, interlamellar fibroblast-like cells were present in the media and may actively participate in fibrosis and synthesis of constituents of the extracellular matrix during atherogenesis.(Hansen 1977; Lauper et al. 1975; Yamamoto & Igawa 1991; Moss & Benditt 1970; Toda et al. 1984) As evidenced in lesions from parrots, remodeling with increased deposition of collagen is a hallmark of atherosclerotic lesion maturation and fibrous cap formation and is similar to other avian models.(Velleman et al. 2001; McCullagh & Ehrhart 1977)

Even if the advanced lesions seem identical between diet-induced and spontaneous atherosclerosis, the mechanisms of lesion formation and progression may differ owing to the compressed experimental time frame. Birds also have major differences in lipoprotein metabolism (absence of apolipoprotein B48, E, and chylomicrons, HDL as the main carrier lipoprotein, drastic changes during egg laying) and arterial microanatomy (no SMC in the intima, fibroblasts in the media) than humans.(Anderson et al. 2012) Nevertheless, all experimental models have limitations and even with animals more closely related to humans, some findings may not translate well to the human disease.(Libby et al. 2011) An example of this discrepancy, as observed in parrots, transgenic mice primarily develop lesions in the proximal great vessels and rarely get lesion complications.(Libby et al. 2011) Similarities in plasma biochemical changes, lesions composition, pathology, ultrastructure, and progression suggest that the pathogenesis of atherosclerosis in Quaker parrots is comparable to other avian models investigated and humans. Therefore, Quaker parrots could be used to study some aspects of the pathogenesis and therapeutics of atherosclerosis. The Quaker parrot is certainly a good model to study spontaneous atherosclerosis in psittaciformes which commonly develop atherosclerosis-related diseases under standard captive conditions and may share common risk factors with humans.

In conclusion, Quaker parrots may be a useful model of atherosclerosis for parrots and humans as this species is small, has low food consumption (10 g/day), and rapidly develops advanced atherosclerotic lesions with cholesterol feeding that resemble lesions found both in humans and other avian models. In addition, advanced lesions induced experimentally are similar to spontaneous-developing lesions within the same species.

CHAPTER IV: ESTIMATION OF INTRATHORACIC ARTERIAL DIAMETER BY MEANS OF COMPUTED TOMOGRAPHIC ANGIOGRAPHY IN HISPANIOLAN AMAZON PARROTS*

I. Introduction

Atherosclerosis is a common disease of aging parrots as suggested by results of retrospective pathologic surveys.(Braun et al. 2002; Krautwald-Junghanns et al. 2004; Bohorquez & C. Stout 1972; Pilny 2004; Garner & Raymond 2003; Fricke et al. 2009) The disease is characterized by the thickening of arterial walls through lipid accumulation and plaque formation in the tunica intima, ultimately resulting in arterial luminal stenosis of the great vessels.(Fricke et al. 2009; Bavelaar & A. C. Beynen 2004a) Atherosclerosis can also lead to arterial aneurysms in pet birds.(Vink-Nooteboom et al. 1998)

Birds are susceptible to diet-induced and spontaneous atherosclerosis.(Bavelaar & Beynen 2004a) Spontaneous atherosclerosis in pet psittacine birds typically develops in older birds fed a nutritionally unbalanced diet, with risk factors similar to those described for human atherosclerosis.(Krautwald-Junghanns et al. 2004; Bavelaar & Beynen 2004a) Parrots can develop a central form of atherosclerosis, in which the great vessels at the base of the heart are most commonly affected.(Krautwald-Junghanns et al. 2004; Fricke et al. 2009; Bavelaar & Beynen 2004a; Oglesbee & Oglesbee 1998) Antemortem diagnosis of atherosclerosis in these birds has been considered difficult and remains one of the challenges of avian medicine. Only advanced cases of disease with considerable calcification of the great vessels or with secondary heart changes can be diagnosed.(Mans & Brown 2007; Phalen et al. 1996; Sedacca et al. 2009; Shrubsole-Cockwill et al. 2008)

Clinical antemortem diagnostic imaging of atherosclerosis in humans includes the use of various modalities of vascular imaging that mainly involve angiographic techniques through the use of high-speed CT scan and magnetic resonance imaging.(Sanz & Fayad 2008) The main site of arterial stenosis in people is the carotid arteries, and CTA is the principal imaging method to measure carotid diameters and quantify stenosis.(Bartlett et al. 2007) Whereas angiography appears to be used in birds, no studies have been conducted to evaluate an angiography protocol in detail and to determine the apparent diameter of intrathoracic arteries in healthy companion birds. The purpose of the study reported here was to establish a CT angiography protocol and provide reference limits for cross-sectional measurements of the great arteries in Hispaniolan Amazon parrots (*Amazona ventralis*).

* This chapter originally appeared as Beaufre, H. et al., 2011. Estimation of intrathoracic arterial diameter by means of computed tomography angiography in Hispaniolan Amazon parrots. *Am J Vet Res*, 72(2), pp 210-218. Reprinted with permission of the American Veterinary Medical Association.

II. Materials and methods

A. Animals

Thirteen Hispaniolan Amazon parrots were included in the study. Birds were considered healthy on the basis of results of physical examination and a recent CBC. The parrots did not have any clinical signs of cardiovascular disease such as lethargy, anorexia, abdominal distention, or dyspnea prior to the study. They were obtained from a research colony maintained at the Louisiana State University and were fed a pelleted diet (Kaytee Exact Rainbow, Chilton, WI). The study protocol was approved by the Louisiana State University Institutional Animal Care and Use Committee.

B. Cardiological evaluation

All birds were screened for cardiac diseases, with echocardiography performed and ECGs obtained while birds were anesthetized with isoflurane. Echocardiography was performed following the transcoelomic approach, (Pees & Krautwaldjunghanns 2005; Pees, Krautwald-Junghanns, et al. 2006; Pees et al. 2004) with an ultrasonographic probe (S12-4 sector array transducer, Philips Healthcare, Andover, MA) connected to an ultrasonography system (IE 33, Philips Healthcare, Andover, MA). Morphometric measurements of the left ventricles were obtained with the inner edges method in the vertical view and aortic diameter in the longitudinal view; aortic outflow velocity was measured by use of spectral Doppler technology. All measurements were compared with published reference limits for Amazon parrots. (Pees & Krautwald-junghanns 2005; Pees, Krautwald-Junghanns, et al. 2006; Pees et al. 2004) The right ventricle was not measured in consideration of its relatively small size in this smaller species of Amazon parrots, lack of detail, and inability to obtain accurate measurements. Electrocardiograms were obtained via an anesthetic monitor (Vetspecs VMS7, VetSpecs Inc, Canton, GA), recorded at 100 mm/s with a gain of 10 mm equal to 0.5 mV, and printed via manufacturer software. Measurements were obtained from the recordings and compared with published reference limits for Amazon parrots. (Nap et al. 1992)

C. CTA procedures

Each parrot was positioned in dorsal recumbency, and anesthesia was induced via face mask with 5% isoflurane in oxygen at an oxygen flow rate of 0.8 L/min. The parrot was then intubated with an uncuffed endotracheal tube, and anesthesia was maintained with 2% to 3% isoflurane. Supplemental heat was provided by a heating pad and forced warm air (Bair Hugger, Arizant Inc, Prairie, MN). A 24- or 26-gauge catheter was placed in the left ulnar vein (n = 10 parrots), right ulnar vein (2), or medial metatarsal vein (1). An injection plug was placed at the end of the catheter, and the catheter was secured in place with an adhesive bandage. A 1-mL syringe containing the contrast medium was connected to the catheter by a 22-gauge butterfly catheter. The CTA examinations were performed with a 16-detector-row CT scanner (Light Speed GE Healthcare, Milwaukee, WI). Whole-body scout scans were performed in orthogonal planes. A survey examination was performed before contrast medium administration (precontrast) by use of a built-in abdominal scan protocol with the following parameters: standard algorithm in helical scan mode, 1.25-mm slice thickness, 1.375 pitch, 100 kVp, and 150 mA. The scan area of interest extended from the last cervical vertebra just cranial to the coracoid bone and continued caudally to the coxofemoral joint. A dynamic CT scan was performed at the level of the abdominal aorta dorsal to the proventriculus and began 3 seconds before an initial manual bolus injection of iohexol (Omnipaque 240 mg/ml, GE Healthcare Inc, Princeton, NJ) (1 mL/kg),

which was administered over 1 second. The person manually injecting the contrast medium was positioned behind a mobile lead x-ray shield.

When precontrast survey scans were completed, CTA was performed with the same scan parameters but with a manual injection of 3 mL of iohexol/kg over 3 seconds, administered 3 seconds prior to initiation of CTA. Additional reconstruction series at 0.625 mm and bone algorithm were performed. Dynamic scans allowed time of arrival of contrast medium to the abdominal aorta (time to enhancement peak) to be determined.

D. ROI measurements

The attenuation coefficient (in HU) was obtained for each vessel including the 2 brachiocephalic trunks, the aorta, and the 2 pulmonary arteries to quantify the amount of contrast medium present in these arteries. Circular ROIs corresponding to the cross-sectional area of all the major arteries before and after contrast administration were obtained. The circular measurement tool gave the area of the ROI from which the diameter (D) was calculated with the following formula:

$$D = 2(\text{area}/\pi)^{1/2}$$

A pulmonary window (width, 1,400 HU; level, -500 HU) was used for pre- and postcontrast measurements (Figure 41). Additional windows used for ROI measurements made after contrast agent administration (postcontrast) included a mediastinal window (width, 350; level, 50) and an angiography window, with the window level determined from the mean contrast attenuation coefficient in the 6 measured arteries and the window width determined by calculating the following ratio: window width/window level = 2. The ratio used was derived from the following formula:

$$W/AC = (3.3 \times L/AC) - 1.3$$

in which W is the window width, AC is the attenuation coefficient, and L is the window level used (L = mean AC of vessels for this protocol). This formula was obtained from a previously reported CTA study (Liu et al. 2000) on phantom arteries of various sizes, which was conducted to determine optimum CT levels and windows. Regions of interest were obtained as the largest circle that would encompass the outermost outline of the arteries before contrast medium administration and the outermost outline of the contrast boundary after administration (Figure 42). For precontrast measurements, the unsharp edges of the arteries were included in the measurements, whereas for postcontrast measurements, such edges were not included to obtain luminal diameters and minimize inaccuracy due to blooming and penumbra artifacts caused by the contrast medium and algorithm used, respectively. The left and right brachiocephalic trunks were measured at the same level as they laterally crossed the cranial thoracic cavity. The ascending aorta was measured at the middle of its ascending course. The abdominal aorta was measured prior to the bifurcation of the mesenteric artery. The left and right pulmonary arteries were measured at the middle of their ascending course to the lungs.

Ratios were also calculated with the length of the keel bone and length of the vertebral body at the coracoid-keel junction as obtained via a bone window. Two observers participated in ROI measurements. Observer 1 (the radiologist) obtained all measurements twice on different days to evaluate intraobserver agreement (reproducibility) of the measurement techniques. Additionally,

observer 2 (the clinician) obtained measurements to evaluate interobserver agreement. Outlining of ROIs, linear measurements, and 3-D reconstruction (segmentation and volume rendering) of the heart and great vessels were performed with a commonly used and calibrated imaging program (OsiriX Imaging Software, version 3.5.1, OsiriX Foundation, Geneva, Switzerland. Available at: www.osirix-viewer.com). Cross-sectional images were magnified at 300% to improve accuracy of measurements.

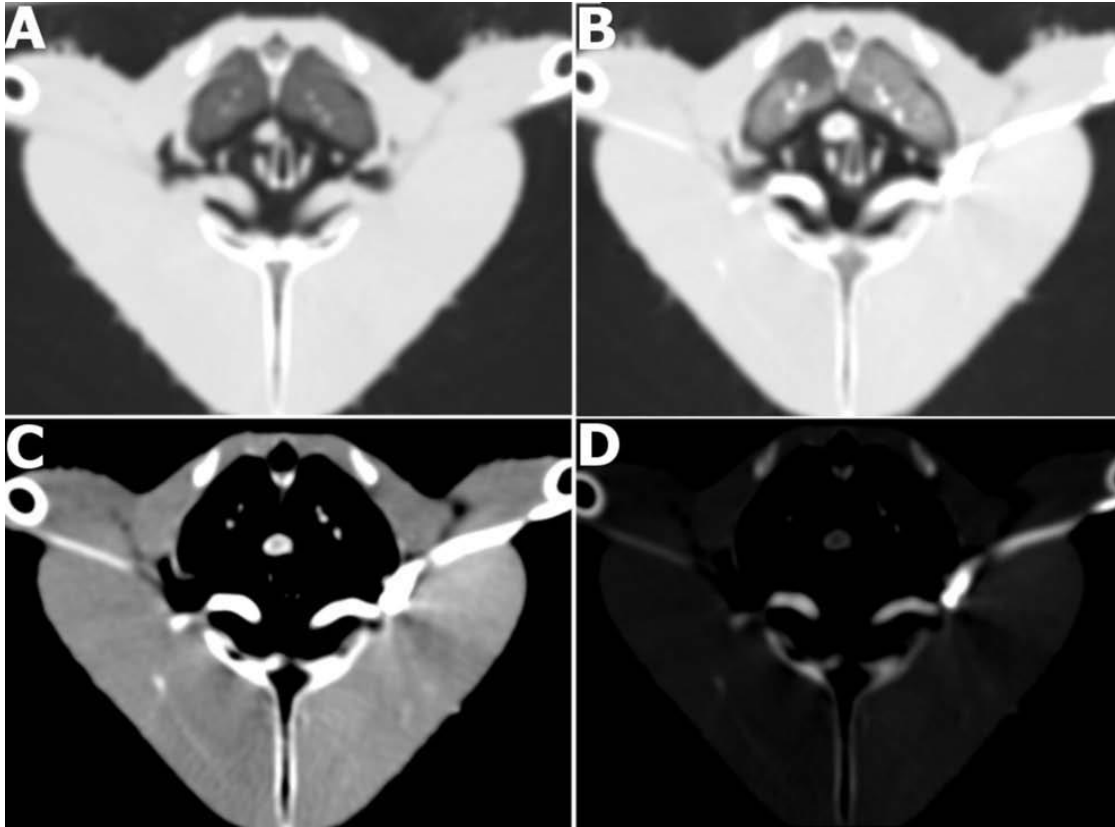


Figure 41: Computed tomography angiography scan of a healthy Hispaniolan Amazon parrot obtained at the level of the brachiocephalic trunks in a pulmonary window (A) before contrast medium administration and in a pulmonary window (B), mediastinal window (C), and manually selected angiography window (D) after administration.

E. Statistical analysis

Analyses were performed by use of the same computer software (SAS, version 9.1.3, SAS Institute Inc, Cary, NC), except where indicated. Data were tested for normality with a Shapiro-Wilk test, with a value of $P < 0.05$ indicating a nonnormal distribution. Results are reported as mean \pm SD when the data were normally distributed and as median (range) when they were not. Univariate summary statistics were calculated to report echocardiographic measurements, CT artery diameters, and ratios. Reference limits were determined as the central 95% of the values (ie, the mean \pm 2 SD) for normally distributed data and the interval between the 2.5th and 97.5th percentiles for non-normally distributed data.

For CTA measurements, with measurements of the various arteries considered dependent variables, differences between the means of these measurements with and without contrast

medium administration, with the various CT windows, and between observers were assessed by means of ANOVA on the ranked value blocked for individual birds. Multiple post hoc comparisons were performed with the Tukey and the least squares means methods. The Wilcoxon matched-pairs signed rank test was used to assess differences between the means of the diameters of the 2 brachiocephalic trunks, the 2 pulmonary arteries, and the 2 consecutive measurements by the same observer (the radiologist).

Spearman rank correlation coefficients (ρ) were calculated to assess the correlation between the sizes of the various arteries and with the parrot body weight overall and for each CT window. A correlation was considered strong when the coefficient was > 0.5 and weak when ≤ 0.5 . Intraobserver agreement (reproducibility) between 2 consecutive measurements was evaluated by calculating concordance correlation coefficients for each artery. (Lin 1989) Reproducibility was considered high when the coefficient value was ≥ 0.76 , medium when between 0.40 and 0.75, and low when ≤ 0.39 . Interobserver agreement between the radiologist and clinician was evaluated by calculating ICC coefficients (SPSS, version 16.0, SPSS Inc, Chicago, IL). (Shrout & Fleiss 1979) The 2-way, random, single-measure reliability ICC for absolute agreement and 95% CIs were determined for each artery. Interobserver agreement was considered high when the coefficient value was ≥ 0.76 , medium when between 0.40 and 0.75, and low when ≤ 0.39 . Values of $P < 0.05$ were considered significant for all analyses.

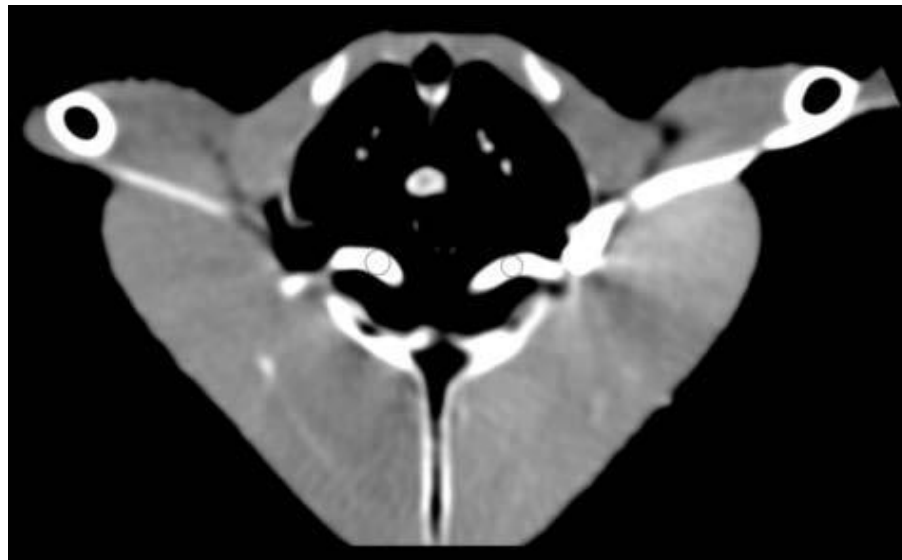


Figure 42: Computed tomography angiography scan of a Hispaniolan Amazon parrot obtained at the level of the brachiocephalic trunks in a mediastinal window. Circular ROIs (circles) were used to measure the diameters of the right and left brachiocephalic trunks.

III. Results

A. Cardiological evaluation

The 13 Hispaniolan Amazon parrots had a mean \pm SD body weight of 290.5 ± 21.2 g. No cardiac abnormalities were detected nor were any clinically important arrhythmias identified on ECGs. All ECG measurements were within reference limits reported for Amazon parrots. (Nap et al. 1992) No echocardiographic reference limits are available for the *A ventralis*, which is a smaller species of the genus *Amazona*, so published reference limits were used for the genus

Amazona, which were obtained from 4 larger species of Amazon parrots (*Amazona amazonica*, *Amazona aestiva*, *Amazona ochrocephala*, and *Amazona viridigenalis*). (Pees et al. 2004) Compared with those reference limits, some echocardiographic measurements (left ventricular width in diastole, left ventricular width in systole, and left ventricular length in systole) were slightly lower. No abnormalities in cardiac shape and function were detected via echocardiography. Therefore, on the basis of aforementioned results, the 13 parrots were considered free of detectable cardiovascular diseases.

Mean \pm SD echocardiographic measurements were as follows: left ventricular width in diastole, 5.60 ± 1.21 mm; left ventricular length in diastole, 20.1 ± 2.46 mm; left ventricular width in systole, 4.22 ± 0.93 mm; left ventricular length in systole, 18.26 ± 2.82 mm; aortic root diameter, 3.35 ± 0.39 mm; aortic outflow velocity, 75.46 ± 15.75 cm/s; left ventricular width-to-length ratio in diastole, 0.28 ± 0.08 ; left ventricular width-to-length ratio in systole, 0.23 ± 0.05 ; and left ventricular fractional shortening, $24.03 \pm 12.79\%$.

B. CTA

With the dynamic axial CT, the enhancement peak in the abdominal aorta ranged from 0.5 to 2 seconds after contrast medium administration (Figure 43). The CTA scans obtained through helical CT acquisition were of good quality and diagnostic value. The mean \pm SD attenuation coefficients of the left and right brachiocephalic trunks, the ascending aorta, and the abdominal aorta were 366 ± 129 HU, 404 ± 193 HU, 332 ± 101 HU, and 253 ± 123 HU, respectively. Median (range) attenuation coefficients in the left and right pulmonary arteries were 260 (89 to 849) HU and 259 (103 to 847) HU, respectively. For comparison, the attenuation coefficient of soft tissue is 20 to 50 HU.

Administration of contrast medium considerably enhanced visualization of the major arteries in various window settings (Figures 41 and 44), particularly the smaller diameter arteries such as the carotid arteries and the abdominal aorta. Three-dimensional reconstruction of the heart and central vasculature by means of segmentation and volume rendering techniques was also possible with CTA (Figure 45). No adverse effects were observed in the parrots during or after contrast administration.

C. ROI measurements

All arterial diameters were considered as apparent arterial diameters because of the lack of gold standard for arterial diameter measurements in birds and the likelihood of motion artifacts. All measurements made before and after contrast medium administration at the various window settings (pulmonary, mediastinal, and angiography) were normally distributed with the exception of the measurements of the left brachiocephalic trunk via the angiography window. Reference limits for the length of the 6 measured arteries were summarized (Table 30). For these arteries,

there were significant (all $P < 0.005$) differences between the means of arterial measurements made before (precontrast) and after (postcontrast) contrast medium administration and via the various windows. In descending order, the largest apparent arterial diameters were observed precontrast, postcontrast via the pulmonary window, postcontrast via the mediastinal window, and postcontrast via the angiography window.

Ratios between the diameters of the major arteries with the keel length and with the vertebral body length were also determined (Tables 31 and 32).

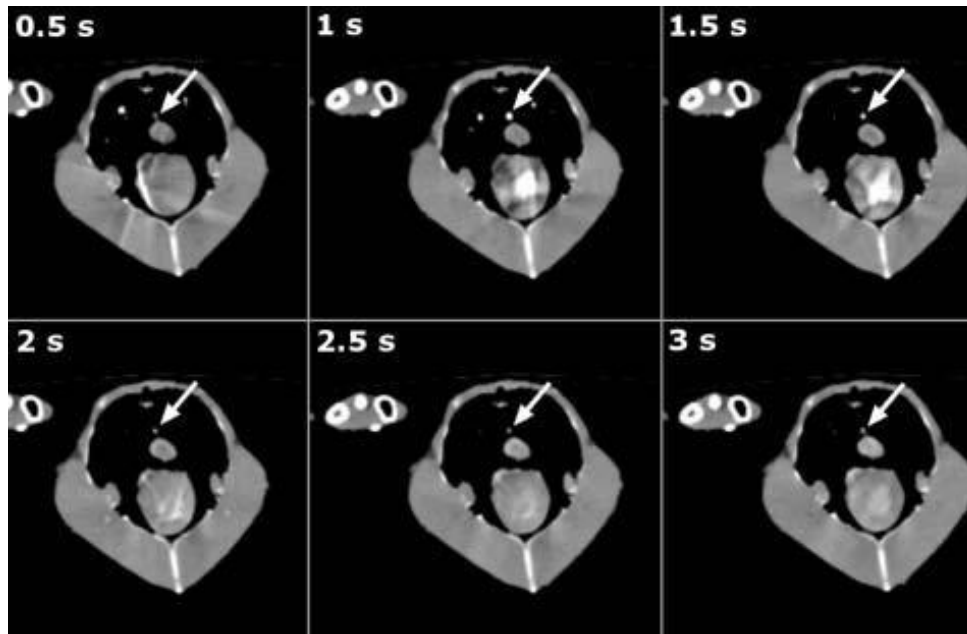


Figure 43: Dynamic axial CTA scan of a Hispaniolan Amazon parrot obtained at the level of the abdominal aorta at various points after administration of contrast medium. The contrast enhancement of the abdominal aorta (arrows) is seen over time with the enhancement peak at 1 second.

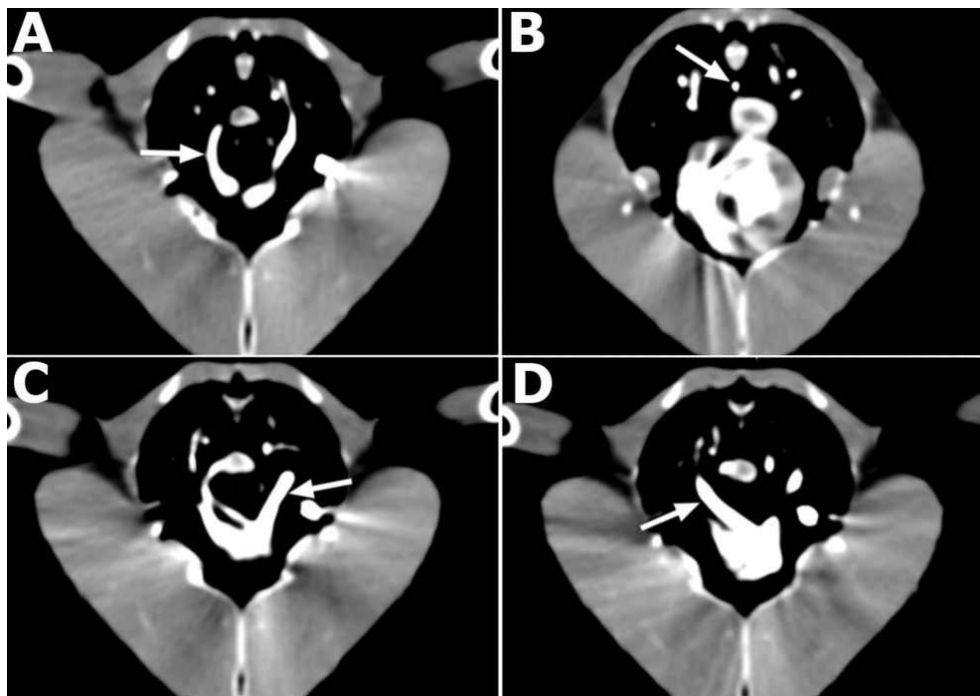


Figure 44: Computed tomography angiography scan of a Hispaniolan Amazon parrot showing the ascending aorta (arrow; A), abdominal aorta (arrow; B), left pulmonary artery (arrow; C), and right pulmonary artery (arrow; D).

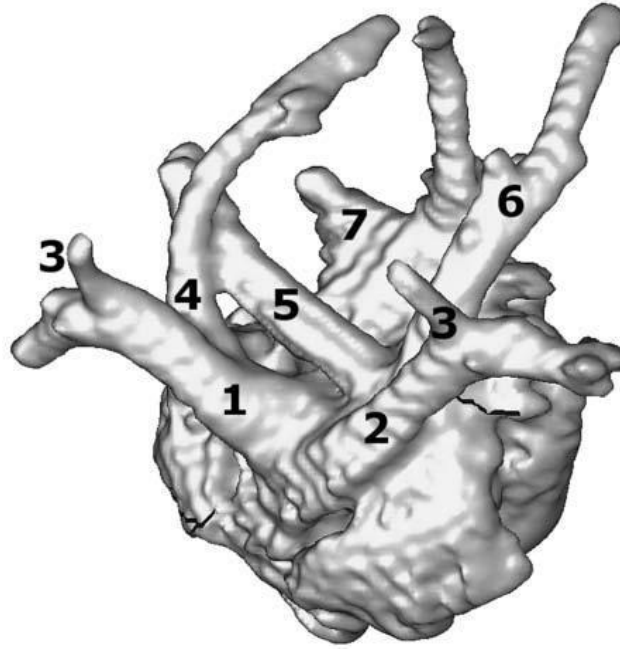


Figure 45: Diagram of the 3D segmentation of the heart of a Hispaniolan Amazon parrot as obtained via segmentation and volume rendering techniques made possible by CTA. The image is oriented to display a cranial view of the base. 1, right brachiocephalic trunk; 2, left brachiocephalic trunk; 3, carotid arteries; 4, ascending aorta; 5, right pulmonary artery; 6, left pulmonary artery; 7, pulmonary veins.

Table 30: Reference limits for apparent diameters (mm) of the major arteries of 13 Hispaniolan Amazon parrots as measured via CTA before and after contrast medium administration and via various windows. PreC, pre-contrast measurements; PostC, post-contrast measurement; RI, reference interval; LB, left brachiocephalic trunk; RB, right brachiocephalic trunk; AO, ascending aorta; AA, abdominal aorta; LP, left pulmonary artery; RP, right pulmonary artery.

Pre- and post-contrast values are reported as mean \pm SD. *Data for this circumstance were not normally distributed; therefore, median is reported.

Reference intervals for normally distributed data were calculated as mean \pm 2SD. Intervals for nonnormally distributed data represent the 2.5th and 97.5th percentiles.

Artery	Pulmonary window				Mediastinal window		Angiography window	
	PreC	RI	PostC	RI	PostC	RI	PostC	RI
LB	3.2 \pm 0.3	2.5-3.8	2.7 \pm 0.4	2.0-3.5	2.4 \pm 0.3	1.8-3.1	2*	1.7-2.9
RB	3.5 \pm 0.3	3.0-4.0	2.9 \pm 0.4	2.1-3.6	2.5 \pm 0.3	1.8-3.1	2.2 \pm 0.3	1.5-2.7
AO	2.5 \pm 0.2	2.0-2.9	2.2 \pm 0.4	1.3-3.4	1.9 \pm 0.3	1.3-2.5	1.7 \pm 0.3	0.9-2.3
AA	2.3 \pm 0.2	1.8-2.7	1.9 \pm 0.3	1.4-2.5	1.5 \pm 0.4	0.8-2.2	1.3 \pm 0.1	1.0-1.6
LP	2.5 \pm 0.3	1.7-3.2	2.4 \pm 0.3	1.9-3.0	1.9 \pm 0.2	1.4-2.3	1.6 \pm 0.3	1.0-2.1
RP	2.3 \pm 0.3	1.7-2.9	2.4 \pm 0.2	2.0-2.8	1.9 \pm 0.3	1.3-2.5	1.6 \pm 0.4	0.9-2.3

Table 31: Reference limits for keel-to-apparent arterial diameter ratio of the major arteries of 13 healthy Hispaniolan Amazon parrots as measured via CTA before and after contrast medium administration and via various windows. KL, keel length. See table 30 for remainder of key.

Artery	Pulmonary window				Mediastinal window		Angiography window	
	PreC	RI	PostC	RI	PostC	RI	PostC	RI
LB:KL	0.13±0.01	0.10-0.16	0.11±0.02	0.08-0.14	0.10±0.01	0.07-0.13	0.08*	0.07-0.12
RB:KL	0.14*	0.13-0.17	0.08±0.15	0.08-0.15	0.07±0.13	0.07-0.13	0.08*	0.07-0.11
AO:KL	0.10*	0.08-0.11	0.05±0.12	0.05-0.12	0.05±0.10	0.05-0.10	0.07±0.01	0.04-0.09
AA:KL	0.09*	0.08-0.10	0.08*	0.06-0.09	0.06*	0.04-0.08	0.06*	0.04-0.06
LP:KL	0.10±0.02	0.06-0.13	0.10±0.01	0.07-0.12	0.07*	0.07-0.09	0.06±0.01	0.04-0.09
RP:KL	0.10±0.01	0.07-0.12	0.10±0.01	0.07-0.12	0.08±0.01	0.05-0.10	0.07±0.01	0.04-0.09

Table 32: Reference limits for vertebral body-to-apparent arterial diameter ratio of the major arteries of 13 healthy Hispaniolan Amazon parrots as measured via CTA before and after contrast medium administration and via various windows. VL, vertebral body length. See table 30 for remainder of key.

Artery	Pulmonary window				Mediastinal window		Angiography window	
	PreC	RI	PostC	RI	PostC	RI	PostC	RI
LB:VL	0.67±0.07	0.53-0.82	0.58±0.09	0.40-0.76	0.52±0.07	0.37-0.66	0.41*	0.36-0.63
RB:VL	0.75±0.07	0.60-0.90	0.61±0.08	0.44-0.78	0.53±0.08	0.37-0.68	0.46±0.07	0.32-0.61
AO:VL	0.52±0.06	0.41-0.64	0.47±0.09	0.28-0.66	0.40±0.07	0.25-0.55	0.35±0.08	0.19-0.50
AA:VL	0.49±0.05	0.40-0.58	0.42±0.06	0.30-0.54	0.33±0.08	0.16-0.49	0.27±0.04	0.20-0.35
LP:VL	0.50±0.07	0.37-0.68	0.51±0.07	0.35-0.68	0.41±0.06	0.30-0.49	0.35±0.06	0.22-0.46
RP:VL	0.49*	0.42-0.67	0.51±0.07	0.36-0.65	0.41±0.06	0.28-0.53	0.35±0.06	0.22-0.48

For the 13 parrots, internal marker lengths were normally distributed and were 24.6 ± 0.5 mm for the keel and 4.6 ± 0.3 mm for the vertebral body. When the effects of contrast medium administration and window settings were not considered, there was no significant ($P = 0.219$) difference between the diameters of the left and right pulmonary arteries but there was a significant ($P < 0.001$) difference between the diameters of the left and right brachiocephalic

trunks, with the right being larger. When controlling for the effect of contrast medium administration and window settings, there was no difference between the left and right pulmonary arteries (all $P > 0.096$). There was also no difference between the diameters of the left and right brachiocephalic trunks (all $P > 0.088$) except for the precontrast diameter values, with values for the right being significantly ($P = 0.002$) larger than for the left. Body weight was not correlated with diameter of the major arteries overall and within window settings (all $P > 0.05$). However, when the presence of contrast medium and the window settings were not taken into account, strong associations were detected between the diameters of the major arteries (all $P < 0.001$; all $\rho > 0.65$). When considering the presence of contrast medium and the window settings, there was a strong correlation between the diameters of the 2 brachiocephalic trunks and between both brachiocephalic trunks and the ascending aorta in the pulmonary ($P < 0.014$; $\rho > 0.66$) and mediastinal windows ($P < 0.023$; $\rho > 0.62$) and only between the diameters of the 2 brachiocephalic trunks but not between both brachiocephalic trunks and the ascending aorta in the precontrast ($P = 0.029$; $\rho = 0.6$) and angiography ($P = 0.007$; $\rho = 0.7$) windows. The diameters of the left and right pulmonary arteries were strongly correlated in all settings except the mediastinal window ($P < 0.037$; $\rho > 0.6$). Correlation patterns were similar for the calculated ratios. The means of measurements made by 2 observers (the radiologist and clinician) did not differ significantly (all $P > 0.072$), except for those of the left brachiocephalic trunk ($P = 0.047$) in which the clinician had larger values than the radiologist. Similarly, no significant (all $P > 0.588$) differences were evident between the means of 2 consecutive measurements by the same observer (the radiologist). Intraobserver agreement (reproducibility) was high, with all concordance correlation coefficients > 0.95 (Table 33). Interobserver agreement was high for measuring diameters of the brachiocephalic trunks, the ascending aorta, and the abdominal aorta and was medium for the pulmonary arteries. Results of the reliability assessment were similar for the calculated ratios.

Table 33: Intraobserver agreement (reproducibility) for a clinician and interobserver agreement between a radiologist and clinician for arterial CTA measurements in 13 Hispaniolan Amazon parrots. CCC, concordance correlation coefficient; ICC(2,1), 2-way, random, single-measure reliability ICC coefficient for absolute agreement comparing the clinician's measurements with those of the radiologist.

Artery	CCC		ICC (2,1)		P value
	Correlation	95% CI	Correlation	95% CI	
LB	0.98	0.97-0.99	0.75	0.58-0.86	<0.001
RB	0.99	0.98-0.99	0.89	0.81-0.93	<0.001
AO	0.96	0.93-0.98	0.76	0.62-0.86	<0.001
AA	0.95	0.93-0.98	0.84	0.73-0.90	<0.001
LP	0.97	0.95-0.99	0.65	0.46-0.78	<0.001
RP	0.99	0.98-1.00	0.71	0.56-0.83	<0.001

IV. Discussion

In the study reported here, a protocol for CTA and reference limits for apparent luminal arterial diameters and ratios were developed for Hispaniolan Amazon parrots. On the basis of our findings, we recommend performing a dynamic axial CT with a test bolus consisting of 25% of the total contrast medium dose (ie, 1 mL/kg of a total dose of 4 mL/kg) to ensure the catheter is

correctly located and determine the time delay to be used during angiographic scanning. A helical CT angiography scan can then be performed with the time delay obtained from the previous test bolus technique, and the remaining dose of contrast medium (ie, 75% or 3 mL/kg) can be administered. We chose manual injections rather than an automated injection synchronized with the CT machine because of poor results obtained with previous attempts, which were probably attributable to the small injection volume and the 3-second delay between activation of the pump and the start of the scan.

The CTA method described here appears safe and of potential diagnostic value as demonstrated by the adequate amount of contrast present in the major arteries. Although adequate visualization of the major arteries was obtained with nonenhanced CT, in particular for the brachiocephalic trunks with a pulmonary or bone window, visualization was greatly improved with the angiography procedure in several window settings. Furthermore, CTA allowed evaluation of smaller diameter arteries, assessment and measurement of the apparent arterial lumens, and 3-D reconstruction and segmentation of the heart and central vasculature, thereby enhancing its diagnostic value.

The interval to enhancement peak in the aorta was fast and just a few seconds from the initiation of contrast medium administration. This interval is considerably longer in humans and dogs, with means varying between 25 to 45 seconds.(Awai et al. 2004; Lee et al. 2007) It depends on many factors such as the type of contrast medium and the duration and rate of injection. (Awai et al. 2004; Lee et al. 2007) However, considering the fast circulation of contrast medium in the avian vascular system, it would be difficult to confirm the influence of any of these factors.

Arterial measurements were window-dependent in the present study; therefore, we recommend using window-specific reference limits when evaluating the apparent luminal diameter of the major arteries in Hispaniolan Amazon parrots. We recommend measuring the arteries via a mediastinal or angiography window, which eliminates penumbra and blooming (blurring) of the arteries and provides better delineation of the contrast medium. Overall, the diameters of the brachiocephalic trunks and pulmonary arteries on one side were not significantly different than those on the other side, and there was a positive correlation between the arterial diameters of both sides. Use of ratios may prove beneficial in the extrapolation of these results to psittacine

species of various sizes, particularly other Amazon parrot species. The measurement method involving circular ROI measurements at the described arterial locations had medium to high reliability as suggested by high intra-observer agreement and medium to high interobserver agreement.

The accuracy of CTA is considerably affected by the attenuation coefficient of contrast material within the vessel, the window settings used for measurement, and the arterial inner diameter.(Liu et al. 2000; Claves et al. 1997; Suzuki et al. 2004) Several studies have involved use of vascular models (phantoms) to determine the most accurate settings for measuring arterial luminal diameters and subsequently quantifying degrees of arterial stenosis. For example, the angiography window formula used in our study yielded the most accurate CTA measurements on phantom arteries of various diameters.(Liu et al. 2000) In another phantom study,(Claves et al. 1997) results suggested that measurement inaccuracy increases with attenuation coefficients < 150 or > 250 HU. However, a different phantom study (Suzuki et al. 2004) involving automated software revealed that measurement errors decrease as densities of intravascular contrast medium increase, with the least measurement error obtained when a high-density vascular model of 460

HU is used. In the study reported here, attenuation coefficients for the arteries after contrast administration were high (overall mean \pm SD, 333 ± 167 HU). The fast heart rate and circulation of contrast medium in the vascular system of birds might limit the ability to obtain a predetermined attenuation coefficient in the selected arteries. Moreover, greater contrast enhancement may be needed to adequately visualize the small arteries of psittacine species. Our study has some limitations. First, the major arteries at the base of the heart move with heart beat, which may induce considerable motion artifacts during sequence acquisition, possibly decreasing accuracy of the diameter measurements. Changes in arterial diameters and positions likely occur during the cardiac cycle and could potentially lead to differences in measurements performed in the present study. In addition, the small size of the study birds limited visualization of the smaller arteries such as the carotid arteries cranially, the mesenteric artery, and other branches of the brachial arteries and the abdominal aorta. Furthermore, all manual measurements involved some degree of subjectivity. Automated software for CTA is available and may provide more objectivity in arterial measurements. Its usefulness has been investigated in a phantom study.(Suzuki et al. 2004) Finally, the reference limits created through our study have not been evaluated in diseased birds; therefore, the potential of CTA in the diagnosis of vascular conditions remains unknown. Several case reports of birds with central atherosclerosis have described the presence of stenosis or narrowing of arterial lumens. A substantial luminal narrowing (approx 50%) of the ascending aorta and pulmonary arteries was detected through gross examination and histologic analysis in an African grey parrot.(Sedacca et al. 2009) A blue and gold macaw that was suspected to have narrowing of the aorta and brachiocephalic arteries on angiography was found at necropsy to have narrowed arterial lumens.(Phalen et al. 1996) A blue-fronted Amazon parrot was also found to have a 60% to 95% reduction in lumen diameter of the carotid arteries caused by atherosclerosis.(Johnson et al. 1992) Furthermore, several examples of arterial luminal stenosis are cited in reviews on atherosclerosis in birds.(StLeger 2007; Bavelaar & Beynen 2004a) These reports support CTA as potentially useful in the evaluation of birds with suspected vascular stenosis. Additionally, a phantom study (Suzuki et al. 2004) of the effect of vascular inner diameter on measurement accuracy showed similar measurement errors existed among the 3-, 4-, and 6-mm-diameter vascular models through

use of a standard algorithm. The results of the present study suggested that CTA may be of value in assessing the major arteries of psittacine species that are of sizes similar to the small vascular models. However, given the small size of the species evaluated, it is possible that arterial lumens cannot be measured accurately and that quantification of the amount of stenosis may not be achievable. To further determine the accuracy of CTA measurements in birds, such measurements will need to be confirmed at necropsy on healthy birds and birds with cardiovascular diseases, including atherosclerosis. Arterial luminal stenosis is a consequence of atherosclerosis in psittacine birds and is believed to be a contributing factor to clinical signs, tissue ischemia, or acute death in affected birds. However, the degree and clinical importance of arterial luminal stenosis has not been properly characterized. More studies are needed to investigate the relationship between arterial stenosis, atherosclerosis, and clinical signs of disease in birds. Studies are also needed to establish and improve the potential of CTA in the diagnosis of atherosclerosis in parrots.

CONCLUSION

The series of research investigations presented here on psittacine atherosclerosis identified several significant findings that are important for future research in the area.

Psittacine atherosclerotic lesions are similar to human lesions and animals used as experimental models and the classification system endorsed by the AHA could be applied to psittacine lesions. The use of this classification scheme in observational and experimental studies on psittacine atherosclerosis will allow further findings to be more comparable between experiments but also between animal species. Psittacine atherosclerotic lesions have the same basic characteristics than other species. Early lesions (type I-II) are clinically silent and characterized by mild lipid deposition and foam cells accumulation with minimal disruption of the arterial architecture and no stenosis. Intermediate lesions (type III) are the transition between early and advanced lesions and could either progress to advanced lesion types or regress to other lesion types. Advanced lesions (types IV-V) are more likely to lead to clinical signs from which the pathophysiology seems to preferentially be through flow-limiting stenosis in parrots. Therefore these lesions are also qualified as clinically significant lesions and are characterized by a large lipido-necrotic core covered by a fibrous cap of variable thickness.

Clinical atherosclerotic diseases are present in birds and likely underdiagnosed due to the lack of reliable antemortem diagnostic techniques. Therefore in order to estimate the prevalence of atherosclerotic diseases which is of greater clinical usefulness to avian practitioners than atherosclerotic lesions that can remain silent for decades, we used advanced atherosclerotic lesions (types IV-VI) diagnosed on necropsy as a surrogate to clinical diseases. The prevalence was high and increased dramatically with age. Females showed a greater prevalence than males but a sex effect was not observed in experimental induction of the lesions in Quaker parrots. As previously suspected by many authors, African grey parrots, Amazon parrots, and cockatiels appeared more susceptible to the disease than macaws and cockatoos. These clinically significant lesions could be induced relatively quickly in a minimum of 4 months in Quaker parrots fed a 1% cholesterol diet. The lesions appeared similar than spontaneous lesions in the same species but early lesions were more lipidic and contained less foam cells when compared to our first study. With the differences in time of lesion development between experimental and spontaneous lesions in mind, Quaker parrots appear to be a useful model for further studying diagnostic imaging, pathophysiology, lipid physiology, biochemical changes, and therapeutics of experimental atherosclerosis.

The complicated lesions (type VI) are the main cause of death in humans through fibrous cap rupture, thrombosis, and emboli. For this reason a modification of the AHA classification which is more clinical has been proposed in humans.(Virmani et al. 2000) Interestingly the fibrous cap is generally fairly thin in psittacine atheromatous lesions and rupture and thrombotic complications seldom happen. Only 3% (2/63) of sampled arteries all from a single bird in our first study showed lesion complications which, in this case, were characterized by plaque fissure without thrombosis. In our second study, only 1.9% (10/525) of birds displayed atherothrombotic lesions and lesion complications could not be experimentally induced in our third study despite 8 months of cholesterol feeding. This may be due to the relative small size of birds which may show different hemodynamic characteristics and the different thrombogenic properties observed between avian thrombocytes and mammalian platelets.(Schmaier et al. 2011) Consequently, clinical signs are mainly due to type IV-V advanced lesions as reported in our studies and in

multiple published case reports.(Beaufrere, Holder, et al. 2011; Johnson et al. 1992; Phalen et al. 1996; Sedacca et al. 2009; Bennett 1994; Mans & Brown 2007)

Antemortem diagnosis of atherosclerosis remains one of the challenges of avian cardiology and avian vascular imaging is still in its infancy.(Beaufrère et al. 2010) Since it was confirmed from our research that atherothrombosis is rare but arterial stenosis associated with advanced atherosclerotic disease is common and readily lead to clinical signs, further research should focus on either direct plaque imaging or arterial luminal assessment. Our last study established a standard CTA protocol and reference intervals for arterial diameter but this imaging modality would need to be assessed in atherosclerotic cases before clinical use could be recommended and to evaluate its diagnostic accuracy and precision. Significant stenosis was induced in our psittacine model of atherosclerosis and our CTA protocol combined with a higher resolution scanner could thus be further explored experimentally.

The epidemiology of atherosclerosis is important to know in order to select population at risk for diagnostic screening and estimate the likelihood that clinical signs compatible with atherosclerotic lesions are indeed caused by such lesions. From our second study, we know for instance that aged birds, female birds, and several genera have an increased susceptibility to the disease. Avian patients thought to have a high chance of having advanced atherosclerosis may also be more prone to anesthetic complications and may require a closer anesthetic monitoring and preanesthetic diagnostic workup. Furthermore, reproductive diseases are significantly associated with increased prevalence of atherosclerotic lesions and may be a target for prevention. Therefore chronic reproductive diseases should be treated medically or surgically to prevent potential long-term health effects on other organ system such as the cardiovascular system. In our third study, significant dyslipidemia was correlated to the severity of experimental atherosclerosis but the occurrence, the nature, and the magnitude of dyslipidemia would need to be studied in spontaneous cases before recommendations can be made. Future objectives should include a better characterization of psittacine lipoproteins and cholesterol metabolic pathways, improvements in lipid clinical pathologic diagnostic methods, and investigations into the correlation of dyslipidemia and spontaneous atherosclerotic lesions. To assess the potential beneficial effects of lipid-lowering therapeutics, target values for cholesterol, LDL, and HDL will first need to be determined. Further studies are currently being planned to investigate the pharmacologic and lipid-lowering properties of rosuvastatin in parrots and may bring some useful insight into the use of such drugs for the treatment and management of psittacine atherosclerosis. However anti-atherosclerotic effects will need to be assessed using a psittacine experimental model such as the one proposed here or in lengthy prospective clinical trials.

In conclusion, atherosclerosis is one of the leading diseases of aging psittaciformes and further research will be needed in this area in order to increase the captive lifespan of these species. Our work provides both tools for more consistent and standardized experimental and diagnostic procedures, and important epidemiological information. We hope this will help foster additional research which will benefit both the captive psittacine population and their human caregivers.

REFERENCES

- Abbott, R. et al., 1983. Joint distribution of lipoprotein cholesterol classes. The Framingham study. *Arteriosclerosis*, 3(3), pp.260–72.
- Acierno, M.J. et al., 2008. Agreement between direct and indirect blood pressure measurements obtained from anesthetized Hispaniolan Amazon parrots. *J Am Vet Med Assoc*, 233(10), pp.1587–90.
- Aguilar, R. et al., 1995. Arrhythmias associated with isoflurane anesthesia in bald eagles (*Haliaeetus leucocephalus*). *J Zoo Wildl Med*, 26(4), pp.508–516.
- Ahrens, I., Bode, C. & Peter, K., 2005. Inhibition of platelet activation and aggregation. In A. von Eckardstein, ed. *Atherosclerosis: diet and drugs*. Berlin, Heidelberg: Springer Verlag, pp. 443–462.
- Al-Sadi, H.I. & Abdullah, A.K., 2011. Spontaneous atherosclerosis in free-living pigeons in Mosul area, Iraq. *Pakistan Vet J*, 31(2), pp.166–168.
- Albert, D. et al., 2012. *Dorland's illustrated medical dictionary* 32nd Ed., Philadelphia, PA: Elsevier Saunders.
- Alvarenga, R.R. et al., 2011. Lipoprotein metabolism in poultry. *World Poult Sci J*, 67, pp.431–440.
- American Veterinary Medical Association, 2002. *US pet ownership & demographics sourcebook*, Schaumburg, IL: the American Veterinary Medical Association.
- Anderson, J., Smith, SC & Taylor, R., 2012. Spontaneous atherosclerosis in pigeons: a good model for human disease. In S. Parthasarathy, ed. *Atherogenesis*. InTech, pp. 25–48.
- Awai, K., Hiraishi, K. & Hori, S., 2004. Effect of contrast material injection duration and rate on aortic peak time and peak enhancement at dynamic CT involving injection protocol with dose tailored to patient weight. *Radiology*, 230(1), pp.142–50.
- Ayala, I. et al., 2005. Use of the Chicken as an Experimental Animal Model in Atherosclerosis. *Avian Poultry Biol Rev*, 16(3), p.9.
- Badimon, L, 2001. Atherosclerosis and thrombosis: lessons from animal models. *Thromb Haemost*, 86(1), pp.356–65.
- Bailey, T. & Kinne, J., 2001. Ventricular septal defect in a houbara bustard (*Chlamydotis undulata macqueenii*). *Avian Dis*, 45, pp.229–233.

- Balakrishnan, K.R. et al., 2007. Electron microscopic insights into the vascular biology of atherosclerosis: study of coronary endarterectomy specimens. *Circulation*, 115(14), pp.e388–90.
- Balamurugan, V. & Kataria, J.M., 2004. The hydropericardium syndrome in poultry--a current scenario. *Vet Res*, 28(2), pp.127–48.
- Baptiste, K.E. et al., 1997. Dissecting aortic aneurysm associated with a right ventricular arteriovenous shunt in a mature ostrich (*Struthio camelus*). *J Avian Med Surg*, 11(3), pp.194–200.
- Barakat, H.A. & St Clair, R.W., 1985. Characterization of plasma lipoproteins of grain- and cholesterol-fed White Carneau and Show Racer pigeons. *J lipid Res*, 26(10), pp.1252–68.
- Barbon, A.R., Smith, Stephen & Forbes, N., 2010. Radiographic evaluation of cardiac size in four Falconiform species. *J Avian Med Surg*, 24(3), pp.222–6.
- Barr, D.A., Jerome, W.G. & Lewis, J C, 1991. Morphological characteristics of naturally-occurring atherosclerosis in the brachiocephalic artery of the pigeon. *Exp Mo Pathol*, 54(2), pp.99–111.
- Bartlett, C., 2008. Filarioid nematodes. In C. Atkinson, N. Thomas, & C. Hunter, eds. *Parasitic diseases of wild birds*. Ames, IA: Wiley-Blackwell, pp. 439–462.
- Bartlett, E., Walters, T. & Symons, S., 2007. Carotid stenosis index revisited with direct CT angiography measurement of carotid arteries to quantify carotid stenosis. *Stroke*, 38, pp.286–291.
- Baumel, J., 1993. Systema cardiovasculare. In J. Baumel et al., eds. *Handbook of avian anatomy: Nomina Anatomica Avium*. Cambridge, MA: Nuttall Ornithological Club, pp. 407–476.
- Bavelaar, F. & Beynen, A., 2003. Influence of type and amount of dietary fat on plasma cholesterol concentrations in African grey parrots. *J Appl Res Vet Med*, 1, pp.1–8.
- Bavelaar, F.J. et al., 2005. Plasma lipids and fatty acid composition in parrots in relation to the intake of alpha-linolenic acid from two feed mixtures. *J Anim Physiol Anim Nutr (Berl)*, 89(9-10), pp.359–366.
- Bavelaar, F.J. & Beynen, A.C., 2004a. Atherosclerosis in parrots. A review. *Vet Q*, 26(2), pp.50–60.
- Bavelaar, F.J. & Beynen, A.C., 2003. Severity of atherosclerosis in parrots in relation to the intake of alpha-linolenic acid. *Avian Dis*, 47(3), pp.566–577.
- Bavelaar, F.J. & Beynen, A.C., 2004b. The relation between diet, plasma cholesterol and atherosclerosis in pigeons, quails and chickens. *Int J Poultry Sci*, 3(11), pp.671–684.

- Bavelaar, F.J.J. & Beynen, A.C.C., 2003. Plasma cholesterol concentrations in African grey parrots fed diets containing psyllium. *Int J Appl Res Vet Med*, 1, pp.1–8.
- Beaufrere, H., Pariaut, R., et al., 2010. Avian vascular imaging. *J Avian Med Surg*, 24(3), pp.174–184.
- Beaufrere, H., Nevarez, J G, et al., 2011. Characterization and classification of psittacine atherosclerotic lesions by histopathology, digital image analysis, transmission and scanning electron microscopy. *Avian Pathol*, 40(5), pp.531–544.
- Beaufrere, H. et al., 2012. Comparison of transcoelomic, contrast, and transesophageal echocardiography in anesthetized red-tailed hawk (*Buteo jamaicensis*). *Am J Vet Res*, 73(10), pp.1560–1568.
- Beaufrere, H., Pariaut, Romain, et al., 2010. Feasibility of transesophageal echocardiography in birds without cardiac disease. *J Am Vet Med Assoc*, 236(5), pp.540–547.
- Beaufrere, H., Holder, K.A., et al., 2011. Intermittent claudication-like syndrome secondary to atherosclerosis in a yellow-naped Amazon parrot (*Amazona ochrocephala auropalliata*). *J Avian Med Surg*, 25(4), pp.266–276.
- Beaufrere, H. et al., Prevalence and risk factors in psittacine atherosclerosis: a multicenter case-control study. *J Am Vet Med Assoc. In Press*.
- Beaufrere, H., Aertsens, A. & Fouquet, J., 2007. Un cas d'insuffisance cardiaque congestive chez un perroquet gris. *L'Hebdo Veterinaire*, 200, pp.8–10.
- Beaufrère, H. et al., 2010. Avian vascular imaging: a review. *J Avian Med Surg*, 24(3), pp.174–84.
- Beaufrère, H. et al., 2011. Diagnosis of presumed acute ischemic stroke and associated seizure management in a Congo African grey parrot. *J Am Vet Med Assoc*, 239(1), pp.122–8.
- Beaufrère, H. & Pariaut, R., 2009. Pimobendan. *J Exot Pet Med*, 18(4), pp.311–313.
- Beehler, B., Montali, R. & Bush, M., 1980. Mitral valve insufficiency with congestive heart failure in a Pukeko. *J Am Vet Med Assoc*, 177, pp.934–937.
- Bennett, R.A. & Gilson, S.D., 1999. Surgical management of bifid sternum in two African grey parrots. *J Am Vet Med Assoc*, 214(3), pp.372–4, 352.
- Bennett, R.A., 1994. Neurology. In B. W. Ritchie, G. J. Harrison, & L. R. Harrison, eds. *Avian Medicine: Principles and Applications*. Lake Worth, FL: Wingers Publishing, pp. 723–747.

- Bersot, T. & Mahley, R., 2005. Clinical classifications of lipid abnormalities. In V Fuster, E. Topol, & E. Nabel, eds. *Atherothrombosis and coronary artery disease*. Philadelphia, PA: Lippincott Williams & Wilkins, pp. 129–137.
- Bhatia, L.S. et al., 2012. Non-alcoholic fatty liver disease: a new and important cardiovascular risk factor? *Eur Heart J*, 33(10), pp.1190–200.
- Biesiadecki, B.J. & Jin, J.-P., 2002. Exon skipping in cardiac troponin T of turkeys with inherited dilated cardiomyopathy. *J Biol Chem*, 277(21), pp.18459–68.
- Blaton, V. & Peeters, H., 1976. The nonhuman primates as models for studying human atherosclerosis: studies on the chimpanzee, the baboon and the rhesus macacus. *Adv Exp Med Biol*, 67(00), pp.33–64.
- Bobryshev, Y.V., 2006. Monocyte recruitment and foam cell formation in atherosclerosis. *Micron*, 37(3), pp.208–222.
- Bocan, T.M. et al., 1994. Atherosclerotic lesion development in hypercholesterolemic Japanese quail following probucol treatment: a biochemical and morphologic evaluation. *Pharmacol Res*, 29(1), pp.65–76.
- Bocan, T.M.A. & Guyton, J.R., 1986. Ultrastructure of the human aortic fibrolipid lesion: formation of the atherosclerotic lipid-rich core. *Am J Pathol*, 123, p.413.
- Bohorquez, F. & Stout, C., 1972. Aortic atherosclerosis in exotic avians. *Exp Mol Pathol*, 17(3), pp.50–60.
- Bondjers, G., 1994. Anti-Atherosclerotic Effects of Beta-Blockers. *Eur Heart J*, 15(suppl C), pp.8–15.
- Boon, J., 2011. Evaluation of size, function, and hemodynamics. In J. Boon, ed. *Veterinary Echocardiography*. Oxford, UK: Wiley-Blackwell, pp. 153–266.
- Borgarelli, M. et al., 2012. Survival characteristics and prognostic variables of dogs with preclinical chronic degenerative mitral valve disease attributable to myxomatous degeneration. *J Vet Intern Med*, 26(1), pp.69–75.
- Boskovic, M. et al., 1995. Möglichkeiten und grenzen echokardiographischer untersuchungen bei tag-und nachgreivogeln (Accipitriformes, falconiformes, strigiformes). *Tierarztl Prax*, 27, pp.334–41.
- Bougiouklis, P.A. et al., 2005. Rupture of the right auricle in broiler chickens. *Avian Pathol*, 34(5), pp.388–91.
- Bowles, H., 2006. Evaluating and treating the reproductive system. In G. J. Harrison & T. Lightfoot, eds. *Clinical Avian Medicine*. Palm Beach, FL: Spix Publishing, pp. 519–540.

- Braun, S., Krautwald-Junghanns, M.E. & Straub, J., 2002. About type and incidence of heart disease in psittacines kept in captivity in Germany. *Dtsch Tierarztl Wochenschr*, 109(6), pp.255–260.
- Brightsmith, D.J. et al., 2010. Nutritional Content of the Diets of Free-living Scarlet Macaw Chicks in Southeastern Peru. *J Avian Med Surg*, 24(1), pp.9–23.
- de Brue, J. et al., 1958. *Classification of atherosclerotic lesions - Report of a study group*, Geneva: World Health Organization.
- Budoff, M. et al., 2008. Task force 13: training in advanced cardiovascular imaging (computed tomography). *J Am Coll Cardiol*, 51(3), pp.409–414.
- Buerkle, M. & Wust, E., 2010. Bifid sternum in an African grey (*Psittacus erithacus*) and an Orange-winged Amazon parrot (*Amazona amazonica*). In *Proc Annu Assoc Avian Med*. p. 331.
- Bulmer, B., 2010. Angiotensin converting enzyme inhibitors and vasodilators. In S. Ettinger & E. Feldman, eds. *Textbook of Veterinary Internal Medicine*. St Louis, MO: Saunders Elsevier, pp. 1216–1223.
- Burger, W.P. et al., 1994. Cardiomyopathy in ostriches (*Struthio camelus*) due to avocado (*Persea americana* var. *guatemalensis*) intoxication. *J South Afric Vet Assoc*, 65(3), pp.113–8.
- Burnick, N. & Degernes, L., 1993. Electrocardiography on fifty-nine anesthetized convalescing raptors. In P. Redig et al., eds. *Raptor Biomedicine*. Minneapolis, MN: University of Minnesota Press, pp. 111–121.
- Bélangier, M.C., 2005. Echocardiography. In S. J. Ettinger & E. C. Feldman, eds. *Textbook of Veterinary Internal Medicine*. Saint Louis, MI: Elsevier Saunders, pp. 311–326.
- Calle, P., Montali, R. & Janssen, D., 1982. Distal extremity necrosis in captive birds. *J Wildl Dis*, 18(4), pp.473–479.
- Casale, E.S., Qureshi, M.A. & Shih, J.C., 1992. Immunocytochemical and scanning electron microscopic studies of atherosclerosis in Japanese quail. *Poultry Sci*, 71(1), pp.141–150.
- Chamberlain, J.G. & Belton, C., 1987. Effects of long term consumption of fish oil (Maxepa) on serum lipids and arterial ultrastructure in Japanese quail (*Coturnix coturnix japonica*). *Atherosclerosis*, 68(1-2), pp.95–103.
- Chapman, K.P., Stafford, W.W. & Day, C.E., 1976. Produced by selective breeding of Japanese quail animal model for experimental atherosclerosis. *Adv Exp Med Biol*, 67(00), pp.347–356.

- Chapman, M.J., 2006. Review: Fibrates: therapeutic review. *Brit J Diabetes Vasc Dis*, 6(1), pp.11–19.
- Charlton, B. et al., 2006. Cardiovascular diseases of chickens. In B. Charlton et al., eds. *Avian disease manual*. Madison, USA: American Association of Avian Pathologists, Inc, pp. 174–178.
- Cheville, N.F., 1994a. Consequences of acute cell injury: necrosis, recovery, and hypertrophy. In N. F. Cheville, ed. *Ultrastructural pathology: an introduction to interpretation*. Ames, IA: Iowa State University Press, pp. 80–125.
- Cheville, N.F., 1994b. Vascular tissue. In N. F. Cheville, ed. *Ultrastructural pathology: an introduction to interpretation*. Ames, IA: Iowa State University Press, pp. 336–392.
- Choudhury, R., Fuster, V. & Fayad, Z., 2005. Evolving invasive and noninvasive imaging techniques in atherothrombotic disease. In V Fuster, E. Topol, & E. Nabel, eds. *Atherothrombosis and coronary artery disease*. Philadelphia, PA: Lippincott Williams & Wilkins, pp. 703–715.
- Cinar, A. et al., 1996. The electrocardiogram of the Pekin duck. *Avian Dis*, 40(4), pp.919–23.
- Cines, D.B. et al., 1998. Endothelial cells in physiology and in the pathophysiology of vascular disorders. *Blood*, 91(10), pp.3527–3561.
- Clarkson, T.B. et al., 1959. Atherosclerosis in pigeons: its spontaneous occurrence and resemblance to human atherosclerosis. *Arch Pathol*, 68, pp.143–147.
- Clarkson, T.B., 1998. Nonhuman primate models of atherosclerosis. *Lab Anim Sci*, 48(6), pp.569–572.
- Claves, J.L. et al., 1997. Evaluation of contrast densities in the diagnosis of carotid stenosis by CT angiography. *Am J Roentgen*, 169(2), pp.569–73.
- Coen, M. & Bochaton-Piallot, M.L., 2010. Phenotypic heterogeneity of smooth muscle cells - implications for atherosclerosis. In S.J. George & J. Johnson, eds. *Atherosclerosis: molecular and cellular mechanisms*. Weinheim, Germany: Wiley-Blackwell, pp. 327–337.
- Congiu, Terenzio et al., 2010. Scanning electron microscopy examination of endothelium morphology in human carotid plaques. *Micron*, 41(5), pp.532–536.
- Cooper, J.E. & Pomerance, A., 1982. Cardiac lesions in birds of prey. *J Comp Pathol*, 92(2), pp.161–8.
- Cornejo, J. et al., 2011. Predicted metabolizable energy density and amino acid profile of the crop contents of free-living scarlet macaw chicks (*Ara macao*). *J Animal Physiol Animal Nutr*.

- Cote, E. & Ettinger, S., 2005. Electrocardiography and cardiac arrhythmias. In S. Ettinger & E. Feldman, eds. *Textbook of Veterinary Internal Medicine*. Saint Louis, MI: Elsevier Saunders, pp. 1040–1076.
- Courchesne, S. & Garner, M., 2009. What is your diagnosis? *J Avian Med Surg*, 23, pp.69–73.
- Crespo, R. & Shivaprasad, H., 2008. Developmental, metabolic, and other noninfectious disorders. In Y. Saif et al., eds. *Diseases of Poultry*. Ames, IA: Blackwell Publishing, pp. 1149–1195.
- Cuchel, M. et al., 2010. Pathways by which reconstituted high-density lipoprotein mobilizes free cholesterol from whole body and from macrophages. *Arterioscler Thromb Vasc Biol*, 30(3), pp.526–32.
- Cullen, P., Rauterberg, J. & Iorkowski, S., 2005. The pathogenesis of atherosclerosis. In A. vonEckardstein, ed. *Atherosclerosis: diet and drugs*. Berlin, Germany: Springer, pp. 3–70.
- Da Cunha, A.F. et al., 2011. Pharmacokinetics/Pharmacodynamics of bupivacaine and lidocaine in chickens. In *Proc Annu Conf Assoc Avian Vet*. p. 313.
- Currie, R.J., 1999. Ascites in poultry: recent investigations. *Avian pPthol*, 28(4), pp.313–26.
- Cybulsky, M.I. & Gimbrone, M.A., 1991. Endothelial expression of a mononuclear leukocyte adhesion molecule during atherogenesis. *Science*, 251(4995), pp.788–91.
- Czarnecki, C., 1986. Comparative Pharmacology - Doxorubicin (adriamycin)-induced cardiotoxicity in turkey poult: An animal model. *Comp Biochem Physiol C Comp Pharmacol*, pp.53–60.
- Czarnecki, C. & Good, A., 1980. Electrocardiographic technic for identifying developing cardiomyopathies in young turkey poults. *Poult Sci*, 59, pp.1515–1520.
- Czarnecki, C.M., 1986. Quantitative morphological alterations during the development of furazolidone-induced cardiomyopathy in turkeys. *J Comp Pathol*, 96(1), pp.63–75.
- Dansky, H.M. et al., 2002. A phenotype-sensitizing Apoe-deficient genetic background reveals novel atherosclerosis predisposition loci in the mouse. *Genetics*, 160(4), pp.1599–608.
- Dauber, D.V. V & Katz, L.N.N., 1943. Experimental atherosclerosis in the chick. *AMA Arch*, 36(5), pp.473–492.
- Daugherty, A. & Rateri, D.L., 2005. Development of experimental designs for atherosclerosis studies in mice. *Methods*, 36(2), pp.129–38.
- Davies, P.F. et al., 1976. Scanning electron microscopy in the evaluation of endothelial integrity of the fatty lesion in atherosclerosis. *Atherosclerosis*, 25(1), pp.125–130.

- Day, C.E., Stafford, W.W. & Schurr, P.E., 1977. Utility of selected line (SEA) of the Japanese quail (*Coturnix coturnix japonica*) for the discovery of new anti-atherosclerosis drugs. *Lab Anim Sci*, 27(5 Pt 2), pp.817–821.
- Degernes, L., 2008. Waterfowl toxicology: a review. *Vet Clin North Am Exot Anim Pract*, 11, pp.283–300.
- Dell’Orbo, C. et al., 2010. Atherosclerotic alterations in human carotid observed by scanning electron microscopy. *Ital J Anat Embryol*, 115(1), pp.53–58.
- Dendorfer, A., Dominiak, P. & Schunkert, H., 2005. ACE inhibitors and angiotensin II receptor antagonists. In A. vonEckardstein, ed. *Atherosclerosis: diet and drugs*. Berlin, Heidelberg: Springer Verlag, pp. 407–422.
- Dillard, A., Matthan, N.R. & Lichtenstein, A.H., 2010. Use of hamster as a model to study diet-induced atherosclerosis. *Nutri Metabol*, 7(1), p.89.
- Dilley, R.J., 2001. Identification of cell types and quantification of lesion composition. In A F Drew, ed. *Methods in Molecular Medicine, vol 52: Atherosclerosis: experimental methods and protocols*. Totowa, NJ: Humana Press Inc., pp. 187–194.
- Doherty, T.M. et al., 2003. Calcification in atherosclerosis: bone biology and chronic inflammation at the arterial crossroads. *Proc Nat Acad Sci USA*, 100(20), pp.11201–11206.
- Donders, A.R.T. et al., 2006. Review: a gentle introduction to imputation of missing values. *J Clin Epidemiol*, 59(10), pp.1087–91.
- Dorrestein, G.M. et al., 1977. Causes of disease and death in birds. *Tijdschrift voor Diergeneeskunde*, 102, pp.437–447.
- Dowell, S.F. et al., 2001. Standardizing Chlamydia pneumoniae assays: recommendations from the Centers for Disease Control and Prevention (USA) and the Laboratory Centre for Disease Control (Canada). *Clin Infect Dis*, 33(4), pp.492–503.
- Drew, A.F., 2010. Animal models of diet-induced atherosclerosis. In A.F. Drew, ed. *Atherosclerosis: experimental methods and protocols*. Humana Press Inc., pp. 1–6.
- Dugan, J.P., Feuge, R.R. & Burgess, D.S., 2002. Review of evidence for a connection between Chlamydia pneumoniae and atherosclerotic disease. *Clin Therap*, 24(5), pp.719–35.
- Dumoncaux, G. & Harrison, G., 1994. Toxins. In B. Ritchie, G. Harrison, & L. Harrison, eds. *Avian Medicine: Principles and Applications*. Lake Worth, FL: Wingers Publishing, pp. 1030–1052.
- Duncker, H., 1979. Coelomic cavities. In A. King & JM McLelland, eds. *Form and function in birds. Volume 1*. London: Academic Press, pp. 39–68.

- Duran, M.C. et al., 2002. Proteomic analysis of human vessels: Application to atherosclerotic plaques. *Proteomics*, 3(6), pp.973–978.
- D’Agostino, R.B. et al., 2008. General cardiovascular risk profile for use in primary care: the Framingham Heart Study. *Circulation*, 117(6), pp.743–53.
- van Eck, M. et al., 2005. Scavenger receptor BI and ATP-binding cassette transporter A1 in reverse cholesterol transport and atherosclerosis. *Curr Opin Lipidol*, 16(3), pp.307–15.
- Echols, M.S., Craig, T.M. & Speer, B.L., 2000. Heartworm (*Paronchocerca ciconarum*) Infection in 2 Saddle-Billed Storks (*Ephippiorhynchus senegalensis*). *J Avian Med Sur*, 14(1), pp.42–47.
- Einzig, S., Jankus, E. & Moller, J., 1972. Ventricular septal defect in turkeys. *Am J Vet Res*, 33, pp.563–566.
- Ellis, A.E. et al., 2007. Pathology and epidemiology of natural West Nile viral infection of raptors in Georgia. *J Wildl Dis*, 43(2), pp.214–23.
- Ensley, P., Hatkin, J. & Silverman, S., 1979. Congestive heart disease in a greater Hill mynah. *J Am Vet Med Assoc*, 175, pp.1010–1013.
- Esfandiary, A. et al., 2010. Diuretic effects of several chemical and herbal compounds in adult laying hens. *Int J Poultry Sci*, 9(3), pp.247–253.
- Evans, D. et al., 2001. Congenital cardiovascular anomalies, including ventricular septal defects in 2 cockatoos. *J Avian Med Surg*, 15(2), pp.101–106.
- Taylor. et al., 2012. Statins for the primary prevention of cardiovascular disease. *Cochrane Database of Systematic Reviews*, Issue 1, p.Art. No.:CD004816. DOI: 10.1002/14651858.CD004816.
- Falk, E., 2006. Pathogenesis of atherosclerosis. *J Am Coll Cardiol*, 47(8, suppl C), pp.C7–13.
- Falk, E. & Shah, P.K., 2005. Pathogenesis of atherothrombosis: role of vulnerable, ruptured, and eroded plaques. In V. Fuster, E. J. Topol, & E. G. Nabel, eds. *Atherothrombosis and coronary artery disease*. Philadelphia, PA: Lippincott Williams & Wilkins, pp. 451–465.
- Farb, A. et al., 1995. Sudden coronary death. Frequency of active coronary lesions, inactive coronary lesions, and myocardial infarction. *Circulation*, 92(7), pp.1701–9.
- Feinstein, S., 2008. *Non-invasive surrogate markers of atherosclerosis* S. Feinstein, ed., London, UK: Informa Healthcare.
- Fernandez, M.L. & Volek, J.S., 2006. Guinea pigs: a suitable animal model to study lipoprotein metabolism, atherosclerosis and inflammation. *Nutr Metab*, 3(17).

- Ferreras, M.C. et al., Proximal aortic dissection (dissecting aortic aneurysm) in a mature ostrich. *Avian Dis*, 45(1), pp.251–6.
- Finlayson, R., 1965. Spontaneous arterial disease in exotic animals. *J Zool*, 147, pp.239–343.
- Finlayson, R. & Hirschinson, V., 1961. Experimental atheroma in budgerigars. *Nature*, 192, pp.369–370.
- Finlayson, R., Symons, C. & T-W-Fiennes, R.N., 1962. Atherosclerosis: a comparative study. *BMJ*, 502, pp.501–507.
- Fletcher, O. & Abdul-Aziz, T., 2008. Cardiovascular system. In OJ Fletcher & T. Abdul-Aziz, eds. *Avian histopathology*. Madison, USA: American Association of Avian Pathologists, Inc, pp. 98–129.
- Fox, H., 1933. Arteriosclerosis in lower mammals and birds: its relation to the disease in man. In E. Cowdry, ed. *Arteriosclerosis*. New York, NY: The MacMillan Company, pp. 153–193.
- Fricke, C. et al., 2009. Characterization of atherosclerosis by histochemical and immunohistochemical methods in African grey parrots (*Psittacus erithacus*) and Amazon parrots (*Amazona* spp.). *Avian Dis*, 53, pp.466–472.
- Friedewald, W.T., Levy, R.I. & Fredrickson, D.S., 1972. Estimation of the Concentration of Low-Density Lipoprotein Cholesterol in Plasma, Without Use of the Preparative Ultracentrifuge. *Clin. Chem.*, 18(6), pp.499–502.
- Frohlich, E., 2001. Fibrosis and ischemia: the real risks in hypertensive heart disease. *Am J Hypert*, 14(6), pp.s194–s199.
- Fuentes, V., 2010. Inotropes: inodilators. In S. Ettinger & E. Feldman, eds. *Textbook of Veterinary Internal Medicine*. St Louis, MO, pp. 1202–1207.
- Fulton, R., 2008. Other toxins and poisons. In Y. Saif et al., eds. *Diseases of Poultry*. Ames, IA: Blackwell Publishing, pp. 1231–1258.
- Gancz, A., Clubb, S. & Shivaprasad, H., 2012. Advanced diagnostic approaches and current management of proventricular dilation disease. *Vet Clin North Am Exot Anim Pract*, 13(3), pp.471–494.
- Garner, M.M. & Raymond, J.T., 2003. A retrospective study of atherosclerosis in birds. In *Proc Annu Assoc Avian Med*. pp. 59–66.
- George, S.J. & Lyon, C., 2010. Pathogenesis of atherosclerosis. In S J George & J Johnson, eds. *Atherosclerosis: molecular and cellular mechanisms*. Weinhein, Germany: Wiley-Vch Gmbh & Co, pp. 3–20.

- Gilbert, C. et al., 2007. Toxicokinetics of the active doxorubicin metabolite, doxorubicinol, in sulphur-crested cockatoos (*Cacatua galerita*). *Res Vet Sci*, pp.123–129.
- Godin, D.V. et al., 1995. Sex-related alterations in antioxidant status and susceptibility to atherosclerosis in Japanese quail. *Canadian J Cardiol*, 11(10), pp.945–51.
- Goldstein, D. & Skadhauge, E., 2000. Renal and extrarenal regulation of body fluid composition. In G. Whittow, ed. *Sturkie's Avian Physiology*. San Diego, CA: Academic Press, pp. 265–297.
- Goode, T.B. et al., 1977. Aortic endothelial cell morphology observed in situ by scanning electron microscopy during atherogenesis in the rabbit. *Atherosclerosis*, 27(2), pp.235–251.
- Gottlieb, H. & Lalich, J.J., 1954. The occurrence of arteriosclerosis in the aorta of swine. *Am J Pathol*, 30, pp.851–855.
- Gotto, A.M. & Farmer, J., 2005. Management and adult treatment panel III guidelines. In V Fuster, E. Topol, & E. Nabel, eds. *Atherothrombosis and coronary artery disease*. Philadelphia, PA: Lippincott Williams & Wilkins, pp. 139–152.
- Greenacre, C. et al., 1993. Adult filarioid nematodes (*Chandlerella* sp.) from the right atrium and major veins of a Ducorps' cockatoo (*Cacatua ducorpsii*). *J Assoc Avian Vet*, 7(3), pp.135–137.
- Greiner, E. & Ritchie, B., 1994. Parasites. In B. Ritchie, G. Harrison, & L. Harrison, eds. *Avian Medicine: Principles and Applications*. Lake Worth, FL: Wingers Publishing, pp. 1007–1029.
- Gresham, G.A. & Howard, A.N., 1961. Aortic rupture in the turkey. *J Athero Res*, 1, pp.75–80.
- Griner, L.A., 1983. Birds. In L.A. Griner, ed. *Pathology of zoo animals*. San Diego, CA: Zoological Society of San Diego, pp. 94–267.
- Grosset, C. et al., 2012. Central vestibular disease in a blue and gold macaw (*Ara ararauna*) with vasculopathy and cerebral infarction and hemorrhage. In *Proc Annu Conf Assoc Avian Vet*. p. 257.
- Grunberg, W., 1964. Spontaneous arteriosclerosis in birds. *Bulletin de la societe royale de zoologie d'Anvers*, 43, pp.479–488.
- Grundy, S.M. et al., 1999. Assessment of cardiovascular risk by use of multiple-risk-factor assessment equations: a statement for healthcare professionals from the American Heart Association and the American College of Cardiology. *Circulation*, 100(13), pp.1481–92.

- Grünberg, W. & Kaiser, E., 1966. Spontaneous arteriosclerosis in a population of free-living Egyptian vultures (*Neophron percnopterus*). II. Histochemistry of lesions and chemical analysis of aortic tissue and blood serum. *Acta cardiologica*, 21(4), pp.446–56.
- Guzman, D. et al., *In Press*. Pharmacokinetics of a single oral dose of pimobendan in Hispaniolan Amazon parrot (*Amazona ventralis*). *J Avian Med Surg*.
- Hamburg, N.M. & Vita, J.A., 2005. Endothelial dysfunction in atherosclerosis: mechanisms of impaired nitric oxide bioactivity. In J. Loscalzo, ed. *Molecular mechanisms of atherosclerosis*. Abingdon, UK: Taylor & Francis, pp. 95–110.
- Hamlin, R.L. & Stalnaker, P., 1987. Basis for use of digoxin in small birds. *J Vet Pharmacol Therap*, 10(4), pp.354–356.
- Hammad, S.M., Siegel, H.S. & Marks, H.L., 1998. Total cholesterol, total triglycerides, and cholesterol distribution among lipoproteins as predictors of atherosclerosis in selected lines of Japanese quail. *Comp Biochem Physiol A Mol Integr Physiol*, 119(2), pp.485–492.
- Hanley, C. et al., 1997. Establishing cardiac measurement standards in three avian species. *J Avian Med Surg*, 11(1), pp.15–19.
- Hanley, C. et al., 2005. Interclavicular hemangiosarcoma in a double yellow-headed Amazon parrot (*Amazona ochrocephala oratrix*). *J Avian Med Surg*, 19(2), pp.130–137.
- Hansen, J., 1977. Spontaneous atherosclerosis - Ultrastructural study in white Carneau pigeon. *Vichows Arch A Pathol Anat Histol*, 375(2), pp.147–157.
- Hansson, G.K., 2005. Inflammation, atherosclerosis, and coronary artery disease. *N Engl J Med*, 352(16), pp.1685–95.
- Harari, J. & Miller, D., 1983. Ventricular septal defect and bacterial endocarditis in a whistling swan. *Avian Pathol*, 183, pp.1296–1297.
- Harel, O. & Zhou, X.-H., 2007. Multiple imputation: review of theory, implementation and software. *Stat Med*, 26(16), pp.3057–77.
- Hargis, A. et al., 1989. Avocado (*Persea americana*) intoxication in caged birds. *J Am Vet Med Assoc*, 194(1), pp.64–66.
- Harper, M. et al., 2010. Platelets: their role in atherogenesis and thrombosis in coronary artery disease. In S.J. George & J. Johnson, eds. *Atherosclerosis: molecular and cellular mechanisms*. Weinheim, Germany: Wiley-Blackwell, pp. 343–363.
- Hawkins, M. et al., 2013. Birds. In J. Carpenter & C. Marion, eds. *Exotic animal formulary*. St Louis, MO: Elsevier, pp. 184–438.

- Hawkins, M.G. et al., 2003. Pharmacokinetics and anesthetic and cardiopulmonary effects of propofol in red-tailed hawks (*Buteo jamaicensis*) and great horned owls (*Bubo virginianus*). *Am J Vet Res*, 64(6), pp.677–683.
- He, S.-Y.Y. et al., 2005. Effect of crocin on experimental atherosclerosis in quails and its mechanisms. *Life Sci*, 77(8), pp.907–921.
- Hermier, D. & Dillon, J., 1992. Characterization of dietary-induced hypercholesterolemia in the chicken. *Biochim Biophys Acta*, 1124, pp.178–184.
- Hermier, D., 1997. Lipoprotein Metabolism and Fattening in Poultry. *J. Nutr.*, 127(5), p.805S–.
- Hessler, J.R. et al., 1983. Lipoprotein oxidation and lipoprotein-induced cytotoxicity. *Arteriosclerosis*, 3(3), pp.215–22.
- Hirsch, A.T. et al., 2006. ACC/AHA 2005 guidelines for the management of patients with peripheral arterial disease (lower extremity, renal, mesenteric, and abdominal aortic): executive summary a collaborative report from the American Association for Vascular Surgery/Society for Vas. *J Am Coll Cardiol*, 47(6), pp.1239–312.
- Hoerr, F., 2008. Mycotoxicoses. In Y. Saif et al., eds. *Diseases of Poultry*. Ames, IA: Blackwell Publishing, pp. 1197–1229.
- Holvoet, P. et al., 1998. LDL hypercholesterolemia is associated with accumulation of oxidized LDL, atherosclerotic plaque growth, and compensatory vessel enlargement in coronary arteries of miniature pigs. *Arterioscler Thromb Vasc Biol*, 18(3), pp.415–22.
- Honaker, J., King, G. & Blackwell, M., 2011. Amelia II: A Program for Missing Data. *J Stat Software*, 45(7), pp.1–47.
- Hoofnagle, A.N. & Heinecke, J.W., 2009. Lipoproteomics: using mass spectrometry-based proteomics to explore the assembly, structure, and function of lipoproteins. *J Lipid Res*, 50(10), pp.1967–75.
- Hoymans, V.Y. et al., 2007. Chlamydia pneumoniae-based atherosclerosis: a smoking gun. *Acta cardiologica*, 62(6), pp.565–71.
- Hoymans, V.Y. et al., 2004. Immunohistostaining assays for detection of Chlamydia pneumoniae in atherosclerotic arteries indicate cross-reactions with nonchlamydial plaque constituents. *J Clin Microbiol*, 42(7), pp.3219–24.
- Ignatowski, A.C., 1908. Influence of animal food on the organism of rabbits. *S. Peterb. Izviest. Imp. Voenno-Med. Akad.*, 16, pp.154–173.
- Inoue, Y. et al., 1995. The response of serum and hepatic lipids and the aortic wall to different levels of dietary cholesterol: a comparative study between hyperlipidemia-and-

- atherosclerosis-prone quail and commercially available quail. *Tohoku J Exp Med*, 175(1), pp.1–13.
- Isaza, R., Buergelt, C. & Kollias, G. V, 1992. Bacteremia and vegetative endocarditis associated with a heart murmur in a blue-and-gold macaw. *Avian Dis*, 36(4), pp.1112–1116.
- Ishibashi, S. et al., 1993. Hypercholesterolemia in low density lipoprotein receptor knockout mice and its reversal by adenovirus-mediated gene delivery. *J Clinical Investig*, 92(2), pp.883–93.
- Ishibashi, S. et al., 1994. The two-receptor model of lipoprotein clearance: tests of the hypothesis in “knockout” mice lacking the low density lipoprotein receptor, apolipoprotein E, or both proteins. *Proc Nat Acad Sci USA*, 91(10), pp.4431–5.
- Iwasaki, H. et al., 2000. The major low molecular weight apolipoprotein from normal and hyperlipidemia atherosclerosis-prone (LAP) Japanese quail. *Biochim Biophys Acta*, 1483(3), pp.316–324.
- Jawien, J., Nastalek, P. & Korbut, R., 2004. Mouse models of experimental atherosclerosis. *J Phys Res*, 55(3), pp.503–517.
- Jellinger, P. et al., 2012. American Association of Clinical Endocrinologists’ guidelines for management of dyslipidemia and prevention of atherosclerosis. *End Pract*, 18(Suppl 1), pp.1–77.
- Jenkins, J.R., 1991. Use of computed tomography in pet bird practice. In *Proc Annu Conf Assoc Avian Vet*. pp. 276–279.
- Jerome, W.G. & Lewis, J C, 1985. Early atherogenesis in the white carneau pigeon. II Ultratructural and cytochemical observations. *Am J Pathol*, 119, p.210.
- Jerome, W.G. & Lewis, J C, 1984. Early atherogenesis in white carneau pigeons, part I: leukocyte margination and endothelial alterations at the celiac bifurcation. *Am J Pathol*, 116, pp.56–58.
- Jerome, W.G. & Lewis, J C, 1990. Early atherogenesis in White Carneau pigeons: effect of a short-term regression diet. *Exp Mol Pathol*, 53(3), pp.223–238.
- Jerome, W.G. & Lewis, J.C., 1997. Cellular dynamics in early atherosclerosis lesion progression in white carneau pigeons. *Arterioscler Thromb Vasc Biol*, 17, pp.654–664.
- Jessup, D., 1980. Valvular endocarditis and bacteremia in a bald eagle. *Med Vet Pract*, 61, pp.49–51.

- Johnson, J. et al., 2005. Plaque rupture after short periods of fat feeding in the apolipoprotein E-knockout mouse: model characterization and effects of pravastatin treatment. *Circulation*, 111(11), pp.1422–30.
- Johnson, J.H. et al., 1992. Atherosclerosis in psittacine birds. In *Proc Annu Assoc Avian Med*.
- Johnston, M.S. et al., 2011. Precision of Repeated, Doppler-Derived Indirect Blood Pressure Measurements in Conscious Psittacine Birds. *J Avian Med and Surg*, 25(2), pp.83–90.
- Jones, N.L., 1997. Simultaneous labeling of lipoprotein intracellular trafficking in pigeon monocyte-derived macrophages. *Am J Pathol*, 150(3), pp.1113–1124.
- Jousilahti, P. et al., 1999. Sex, Age, Cardiovascular Risk Factors, and Coronary Heart Disease : A Prospective Follow-Up Study of 14 786 Middle-Aged Men and Women in Finland. *Circulation*, 99(9), pp.1165–1172.
- Joyner, K.L., 1994. Theriogenology. In B.W. Ritchie, G. J. Harrison, & L. R. Harrison, eds. *Avian Medicine: Principles and Applications*. Lake Worth, FL: Wingers Publishing, pp. 748–804.
- Joyner, P.H. et al., 2008. Induction and recovery characteristics and cardiopulmonary effects of sevoflurane and isoflurane in bald eagles. *Am J Vet Res*, 69(1), pp.13–22.
- Julian, R.J., 1993. Ascites in poultry. *Avian Pathol*, 22(3), pp.419–54.
- Julian, R.J., 1998. Rapid growth problems: ascites and skeletal deformities in broilers. *Poultry Sci*, 77(12), pp.1773–80.
- Julian, R.J., 2002. Cardiovascular disease. In F. Jordan et al., eds. *Poultry Dis*. London, UK: W.B. Saunders, pp. 484–495.
- Julian, R.J., 2005. Production and growth related disorders and other metabolic diseases of poultry--a review. *Vet J*, 169(3), pp.350–69.
- Jullian, R.J., 2002. Cardiovascular diseases. In F. Jordan et al., eds. *Poultry diseases*. London, UK: W.B. Saunders, pp. 484–495.
- Jun, M. et al., 2010. Effects of fibrates on cardiovascular outcomes: a systematic review and meta-analysis. *Lancet*, 375(9729), pp.1875–84.
- Kamari, Y. et al., 2008. Characterisation of atherosclerotic lesions with scanning electron microscopy (SEM) of wet tissue. *Diab Vasc Dis Res*, 5(1), pp.44–47.
- Kane, J.P., 2005. Structure and function of the plasma lipoproteins and their receptors. In V. Fuster, E. J. Topol, & E. G. Nabel, eds. *Atherothrombosis and coronary artery disease*. Philadelphia, PA: Lippincott Williams & Wilkins, pp. 85–94.

- Karim, R. et al., 2008. Relation of framingham risk score to subclinical atherosclerosis evaluated across three arterial sites. *Am J Cardiol*, 102(7), pp.825–830.
- Katsuda, S. et al., 1992. Human atherosclerosis. III Immunocytochemical analysis of the cell composition of lesions in young adults. *Am J Pathol*, 140, pp.907–914.
- Kavey, R.-E.W.E.W. et al., 2003. American Heart Association guidelines for primary prevention of atherosclerotic cardiovascular disease beginning in Childhood. *Circulation*, 107(11), p.1562.
- Kawaguchi, H. et al., 2011. Micromini pig, a non-rodent experimental animal optimized for life science research: novel atherosclerosis model induced by high fat and cholesterol diet. *J Pharm Sci*, 115(2), pp.115–121.
- Keene, B. et al., 2010. Guidelines for the diagnosis and treatment of canine chronic valvular heart disease. In S. Ettinger & E. Feldman, eds. *Textbook of Veterinary Internal Medicine*. St Louis, MO, pp. 1196–1202.
- Kellin, N., 2009. *Auswertung der sektions- und laborbefunde von 1780 vogeln der ordnung psittaciformes in einem zeitraum von vier jahren (2000 bis 2003)*. Doctoral thesis. Justus-Liebig University, Giessen, Germany.
- Kempeneers, P., 1987. *Atherosclerosis in parrots*. Department of Pathology, Faculty of Veterinary Medicine, Utrecht University.
- Kim, D. et al., 2012. Nonalcoholic fatty liver disease is associated with coronary artery calcification. *Hepatology*, 56(2), pp 605-613.
- Kindel, T., Lee, D.M. & Tso, P., 2010. The mechanism of the formation and secretion of chylomicrons. *Atherosclerosis Suppl*, 11, pp.11–16.
- King, A. & McLelland, J.M., 1984. Cardiovascular system. In A. King & J. MacLelland, eds. *Birds: their structure and function*. Bailliere Tindall, pp. 214–236.
- King, A.S. & McLelland, J., 1984. Digestive System. In A. S. King & J. McLelland, eds. *Birds: their structure and function*. Eastbourne, UK: Bailliere Tindall, pp. 84–109.
- Knafo, S.E. et al., 2011. Cardiomyopathy and right-sided congestive heart failure in a red-tailed hawk (*Buteo jamaicensis*). *J Avian Med Surg*, 25(1), pp.32–9.
- Koch, J. et al., 1983. Blood pressure of chickens selected for leanness or obesity. *Poultry Sci*, 62(5), pp.904–7.
- Kolodgie, F.D. et al., 1996. Hypercholesterolemia in the rabbit induced by feeding graded amounts of low-level cholesterol. Methodological considerations regarding individual

- variability in response to dietary cholesterol and development of lesion type. *Arterioscler Thromb Vasc Biol*, 16(12), pp.1454–64.
- Krautwald-Junghanns, M.-E. et al., 1995. Transcoelomic Two-Dimensional Echocardiography in the Avian Patient. *J Avian Med Surg*, 9, pp.19–31.
- Krautwald-Junghanns, M.-E., Pees, M. & Schroff, S., 2011. Cardiovascular system. In M.-E. Krautwald-junghanns et al., eds. *Diagnostic imaging of exotic pets*. Hannover, Germany: Schlutersche Verlagsgesellschaft mbH & Co, pp. 84–91.
- Krautwald-Junghanns, M.-E., Schloemer, J. & Pees, M., 2008. Iodine-based contrast media in avian medicine. *J Exot Pet Med*, 17(3), p.189.
- Krautwald-Junghanns, M.-E. et al., 2004. Research on the anatomy and pathology of the psittacine heart. *J Avian Med Surg*, 18(1), pp.2–11.
- Krista, L. & McQuire, J., 1988. Atherosclerosis in coronary, aortic, and sciatic arteries from wild male turkeys (*Meleagris gallopava silvestris*). *Am J Vet Res*, 49(9), pp.1582–8.
- Kritchevsky, D. et al., 1984. Experimental atherosclerosis in rabbits fed cholesterol-free diets. Part 12. Comparison of peanut and olive oils. *Atherosclerosis*, 50(3), pp.253–9.
- Kushner, L.I., 1999. ECG of the month. Atrioventricular block in a Muscovy duck. *J Am Vet Med Assoc*, 214(1), pp.33–6.
- Kwiterovitch, P.O., 2000. The metabolic pathways of high-density lipoprotein, low-density lipoprotein, and triglycerides: a current review. *Am J Cardiol*, 86, p.5L–10L.
- Langelier, M., Connelly, P. & Subbiah, M.T., 1976. Plasma lipoprotein profile and composition in White Carneau and Show Racer breeds of pigeons. *Canadian J Biochem*, 54(1), pp.27–31.
- Langille, B.L. & Jones, D.R., 1975. Central cardiovascular dynamics of ducks. *Am J Physiol*, 228(6), pp.1856–61.
- Latimer, K.S. et al., 1990. Myocardial sarcocystosis in a grand eclectus parrot (*Eclectus roratus*) and a Moluccan cockatoo (*Cacatua moluccensis*). *Avian Dis*, 34(2), pp.501–505.
- Lauper, N.T. et al., 1975. Anatomy and histology of aorta of White Carneau pigeon. *Lab Invest*, 32(4), pp.536–551.
- Lee, C.H. et al., 2007. CTA contrast enhancement of the aorta and pulmonary artery: the effect of saline chase injected at two different rates in a canine experimental model. *Invest Radiol*, 42(7), pp.486–90.

- Lewis, J.C. et al., 1982. Endothelial surface characteristics in pigeon coronary artery atherosclerosis. 1. Cellular alterations during the initial stages of dietary cholesterol challenge. *Lab Invest*, 46(2), pp.123–138.
- Lewis, J.C. & Kottke, B.A., 1977. Endothelial damage and thrombocyte adhesion in pigeon atherosclerosis. *Science*, 196(4293), pp.1007–1009.
- Lewis, J.C., Taylor, R.G. & Jerome, W.G., 1985. Foam cell characteristics in coronary-arteries and aortas of white carneau pigeons with moderate hypercholesterolemia. *Ann NY Acad Sci*, 454, pp.91–100.
- Li, L.Z., 1989. An electron microscopic study of the morphologic changes in the endothelium in experimental atherosclerosis in pigeons. *Zhonghua Xin Xue Guan Bing Za Zhi*, 17(6), pp.369–370.
- Libby, P. et al., 2002. Inflammation in Atherosclerosis: Transition From Theory to Practice. *Circulation*, 74(2), pp.213–220.
- Libby, P., Inflammation in atherosclerosis. *Nature*, 420(6917), pp.868–74.
- Libby, P., Ridker, P.M. & Hansson, G.K., 2011. Progress and challenges in translating the biology of atherosclerosis. *Nature*, 473(7347), pp.317–25.
- Lichtenberger, M. & Ko, J., 2007. Critical care monitoring. *Vet Clin N Am Exot Anim Pract*, 10(2), pp.317–44.
- Liebson, P., 2008. Echocardiography: left ventricular hypertrophy and atherosclerosis. In S. Feinstein, ed. *Non-invasive surrogate markers of atherosclerosis*. Boca Raton, FL: Informa Healthcare, pp. 1–10.
- Lightfoot, T.L. & Yeager, J.M., 2008. Pet bird toxicity and related environmental concerns. *Vet Clin N Am Exot Anim Pract*, 11(2), pp.229–59, vi.
- Lin, L.-K., 1989. A concordance correlation coefficient to evaluate reproducibility. *Biometrics*, 45, pp.255–268.
- Lindstedt, K.A., Kokkonen, J.O. & Kovanen, P.T., 1992. Soluble heparin proteoglycans released from stimulated mast cells induce uptake of low density lipoproteins by macrophages via scavenger receptor-mediated phagocytosis. *J Lipid Res*, 33(1), pp.65–75.
- Liu, Y., Hopper, K. & Mauger, D., 2000. CT angiography measurement of the carotid artery: optimizing visualization by manipulating window and level settings and contrast material attenuation. *Radiology*, 217, pp.494–500.

- Lizenko, M.V. et al., Content of the main lipid components in blood serum lipoproteins of human and of various animal species. *Zhurnal evoliutsionnoĭ biokhimii i fiziologii*, 43(2), pp.155–61.
- de Loecker, I. & Preiser, J.-C., 2012. Statins in the critically ill. *Ann Intensive Care*, 2(1), p.19.
- Lucas, A. et al., 1996. Development of an avian model for restenosis. *Atherosclerosis*, 119(1), pp.17–41.
- Lumeij, J.T. & Stokhof, A.A., 1985. Electrocardiogram of the racing pigeon (*Columba livia domestica*). *Res Vet Sci*, 38(3), pp.275–8.
- Lumeij, J.T. & Ritchie, B., 1994. Cardiology. In B. W. Ritchie, G. J. Harrison, & L R Harrison, eds. *Avian Medicine: Principles and Applications*. Lake Worth, FL: Wingers Publishing, pp. 695–722.
- Lumeij, J.T., 2008. Avian Clinical Biochemistry. In J. J. Kaneko, J. W. Harvey, & M. L. Bruss, eds. *Clinical Biochemistry of Domestic Animals*. New York, NY: Academic Press, pp. 839–872.
- Lumeij, J.T., Shaik, M.A.S. & Ali, M., 2011. Radiographic reference limits for cardiac width in peregrine falcons (*Falco peregrinus*). *J Am Vet Med Assoc*, 238(11), pp.1459–63.
- MacKinnon, A.M. et al., 1985. Secretion of cholesteryl ester-enriched very low density lipoproteins by the liver of cholesterol-fed rabbits. *Atherosclerosis*, 54(2), pp.145–55.
- Mahley, R.W., Weisgraber, K.H. & Innerarity, T., 1974. Canine lipoproteins and atherosclerosis. II. Characterization of the plasma lipoproteins associated with atherogenic and nonatherogenic hyperlipidemia. *Circ Res*, 35, pp.722–733.
- Maina, J., 1996. Perspectives on the structure and function in birds. In W. Rosskopf & R. Woerpel, eds. *Diseases of cage and aviary birds*. Baltimore, MD: Williams & Wilkins, pp. 163–217.
- Manning, P.J. & Middleton, C.C., 1972. Atherosclerosis in wild turkeys: morphologic features of lesions and lipids in serum and aorta. *Am J Vet Res*, 33(6), pp.1237–46.
- Mans, C. & Brown, C.J., 2007. Radiographic evidence of atherosclerosis of the descending aorta in a grey-cheeked parakeet (*Brotogeris pyrrhopterus*). *J Avian Med Surg*, 21(1), pp.56–62.
- Martin, K., 2006. Psittacine behavioral pharmacotherapy. In A. Luescher, ed. *Manual of parrot behavior*. Ames, IA: Blackwell Publishing, pp. 267–279.
- Martin, M.W.S., Stafford Johnson, M.J. & Celona, B., 2009. Canine dilated cardiomyopathy: a retrospective study of signalment, presentation and clinical findings in 369 cases. *J Small Anim Pract*, 50(1), pp.23–9.

- Martinez, L., Jeffrey, J. & Odom, T., 1997. Electrocardiographic diagnosis of cardiomyopathies in Aves. *Poul Av Biol Reviews*, 8(1), pp.9–20.
- Martinez-Lemus, L.A. et al., 1998. Echocardiography evaluation of cardiac structure and function in Broiler and Leghorn chickens. *Poultry Sci*, 77(7), p.1045(1050).
- Mathers, C.C. et al., 2004. Global burden of disease: data sources, methods, and results. *World Health Organization, survey 199998a2*.
- McCullagh, K.G. & Ehrhart, L.A., 1977. Enhanced synthesis and accumulation of collagen in cholesterol-aggravated pigeon atherosclerosis. *Atherosclerosis*, 26(3), pp.341–352.
- McGill, H.C.C. & McMahan, C.A.A., 2005. Risk factors: overview. In V. Fuster, E. J. Topol, & E. G. Nabel, eds. *Atherothrombosis and coronary artery disease*. Philadelphia, PA: Lippincott Williams & Wilkins, pp. 23–33.
- McGorisk, G.M. & Treasure, C.B., 1996. Endothelial dysfunction in coronary heart disease. *Curr Opinion Cardiol*, 11(4), pp.341–50.
- McLean, J.W. et al., 1987. cDNA sequence of human apolipoprotein(a) is homologous to plasminogen. *Nature*, 330(6144), pp.132–7.
- McLelland, J., 1993. Pericardium, pleura et peritoneum. In J. Baumel et al., eds. *Handbook of avian anatomy: Nomina Anatomica Avium*. Cambridge, MA: Nuttall Ornithological Club, pp. 251–256.
- Mendelsohn, M.E., 2009. Estrogen actions in the cardiovascular system. *Climacteric*, 12 Suppl 1, pp.18–21.
- Miller, M. et al., 2011. Triglycerides and cardiovascular disease: a scientific statement from the American Heart Association. *Circulation*, 123(20), pp.2292–333.
- Mineo, C. et al., 2003. High density lipoprotein-induced endothelial nitric-oxide synthase activation is mediated by Akt and MAP kinases. *J Biol Chem*, 278(11), pp.9142–9.
- Mitchell, E.B. et al., 2008. Congenital mitral stenosis, subvalvular aortic stenosis, and congestive heart failure in a duck. *J Vet Cardiol*, 10(1), pp.67–73.
- Mitchinson, M.J. & Keymer, I.F., 1977. Aortic rupture in ostriches (*Struthio camelus*)-a comparative study. *J Comp Pathol*, 87(1), pp.27–33.
- Moghadasian, M.H., 2002. Experimental atherosclerosis: a historical overview. *Life Sci*, 70(8), pp.855–865.
- Moghadasian, M.H., Frohlich, J.J. & McManus, B.M., 2001. Advances in experimental dyslipidemia and atherosclerosis. *Lab Invest*, 81(9), pp.1173–1177.

- Moore, K.J. & Rayner, K., 2010. Macrophage foam cells formation: the pathways to cholesterol engorgement. In S J George & J Johnson, eds. *Atherosclerosis: molecular and cellular mechanisms*. Weinheim, Germany: Wiley-Vch Gmbh & Co, pp. 231–254.
- Moore, K.J. & Tabas, I., 2011. Macrophages in the pathogenesis of atherosclerosis. *Cell*, 145(3), pp.341–55.
- Morishita, T.Y. et al., 1998. Morbidity and mortality in free-living raptorial birds of Northern California: a retrospective study, 1983–1994. *J Avian Med Surg*, 12(2), pp.78–81.
- Morris, P., Avgeris, S. & Baumgartner, 1989. Hemochromatosis in a greater indian hill mynah (*Gracula religiosa*). *J Assoc Avian Vet*, 3(2), pp.87–92.
- Morrissey, R.B. & Donaldson, W.E., 1977. Rapid accumulation of cholesterol in serum, liver and aorta of Japanese quail. *Poultry Sci*, 56(6), pp.2003–2008.
- Mosca, L., 2005. Estrogen and atherothrombosis. In V Fuster, E. Topol, & E. Nabel, eds. *Atherothrombosis and coronary artery disease*. Philadelphia, PA: Lippincott Williams & Wilkins, pp. 297–307.
- Moss, N.S. & Benditt, E.P., 1970. Spontaneous and experimentally induced arterial lesions, I: an ultrastructural survey of the normal chicken aorta. *Lab Invest*, 22, p.231.
- Nagata, J. et al., 1997. Lipoprotein and apoprotein profiles of hyperlipidemic atherosclerosis-prone Japanese quail. *J Nutr Sci Vitaminol*, 43(1), pp.47–57.
- Nakamura, H. & Ohtsubo, K., 1992. Ultrastructure appearance of atherosclerosis in human and experimentally-induced animal models. *Electron Microscopy Reviews*, 5(1), pp.129–170.
- Naldo, J. & Samour, J., 2004. Causes of morbidity and mortality in falcons in Saudi Arabia. *J Avian Med Surg*, 18(4), pp.229–241.
- Nap, A.M., Lumeij, J T & Stokhof, A.A., 1992. Electrocardiogram of the African grey (*Psittacus erithacus*) and Amazon (*Amazona* spp.) parrot. *Avian Pathol*, 21(1), pp.45–53.
- Nichols, D. & Montali, R., 1995. Atherosclerosis in zoo birds. *Lab Invest*, 52, pp.48–49A.
- Nickel, R. et al., 1977. Circulatory system. In R. Nickel et al., eds. *Anatomy of the domestic birds*. Berlin: Verlag Paul Parey - Springer Verlag, pp. 85–107.
- Nishina, P.M., Verstuyft, J. & Paigen, B., 1990. Synthetic low and high fat diets for the study of atherosclerosis in the mouse. *J Lipid Res*, 31(5), pp.859–69.
- Odom, T.W. et al., 1991. Use of electrocardiographic analysis for investigation of ascites syndrome in broiler chickens. *Avian Dis*, 35(4), pp.738–44.

- Oglesbee, B.L. & Lehmkuhl, L., 2001. Congestive heart failure associated with myxomatous degeneration of the left atrioventricular valve in a parakeet. *J Am Vet Med Assoc*, 218(3), pp.360,376–380.
- Oglesbee, B.L. & Oglesbee, M.J., 1998. Results of postmortem examination of psittacine birds with cardiac disease: 26 cases (1991-1995). *J Am Vet Med Assoc*, 212(11), pp.1737–1742.
- Oglesbee, B.L. et al., 2001. Electrocardiographic Reference Values for Macaws (*Ara* species) and Cockatoos (*Cacatua* species). *J Avian Med Surg*, 15(1), pp.17–22.
- Ojerio, A.D. et al., 1972. Diet-induced atherosclerosis and myocardial infarction in Japanese quail. *Lab Anim Sci*, 22(1), pp.33–39.
- Olkowski, A.A. et al., 1997. A Study of Electrocardiographic Patterns in a Population of Commercial Broiler Chickens. *Vet Res Comm*, 21(1), pp.51–62.
- Olkowski, A.A., 2007. Pathophysiology of Heart Failure in Broiler Chickens: Structural, Biochemical, and Molecular Characteristics. *Poult. Sci.*, 86(5), pp.999–1005.
- Olkowski, A.A. & Classen, H.L., 1998. High Incidence of Cardiac Arrhythmias in Broiler Chickens. *J Vet Med A*, 45(1-10), pp.83–91.
- Olsen G.H. & Gee G.F., 1997, Causes of Mississippi sandhill crane mortality in captivity, 1984-95. In: Proc North Am Crane Workshop, 7: 249-252.
- Orita, S. et al., 1994. Spontaneous aortic atherosclerosis in layer chickens. *J Comp Pathol*, 110, pp.341–347.
- Pahan, K., 2006. Lipid-lowering drugs. *Cell Mol Life Sci*, 63(10), pp.1165–78.
- Paigen, B. et al., 1985. Variation in susceptibility to atherosclerosis among inbred strains of mice. *Atherosclerosis*, 57(1), pp.65–73.
- Pakkal, M., Raj, V. & McCann, G.P., 2011. Non-invasive imaging in coronary artery disease including anatomical and functional evaluation of ischaemia and viability assessment. *Brit J Radiol*, 84 Spec No3, pp.S280–95.
- Paoletti, R., Bolego, C. & Cignerella, A., 2005. Lipid and non-lipid effects of statins. In A. von Eckarstein, ed. *Atherosclerosis: diet and drugs*. Berlin, Germany: Springer Verlag, pp. 365–388.
- Papakonstantinou, E., Roth, M. & Karakiulakis, G., 2001. Isolation and characterization of glycosaminoglycans from human atheromatous vessels. In A F Drew, ed. *Methods in Molecular Medicine, vol 52: Atherosclerosis: experimental methods and protocols*. Totowa, NJ: Humana Press Inc., pp. 123–136.

- Paslawski, R. et al., 2011. Swine as a model of experimental atherosclerosis. *Adv Clin Exp Med*, 20(2), pp.211–215.
- Pasquinelli, G. et al., 1989. Electron microscopy of lipid deposits in human atherosclerosis. *Scann Microsc*, 3(3), pp.1151–1159.
- Pasternak, R.C. et al., 2002. ACC/AHA/NHLBI clinical advisory on the use and safety of statins. *J Am Coll Cardiol*, 40(3), pp.567–72.
- Pearson, T.A., 2002. AHA Guidelines for Primary Prevention of Cardiovascular Disease and Stroke: 2002 Update: Consensus Panel Guide to Comprehensive Risk Reduction for Adult Patients Without Coronary or Other Atherosclerotic Vascular Diseases. *Circulation*, 106(3), pp.388–391.
- Pees, M., Kuhring, K., et al., 2006. Bioavailability and compatibility of enalapril in birds. In *Proc Annu Assoc Avian Med*. pp. 7–11.
- Pees, M., Schmidt, V., et al., 2006. Diagnosis and long-term therapy of right-sided heart failure in a yellow-crowned amazon (*Amazona ochrocephala*). *Vet Rec*, 158(13), pp.445–447.
- Pees, M. & Krautwald-Junghanns, M., 2005. Avian echocardiography. *Sem Avian Exot Pets*, 14(1), pp.14–21.
- Pees, M., Straub, J. & Krautwald-Junghanns, M., 2001. Insufficiency of the muscular atrioventricular valve in the heart of a blue-fronted amazon (*Amazona aestiva aestiva*). *Vet Rec*, 148(17), pp.540–543.
- Pees, M., Krautwald-Junghanns, M.E. & Straub, J., 2006. Evaluating and treating the cardiovascular system. In G.J. Harrison & T.L. Lightfoot, eds. *Clinical Avian Medicine*. Palm Beach, FL: Spix Publishing, pp. 379–394.
- Pees, M., Straub, J. & Krautwald-Junghanns, M.-E., 2004. Echocardiographic examinations of 60 African grey parrots and 30 other psittacine birds. *Vet Rec*, 155(3), pp.73–76.
- Pees, M. & Krautwald-Junghanns, M.-E., 2009. Cardiovascular physiology and diseases of pet birds. *Vet Clin North Am Exot Anim Pract*, 12(1), pp.81–97, vi.
- Penn, M.S. & Chisolm, G.M., 2005. Lipoprotein oxidation, arterial inflammation, and atherogenesis. In V. Fuster, E. J. Topol, & E. G. Nabel, eds. *Atherothrombosis and coronary artery disease*. Philadelphia, PA: Lippincott Williams & Wilkins, pp. 111–122.
- Pepperberg, I., 2002. *The Alex studies: cognitive and communicative abilities of grey parrots*, Cambridge, MA: Harvard University Press.

- Petzinger, C. et al., 2011. HDL density subfraction alterations and plasma lipids with dietary polyunsaturated fatty acids in *Myiopsitta monachus*. In *Proc Annu Assoc Avian Med.* pp. 297–298.
- Petzinger, C., 2012. *Lipid metabolic effects of dietary N-3 fatty acids on learning ability and potential risk factors for atherosclerosis in Monk parrots (Myiopsitta monachus) and energy needs for growth in this species*. PhD Dissertation. Texas A&M University.
- Petzinger, C. et al., 2010. Dietary modification of omega-3 fatty acids for birds with atherosclerosis. *J Am Vet Med Assoc*, 236(5), pp.523–528.
- Phalen, D.N. et al., 1996. Heart failure in a macaw with atherosclerosis of the aorta and brachiocephalic arteries. *J Am Vet Med Assoc*, 209(8), pp.1435–1440.
- Pick, R. et al., 1952. The inhibition of coronary atherosclerosis by estrogens in cholesterol-fed chicks. *Circulation*, 6(2), pp.276–80.
- Piedrahita, J.A. et al., 1992. Generation of mice carrying a mutant apolipoprotein E gene inactivated by gene targeting in embryonic stem cells. *Proc Nat Acad Sci USA*, 89(10), pp.4471–5.
- Pilny, A.A., 2004. Retrospective of Atherosclerosis in Psittacine Birds: Clinical and Histopathologic Findings in 31 Cases. *Proc Annu Assoc Avian Vet*, pp.349–351.
- Pilny, A.A. et al., 2012. Evaluation of *Chlamydophila psittaci* infection and other risk factors for atherosclerosis in pet psittacine birds. *J Am Vet Med Assoc*, 240(12), pp.1474–80.
- Pinheiro, J.C. & Bates, D.M., 2000. *Mixed-Effects models in S and S-plus* J. C. Pinheiro & D. M. Bates, eds., New York, NY: Springer Verlag.
- Poredos, P., 2001. State-of-the-Art Review: Endothelial Dysfunction in the Pathogenesis of Atherosclerosis. *Clin Appl Thromb Hemost*, 7(4), pp.276–280.
- Prescott, M.F. et al., 1991. Development of complex atherosclerotic lesions in pigs with inherited hyper-LDL cholesterolemia bearing mutant alleles for apolipoprotein B. *Am J Pathol*, 139(1), pp.139–47.
- Prichard, R.W. et al., 1963. Myocardial infarcts in pigeons. *Am J Pathol*, 43, pp.651–9.
- Prichard, R.W. et al., 1964. Pigeon atherosclerosis. *Am Heart J*, 67(5), p.715–&.
- Prichard, R.W. et al., 1962. Studies on the atherosclerotic pigeons. *JAMA*, 179(1), pp.49–52.
- Rabelink, T.J., De Boer, H.C. & Van Zonneveld, A.J., 2010. Endothelial activation and circulating markers of endothelial activation in kidney disease. *Nature reviews. Nephrology*, 6(7), pp.404–14.

- Radcliffe, J.D. & Liebsch, K.S., 1985. Dietary induction of hypercholesterolemia and atherosclerosis in Japanese quail of strain SEA. *J Nutr*, 115(9), pp.1154–1161.
- Rader, D.J., 2005. Plasma High-density lipoproteins and atherogenesis. In V Fuster, E. J. Topol, & E. G. Nabel, eds. *Atherothrombosis and coronary artery disease*. Philadelphia, PA: Lippincott Williams & Wilkins, pp. 95–109.
- Raines, E.W., Libby, P. & Rosenfeld, M.E., 2005. The roles of macrophages. In V. Fuster, E. J. Topol, & E. G. Nabel, eds. *Atherothrombosis and coronary artery disease*. Philadelphia, PA: Lippincott Williams & Wilkins, pp. 505–520.
- Rainwater, D.L. et al., 2009. *The Baboon in Biomedical Research* J. L. VandeBerg, S. Williams-Blangero, & S. D. Tardif, eds., New York, NY: Springer New York.
- Rapacz, J. & Hasler-Rapacz, J., 1989. Animal models: the pig. In A. J. Lusis & S. R. Sparkes, eds. *Genetic factors in atherosclerosis: approaches and model systems*. Basel: Karger, pp. 139–169.
- Rasband, W.S., 1997-2010. *ImageJ 1.43u*. Bethesda, MD: US National Institute of Health, Available online at: <http://rsb.info.nih.gov/ij/> (accessed January 2010).
- Reavill, D.R. & Dorrestein, G.M., 2010. Pathology of aging psittacines. *Vet Clin North Am Exot Anim Pract*, 13(1), pp.135–50.
- Redig, P. & Arent, L., 2008. Raptor toxicology. *Vet Clin North Am Exot Anim Pract*, 11, pp.261–282.
- Reiner, Z. et al., 2011. ESC/EAS Guidelines for the management of dyslipidaemias. *Eur Heart J*, 32, pp.1769–1818.
- Reitman, J.S., Mahley, R W & Fry, D.L., 1982. Yucatan miniature swine as a model for diet-induced atherosclerosis. *Atherosclerosis*, 43(1), pp.119–32.
- Rembert, M.S. et al., 2008. Intermittent bradyarrhythmia in a Hispaniolan Amazon parrot (*Amazona ventralis*). *J Avian Med Surg*, 22(1), pp.31–40.
- Risi, E. et al., 2011. A case of congenital atrial communication and dilated cardiomyopathy on a griffon vulture (*Gyps fulvus*). In *Proc Annu Conf Europ Assoc Avian Vet*. pp. 244–249.
- Robillard, R. et al., 2005. Fibrates. In A. von Eckardstein, ed. *Atherosclerosis: diet and drugs*. Berlin, Heidelberg: Springer Verlag, pp. 389–406.
- Roger, V.L. et al., 2011. Heart disease and stroke statistics--2011 update: a report from the American Heart Association. *Circulation*, 123(4), pp.e18–e209.

- Romagnano, A. et al., 1996. Magnetic resonance imaging of the brain and coelomic cavity of the domestic pigeon (*Columba livia domestica*). *Vet Radiol Ultras*, 37(6), pp.431–440.
- Rosenthal, K. & Miller, M., 1997. Cardiac disease. In R. Altman et al., eds. *Avian medicine and surgery*. Philadelphia, PA: W.B. Saunders Company, pp. 491–500.
- Rosenthal, K. & Stamoulis, M., 1993. Diagnosis of congestive heart failure in an Indian Hill Mynah Bird (*Gracula religiosa*). *J Associ Avian Vet*, 7(1), pp.27–30.
- Ross, R., 1999. Atherosclerosis: an inflammatory disease. *N Engl Med*, 340, pp.115–126.
- Ross, R., Glomset, J. & Harker, L., 1977. Response to injury and atherogenesis. *Am J Pathol*, 86(3), pp.675–684.
- Rubin, D., 2004. *Multiple imputation for nonresponse in surveys* Wiley Clas., New York, NY: Wiley Interscience.
- Ruifrok, A.C. & Johnston, D.A., 2001. Quantification of histochemical staining by color deconvolution. *Analyt Quant Cytol Histol*, 4, 291–299.
- Saito, E.K. et al., 2007. Raptor mortality due to West Nile virus in the United States, 2002. *J Wildl Dis*, 43(2), pp.206–13.
- van Sant, F., 2006. Problem sexual behaviors of companion parrots. In A. Luescher, ed. *Manual of parrot behavior*. Ames, IA: Blackwell Publishing, pp. 233–245.
- Santerre, R.F. et al., 1972. Spontaneous atherosclerosis in pigeons. A model system for studying metabolic parameters associated with atherogenesis. *Am J Pathol*, 67(1), pp.1–22.
- Sanz, J. & Fayad, Z.A., 2008. Imaging of atherosclerotic cardiovascular disease. *Nature*, 451(7181), pp.953–957.
- Scanu, A.M., Khalil, A. & Neven, L., 1988. Genetically determined hypercholesterolemia in a rhesus monkey family due to deficiency of the LDL receptor. *J Lipid Res*, 29(12), pp.1671–1681.
- Schenker, O.A. & Hoop, R.K., 2007. Chlamydiae and atherosclerosis: can psittacine cases support the link? *Avian Dis*, 51(1), pp.8–13.
- Schmaier, A.A. et al., 2011. Occlusive thrombi arise in mammals but not birds in response to arterial injury: evolutionary insight into human cardiovascular disease. *Blood*, 118(13), pp.3661–9.
- Schmidt, R.E., Reavill, D.R. & Phalen, D.N., 2003. Cardiovascular system. In R E Schmidt, Drury R Reavill, & D.N. Phalen, eds. *Pathology of pet and aviary birds*. Ames. IA: Blackwell Publishing, pp. 3–16.

- Schneider, W.J., 2009. Receptor-mediated mechanisms in ovarian follicle and oocyte development. *Gen Comp Endocrinol*, 163(1-2), pp.18–23.
- Schnellbacher, R.W. et al., 2012. Effects of dopamine and dobutamine on isoflurane-induced hypotension in Hispaniolan Amazon parrots (*Amazona ventralis*). *Am J Vet Res*, 73(7), pp.952–8.
- Schroeder, N., 2010. Diuretics. In S. Ettinger & E. Feldman, eds. *Textbook of Veterinary Internal Medicine*. St Louis, MO: Saunders Elsevier, pp. 1212–1214.
- Schulz, K. & Grimes, D., 2002. Case-control studies: research in reverse. *The Lancet*, 359, pp.431–34.
- Schwartz, S.M., Virmani, R. & Rosenfeld, M E, 2000. The good smooth muscle cells in atherosclerosis. *Curr Atheroscler Rep*, 2(5), pp.422–9.
- Schwenke, D.C. & St Clair, R.W., 1993. Influx, efflux, and accumulation of LDL in normal arterial areas and atherosclerotic lesions of white Carneau pigeons with naturally occurring and cholesterol-aggravated aortic atherosclerosis. *Arterioscler Thromb*, 13(9), pp.1368–1381.
- Sedacca, C.D. et al., 2009. Chronic cor pulmonale secondary to pulmonary atherosclerosis in an African Grey parrot. *J Am Vet Med Assoc*, 234(8), pp.1055–9.
- Sessa, R. et al., 2009. Chlamydia pneumoniae and atherosclerosis: current state and future prospectives. *Int J Immunopathol Pharmacol*, 22(1), pp.9–14.
- Shih, J.C.H.H.J. et al., 1983. Genetic selection, general characterization and histology of atherosclerosis-susceptible and -resistant Japanese quail. *Atherosclerosis*, 49(1), pp.41–53.
- Shivaprasad, H.L., 1993. Diseases of the nervous system in pet birds: a review and report of diseases rarely documented. In *Proc Annu Conf Assoc Avian Vet*. pp. 213–222.
- Shropshire, C., Stauber, E. & Arai, M., 1992. Evaluation of selected plants for acute toxicosis in budgerigars. *J Am Vet Med Assoc*, 7(1), pp.936–939.
- Shrout, P. & Fleiss, J., 1979. Intraclass correlations: uses in assessing rater reliability. *Psychol Bull*, 86, pp.420–428.
- Shrubsole-Cockwill, A., Wojnarowicz, C. & Parker, D., 2008. Atherosclerosis and ischemic cardiomyopathy in a captive, adult red-tailed hawk (*Buteo jamaicensis*). *Avian Dis*, 52(3), pp.537–9.
- Siegel, H.S., Hammad, S.M. & Marks, H.L., 1995. Atherosclerosis in Japanese Quail males selected for high or low plasma cholesterol. *Poult Sci*, 74(10), pp.1712–1716.

- Siller, W., 1958. Ventricular septal defects in the fowl. *J Pathol Bacteriol*, 76, pp.431–440.
- Simone-Freilicher, E., 2007. Use of isoxsuprine for treatment of clinical signs associated with presumptive atherosclerosis in a yellow-naped Amazon parrot (*Amazona ochrocephala auropalliata*). *J Avian Med Surg*, 21(3), pp.215–219.
- Simpson, C.F. & Harms, R.H., 1969. Aortic atherosclerosis of turkeys induced by feeding of cholesterol. *J Atheroscler Res*, 10(1), pp.63–75.
- Simpson, C.F., Kling, J.M. & Palmer, R.F., 1970. Beta-aminopropionitrile-induced dissecting aneurysms of turkeys: treatment with propranolol. *Toxicol Appl Pharmacol*, 16(1), pp.143–53.
- Singh, V. et al., 2009. Models to study atherosclerosis: a mechanistic insight. *Cur Vasc Pharm*, 7, pp.75–109.
- Sipahi, I. et al., 2007. β -Blockers and Progression of Coronary Atherosclerosis: Pooled Analysis of 4 Intravascular Ultrasonography Trials. *Ann Intern Med*, 147(1), pp.10–18.
- Sisson, D., 2010. Pathophysiology of heart failure. In S. Ettinger & E. Feldman, eds. *Textbook of Veterinary Internal Medicine*. 2010: Saunders Elsevier, pp. 1143–1158.
- Sitia, S. et al., 2010. From endothelial dysfunction to atherosclerosis. *Autoimmunity Reviews*, 9(12), pp.830–4.
- Smith, F.M., West, N.H. & Jones, D.R., 2000. The cardiovascular system. In G. C. Whittow, ed. *Sturkie's Avian Physiology*. London: Academic Press, pp. 141–232.
- Smith, S.C., Blair, S.N., et al., 2001. AHA/ACC Guidelines for Preventing Heart Attack and Death in Patients With Atherosclerotic Cardiovascular Disease: 2001 update. A statement for healthcare professionals from the American Heart Association and the American College of Cardiology. *J Am Coll Cardiol*, 38(5), pp.1581–3.
- Smith, S.C. et al., 2008. Differentially expressed soluble proteins in aortic cells from atherosclerosis-susceptible and resistant pigeons. *Poultry Sci*, 87(7), pp.1328–34.
- Smith, S.C., Smith, E.C. & Taylor, R.L., 2001. Susceptibility to spontaneous atherosclerosis in pigeons: an autosomal recessive trait. *J Heredity*, 92(5), pp.439–442.
- Smith, S.C. et al., 2011. AHA/ACCF Secondary Prevention and Risk Reduction Therapy for Patients with Coronary and other Atherosclerotic Vascular Disease: 2011 update: a guideline from the American Heart Association and American College of Cardiology Foundation. *Circulation*, 124(22), pp.2458–73.
- Snyder, N., McGowan, P. & Gilardi, P., 2000. *Parrots. Status Survey and Conservation Action Plan 2000–2004*, Gland, Switzerland and Cambridge, UK: IUCN.

- Song, S.H. & Roach, M.R., 1998. Surface features of human aortic atherosclerosis as seen with scanning electron microscopy. *Yonsei medical journal*, 39(5), pp.430–8.
- Speckmann, E.W. & Ringer, R.K., 1963. The cardiac output and carotid and tibial blood pressure of the turkey. *Canadian J Biochem Physiol*, 41(11), pp.2337-2341.
- Spence, J.D., Jenkins, D.J.A. & Davignon, J., 2012. Egg yolk consumption and carotid plaque. *Atherosclerosis*, 224(2), pp.469–73.
- St Clair, R.W., 1983. Metabolic changes in the arterial wall associated with atherosclerosis in the pigeon. *Federation Proceedings*, 42(8), pp.2480–5.
- St Clair, R.W., 1998. The contribution of avian models to our understanding of atherosclerosis and their promise for the future. *Lab Anim Sci*, 48(6), pp.565–568.
- Stanford, M., 2005. Significance of cholesterol assays in the investigation of hepatic lipidosis and atherosclerosis in psittacine birds. *ExoticDVM*, 7(3), pp.28–34.
- Starokadomsky, L.M. & Ssoblew, L.W., 1909. Zur frage der experimentelle arteriosklerose. *Frankf. Ztschr. F. Pathol.*, 3, pp.912–925.
- Sary, H., 2003a. *Atlas of atherosclerosis: Progression and regression*, New York, NY: Parthenon Publishing Group.
- Sary, H., 2003b. Phase of clinically important lesions. In H. C. Sary, ed. *Atlas of atherosclerosis: progression and regression*. New York, NY: The Parthenon Publishing Group Inc., pp. 25–31.
- Sary, H., 2003c. Terminologies in atherosclerosis and classification of lesions according to their pathways of development. In H. Sary, ed. *Atlas of atherosclerosis: progression and regression*. New York, NY: The Parthenon Publishing Group Inc., pp. 16–18.
- Sary, H.C. et al., 1995. A definition of advanced types of atherosclerotic lesions and a histological classification of atherosclerosis. A report from the Committee on Vascular Lesions of the Council on Arteriosclerosis, American Heart Association . *Circulation*, 92, pp.1355–1374.
- Sary, H.C. et al., 1994. A definition of initial, fatty streak, and intermediate lesions of atherosclerosis. A report from the Committee on vascular lesions of the Council on Arteriosclerosis, American Heart Association. *Arterioscler Thromb Vasc Biol*, 14, pp.840–856.
- Sary, H.C. et al., 1992. A definition of the intima of human arteries and of its atherosclerosis-prone regions. A report from the Committee on Vascular Lesions of the Council on Arteriosclerosis, American Heart Association. *Arterioscler Thromb Vasc Biol*, 12, pp.120–134.

- Stary, H.C., 2005. Histologic classification of human atherosclerosis lesions. In V Fuster, E. Topol, & E. Nabel, eds. *Atherothrombosis and coronary artery disease*. Philadelphia, PA: Lippincott Williams & Wilkins, pp. 441–449.
- Stary, H.C., 2000. Natural history and histological classification of atherosclerotic lesions. *Arterioscler Thromb Vasc Biol*, 20, p.1177.
- Stevens, L., 1996. Lipids and their metabolism. In L. Stevens, ed. *Avian biochemistry and molecular biology*. Cambridge, UK: Cambridge University Press, pp. 46–64.
- Still, W.J., 1963. An electron microscope study of cholesterol atherosclerosis in the rabbit. *Exp Mol Pathol*, 14, pp.491–502.
- St Leger J., 2003. Acute aortic rupture in Antarctic penguins. In *Proc Am Assoc Zoo Vet*.
- St Leger, J., 2007. Avian atherosclerosis. In M. E. Fowler & R. E. Miller, eds. *Zoo and wild animal medicine Current Therapy*. Saunders, pp. 200–205.
- Stocker, R. & Keaney, J.F., 2005. Oxidative stress and atherosclerosis. In J. Loscalzo, ed. *Molecular mechanisms of atherosclerosis*2. Abington, UK: Taylor & Francis, pp. 61–83.
- Stout, L.C. & Thorpe, L.W., 1980. Histology of normal aortas in birds with emphasis on intimal thickening. *Atherosclerosis*, 36, pp.545–558.
- Straub, J., 2003. Effect of handling-induced stress on the results of spectral Doppler echocardiography in falcons. *Res Vet Sci*, 74(2), pp.119–122.
- Straub, J. et al., 2003. Pericardiocentesis and the use of enalapril in a Fischer's lovebird (*Agapornis fischeri*). *Vet Rec*, 152, pp.24–26.
- Straub, J. et al., 2004. Pulsed-wave Doppler-derived velocity of diastolic ventricular inflow and systolic aortic outflow in raptors. *Vet Rec*, 154(5), pp.145–7.
- Straub, J., Pees, M. & Krautwald-Junghanns, M.-E., 2002. Measurement of the cardiac silhouette in psittacines. *J Am Vet Med Assoc*, 221(1), pp.76–79.
- Straub, J. et al., 2003. The effects of isoflurane anaesthesia on some Doppler-derived cardiac parameters in the common buzzard (*Buteo buteo*). *Vet J*, 166(3), pp.273–276.
- Sturkie, P., 1976. Heart: contraction, conduction, and electrocardiography. In P. Sturkie, ed. *Avian Physiology*. New York, NY: Springer Verlag, pp. 103–121.
- Subbiah, M.T.R., Kottke, B.A. & Carlo, I.A., 1970. Experimental studies in spontaneous atherosclerosis susceptible white carneau pigeon – nature of biliary and fecal neutral steroids. *Mayo Clin Proc*, 45(10), p.729–&.

- Suckling, K.E. & Jackson, B., 1993. Animal models of human lipid metabolism. *Prog Lipid Res*, 32(1), pp.1–24.
- Summerfield, N.J. et al., 2012. Efficacy of Pimobendan in the Prevention of Congestive Heart Failure or Sudden Death in Doberman Pinschers with Preclinical Dilated Cardiomyopathy (The PROTECT Study). *J Vet Intern Med*, 26(6), pp.1337–49.
- Suzuki, S. et al., 2004. Measurement of vascular diameter in vitro by automated software for CT angiography: effects of inner diameter, density of contrast medium, and convolution kernel. *Am J Roentgenol*, 182(5), pp.1313–7.
- Szmitko, P.E. et al., 2003. New markers of inflammation and endothelial cell activation: Part I. *Circulation*, 108(16), pp.1917–23.
- Taatjes, D.J. et al., 2000. Improved quantitative characterization of atherosclerotic plaque composition with immunohistochemistry, confocal fluorescence microscopy, and computer-assisted image analysis. *Histochemistry and cell biology*, 113(3), pp.161–73.
- Takahashi, K., Takeya, M. & Sakashita, N., 2002. Multifunctional roles of macrophages in the development and progression of atherosclerosis in humans and experimental animals. *Med Electron Microsc*, 35, pp.179–203.
- Talayero, B.G. & Sacks, F.M., 2011. The role of triglycerides in atherosclerosis. *Cur Cardiol Rep*, 13(6), pp.544–52.
- Tall, A. et al., 1987. Accelerated transfer of cholesteryl esters in dyslipidemic plasma: role of cholesteryl ester transfer protein. *J Clin Invest*, 79, pp.1217–1225.
- Taylor, M., 1994. Endoscopic examination and biopsy techniques. In B. Ritchie, G.J. Harrison, & L.R. Harrison, eds. *Avian Medicine: Principles and Applications*. Lake Worth, FL: Wingers Publishing, pp. 327–354.
- Taylor, R.G. & Lewis, J C, 1986. Endothelial cell proliferation and monocyte adhesion to atherosclerotic lesions of white carneau pigeons. *Am J Pathol*, 125(1), pp.152–160.
- Thomas, W.P. et al., 1993. Recommendations for standards in transthoracic two-dimensional echocardiography in the dog and cat. Echocardiography Committee of the Specialty of Cardiology, American College of Veterinary Internal Medicine. *J Vet Intern Med*, 7(4), pp.247–52.
- Thompson, K.H. & Zilversmit, D.B., 1983. Plasma very low density lipoprotein (VLDL) in cholesterol-fed rabbits: chylomicron remnants or liver lipoproteins? *J Nutr*, 113(10), pp.2002–10.
- Tidholm, A., Svensson, H. & Sylvén, C., 1997. Survival and prognostic factors in 189 dogs with dilated cardiomyopathy. *J Am Anim Hosp Assoc*, 33(4), pp.364–8.

- Toda, T., 1988. Immunohistochemical and ultrastructural study of aortic lesions in fat-fed quails. *Jikken Dobutsu*, 37(2), pp.179–185.
- Toda, T., Leszczynski, D. & Kummerow, F., 1981. Vasculotoxic effects of dietary testosterone, estradiol, and cholesterol on chick artery. *J Pathol*, 134(3), pp.219–31.
- Toda, T., Toda, Y. & Kummerow, F.A., 1984. Electron microscopic comparison of the tunica media of the thoracic aorta between species. *Tohoku J Exp Med*, 143(2), pp.141–7.
- Touzot-Jourde, G., Hernandez-Divers, S.J. & Trim, C.M., 2005. Cardiopulmonary effects of controlled versus spontaneous ventilation in pigeons anesthetized for coelioscopy. *J Am Vet Med Assoc*, 227(9), pp.1424–8.
- Vanhooser, S.L. et al., 1994. Aortic rupture in ostrich associated with copper deficiency. *Vet Human Toxicol*, 36(3), pp.226–7.
- Velleman, S.G. et al., 2001. Collagen characteristics and organization during the progression of cholesterol-induced atherosclerosis in Japanese quail. *Exp Biol Med*, 226(4), pp.328–333.
- Vilahur, G., Padro, T. & Badimon, Lina, 2011. Atherosclerosis and thrombosis: insights from large animal models. *J Biomed Biotechnol*, 2011, p.907575.
- Vink-Nooteboom, M. et al., 1998. Clinical diagnosis of aneurysm of the right coronary artery in a white cockatoo (*Cacatua alba*). *J Small Anim Pract*, 39(11), pp.533–537.
- Virmani, R. et al., 2000. Lessons from sudden coronary death: a comprehensive morphological classification scheme for atherosclerotic lesions. *Arterioscler Thromb Vasc Biol*, 20, pp.1262–1275.
- von Eckardstein, A., 2005. Risk factors for atherosclerotic vascular disease. In A. vonEckardstein, ed. *Atherosclerosis: diet and drugs*. Berlin, Germany: Springer, pp. 71–105.
- Walski, M. et al., 2002. Ultrastructural alterations of endothelium covering advanced atherosclerotic plaque in human carotid artery visualised by scanning electron microscope. *J Physiol Pharmacol*, 53(4 Pt 1), pp.713–23.
- Walzem, R.L. et al., 1999. Estrogen induction of VLDL assembly in egg-laying hens. *J Nutr*, 129(2S Suppl), p.467S–472S.
- Wamhoff, B.R., Kumar, M.S. & Owens, G.K., 2005. Role of alterations in the differentiated state of smooth muscle cell in atherothrombogenesis. In V. Fuster, E. J. Topol, & E. G. Nabel, eds. *Atherothrombosis and coronary artery disease*. Philadelphia, PA: Lippincott Williams & Wilkins, pp. 401–419.

- Watanabe, Y., 1980. Serial inbreeding of rabbits with hereditary hyperlipidemia (WHHL-rabbit). *Atherosclerosis*, 36(2), pp.261–8.
- Watson, C. & Alp, N.J., 2008. Role of *Chlamydia pneumoniae* in atherosclerosis. *Clin Sci*, 114(8), pp.509–31.
- Weber, G. et al., 1977. Regression of arteriosclerotic lesions in rhesus monkey aortas after regression diet. Scanning and transmission electron microscope observations of the endothelium. *Atherosclerosis*, 26(4), pp.535–47.
- Weintraub, W.S. et al., 2011. Value of primordial and primary prevention for cardiovascular disease: a policy statement from the American Heart Association. *Circulation*, 124(8), pp.967–90.
- Weiss, D., Kools, J.J. & Taylor, W R, 2001. Angiotensin II-induced hypertension accelerates the development of atherosclerosis in apoE-deficient mice. *Circulation*, 103(3), pp.448–54.
- Weiss, D. & Taylor, W.R., 2008. Deoxycorticosterone acetate salt hypertension in apolipoprotein E-/- mice results in accelerated atherosclerosis: the role of angiotensin II. *Hypertension*, 51(2), pp.218–24.
- Wennberg, P. & Rooke, T., 2005. Diagnosis and management of diseases of the peripheral arteries and veins. In V Fuster, E. Topol, & E. Nabel, eds. *Atherothrombosis and coronary artery disease*. Philadelphia, PA: Lippincott Williams & Wilkins, pp. 1525–1541.
- West, K.L., Kern, T.L. & Fernandez, M.L., 2003. SC-435 an ileal apical sodium co-dependent bile acid transporter (ASBT) inhibitor lowers plasma cholesterol and reduces atherosclerosis in guinea pigs. *Atherosclerosis*, 171, pp.201–210.
- West, N., Langille, B. & Jones, DR, 1981. Cardiovascular system. In A. King & J McLelland, eds. *Form and Function in Birds. Volume 2*. London: Academic Press, pp. 235–339.
- Westerhof, I., Van de Wal, M. & Lumiej, J., 2011. Electrocardiographic changes in a galah (*Eolophus roseicapilla*) with lead poisoning. In *Proc Annu Conf Europ Assoc Avian Vet*. pp. 59–60.
- Wheeler, M.T. & McNally, E.M., 2005. The interaction of coronary tone and cardiac fibrosis. *Cur Atheroscler Rep*, 7(3), pp.219–26.
- White, C., 2002. A review of the pharmacologic and pharmacokinetic aspects of rosuvastatin. *J. Clin. Pharmacol.*, 42(9), pp.963–970.
- WHO, 2012. World Health Statistics. *WHO Library*.
- WHO, 2011. *Global atlas on cardiovascular disease prevention and control* S. Mendis, P. Puska, & B. Norrving, eds., Geneva: World Health Organization.

- WHO, 2007. *Prevention of cardiovascular disease: guidelines for assessment and management of cardiovascular risk*, Geneva: World Health Organization.
- Wight, T., Heinegard, D. & Hascall, V., 1991. Proteoglycans: structure and function. In E. Hay, ed. *Cell biology of extracellular matrix*. New York, NY: Plenum Press.
- Wight, T.N., 2005. The vascular extracellular matrix. In V. Fuster, E. J. Topol, & E. G. Nabel, eds. *Atherothrombosis and coronary artery disease*. Philadelphia, PA: Lippincott Williams & Wilkins, pp. 421–437.
- Wight, T.N., Cooke, P.H. & Smith, Samuel C., 1977. An electron microscopic study of pigeon aorta cell cultures. *Exp Mol Pathol*, 27(1), pp.1–18.
- Williams, K.J. & Tabas, I, 1998. The response-to-retention hypothesis of atherogenesis reinforced. *Curr Opinion Lipidol*, 9(5), pp.471–4.
- Wilson, P.W.F., 2005. The epidemiology of atherosclerotic disease. In J. Loscalzo, ed. *Molecular mechanisms of atherosclerosis*. Abingdon, UK: Taylor & Francis, pp. 3–28.
- Wilson, R. et al., 1989. Single dose digoxin pharmacokinetics in the Quaker conure (*Myiopsitta monachus*). *J Zoo Wildl Med*, 20(4), pp.432–434.
- Wood, D. et al., 1998. Prevention of coronary heart disease in clinical practice: recommendations of the second joint task force of European and other Societies on coronary prevention. *Eur Heart J*, 19, pp.1434–1503.
- Woollard, K.J. & Geissmann, F., 2010. Monocytes in atherosclerosis: subsets and functions. *Nature Reviews*, 7, pp.77–87.
- Worthley, S.G. et al., 2000. Serial in vivo MRI documents arterial remodeling in experimental atherosclerosis. *Circulation*, 101(6), pp.586–9.
- Wu, T.C. & Donaldson, W.E., 1982. Effect of cholesterol feeding on serum lipoproteins and atherosclerosis in atherosclerosis-susceptible and atherosclerosis-resistant Japanese quail. *Poult Sci*, 61(12), pp.2407–2414.
- Xiangdong, L. et al., 2011. Animal models for the atherosclerosis research: a review. *Protein & cell*, 2(3), pp.189–201.
- Xiao, Q., 2010. Genetically manipulated models of atherosclerosis in mice. In A.F. Drew, ed. *Atherosclerosis: experimental methods and protocols*. Philadelphia, PA: Humana Press Inc., pp. 15–26.
- Yamamoto, K. & Igawa, T., 1991. Ultrastructural and immunohistochemical study of experimental atherosclerosis in Japanese quails. *Jikken Dobutsu*, 40(2), pp.173–182.

- Yanni, A.E., 2004. The laboratory rabbit: an animal model of atherosclerosis research. *Lab Anim*, 38(3), pp.246–256.
- Zaikina, O.E. et al., 1982. Quantitative SEM analysis of injury to the endothelium of rabbit aorta and carotid artery during experimental atherosclerosis. *Atherosclerosis*, 41(2-3), pp.141–54.
- Zandvliet, M.J.M.J., 2005. Electrocardiography in psittacine birds and ferrets. *Sem Avian Exot Pets*, 14(1), pp.34–51.
- Zandvliet, M.M.J.M., Dorrestein, G. & Van Der Hage, M., 2001. Chronic pulmonary interstitial fibrosis in Amazon parrots. *Avian Pathol*, 30(5), pp.517–524.
- Zannis, V.I. et al., 2005. Lipoproteins and atherogenesis. In J. Loscalzo, ed. *Molecular mechanisms of atherosclerosis*. Abington, UK: Taylor & Francis, pp. 111–174.
- Van Zeeland, Y., Schoemaker, N. & Lumeij, J., 2010. Syncope associated with second degree atrioventricular block in a cockatoo. In *Proc Annu Conf Assoc Avian Vet*. pp. 345–346.
- Zehnder, A.M. et al., 2009. Evaluation of indirect blood pressure monitoring in awake and anesthetized red-tailed hawks (*Buteo jamaicensis*): effects of cuff size, cuff placement, and monitoring equipment. *V Anesth Analg*, 36(5), pp.464–79.

APPENDIX 1: LETTER OF PERMISSION FROM AVIAN PATHOLOGY



RightsLink®

Home

Account
Info

Help



Title: Characterization and classification of psittacine atherosclerotic lesions by histopathology, digital image analysis, transmission and scanning electron microscopy

Author: Hugues Beaufrère, Javier G. Nevarez, Kali Holder et al.

Publication: Avian Pathology

Publisher: Taylor & Francis

Date: Oct 1, 2011

Copyright © 2011 Taylor & Francis

Logged in as:
Hugues Beaufrère
Account #:
3000327322

LOGOUT

Thesis/Dissertation Reuse Request

Taylor & Francis is pleased to offer reuses of its content for a thesis or dissertation free of charge contingent on resubmission of permission request if work is published.

BACK

CLOSE WINDOW

Copyright © 2013 [Copyright Clearance Center, Inc.](#) All Rights Reserved. [Privacy statement.](#)
Comments? We would like to hear from you. E-mail us at customercare@copyright.com

APPENDIX 2: LETTER OF PERMISSION FROM THE AMERICAN VETERINARY MEDICAL ASSOCIATION



AVMA

American Veterinary Medical Association

Diane A Fagen, Librarian
Copyright & Permissions
1931 N. Meacham Rd.
Suite 100
Schaumburg, IL
60173-4360
phone 800.248.2862
fax 847.925.9329

Thursday 24 January 2013

Hugues Beaufrere, Dr.Med.Vet.
Diplomate ABVP (Avian), ECZM (Avian)
Graduate Assistant, Zoological Medicine
School of Veterinary Medicine
Louisiana State University, USA

Dear Dr Beaufrere:

Thank you for your letter, which is reproduced, below, in olive-green-colored font:

I would like to ask the permissions to reproduce two of my articles in my upcoming PhD dissertation. One is already published in AJVR and one is accepted for publication in JAVMA:

Beaufrère H, Ammersbach M, Reavill D, Garner M, Heatley J, Wakamatsu N, Nevarez J, Tully T. Prevalence and risk factors in psittacine atherosclerosis: a multicenter case-control study. *J Am Vet Med Assoc*, accepted for publication, 10/2012.

Permission granted for this use, including deposit of the dissertation with ProQuest, and on the Louisiana State University repository, provided the embargo of 13 months from the date of publication in JAVMA is observed (which will allow you to gain the benefit of royalties from any sales of your dissertation, provided you have retained copyright in the dissertation). Thank you for correctly noting that the manuscript is "accepted for publication".

Beaufrère H, Rodriguez D, Pariaut R, Gaschen L, Schnellbacher R, Nevarez J, Tully T. Estimating intrathoracic arterial diameter using CT angiography in Hispaniolan Amazon parrots (*Amazona ventralis*). *Am J Vet Res* 2011; 72(2): 210-218.

Permission granted for this use, including deposit of the dissertation with ProQuest, and on the Louisiana State University repository, provided the embargo of 13 months from the date of publication in AJVR is observed (which will allow you to provide it prior to the two-year period you have specified, if it is published sooner).

Congratulations on your achievement, and thank you for your commitment to animal health.

Best regards,

American Veterinary Medical Association

Diane A Fagen, Copyright & Permissions

APPENDIX 3: LETTER OF PERMISSION FROM VETERINARY PATHOLOGY



Veterinary Pathology
The American College of Veterinary Pathologists™

ACVP, Editor-in-Chief

Dr. Carl Alden
Millennium Pharmaceuticals

ECVP Editor

Dr. Andrea Groene
University of Utrecht

JCVP Editor

Dr. Toshiharu Hayashi
Yamaguchi University

Section Editors

Dr. Margaret Miller
Domestic Animals

Dr. Matti Kiupel
Oncology

Dr. Joaquim Segales
Infectious Disease

Dr. Makoto Shibutani
Other Diseases
& Laboratory Medicine

Dr. Jerrold Ward
Laboratory Animals

Dr. David Swayne
Poultry

Dr. Judith St. Leger
Wildlife, Marine
and Zoo Animals

Dr. Rani Sellers
Animal Models

Dr. Robert Sills
Environmental Pathobiology

Dr. Catherine George
Pharmaceutical Pathobiology

Dr. Kunitoshi Mitsumori
Pharmaceutical Pathobiology

Dr. Trent Schoeb
Diagnostic Exercise

Dr. Piper Treuting
Book Reviews

eVetPath Editor

Dr. Mark Mense

Images

Dr. Deborah Gillette

Dr. Diane Gunson

Dr. Silvia Ferro

January 16, 2013

To Whom it May Concern:

Please let it be known that per *Veterinary Pathology's* "Exclusive License to Publish" agreement, Dr. Hugues Beaufrere may use his manuscript "Experimental Diet-Induced Atherosclerosis in Quaker Parrots (*Myiopsitta monachus*)" to share with research colleagues at any time.

Sincerely,

Jill Findlay

Managing Editor

VITA

Dr. Hugues Beaufrère received his doctorate in veterinary medicine from the University of Lyon, France in 2006. He then completed a small animal internship in a private practice in Belgium in 2007 followed by an avian and exotic medicine internship at the Ontario Veterinary College in Canada the following year. Following his internships, Dr. Beaufrère enrolled into a combined PhD and Zoological Medicine Residency program in the Department of Veterinary Clinical Sciences at the School of Veterinary Medicine – Louisiana State University. His PhD program included a minor in Applied Statistics with the Department of Experimental Statistics at the same University. In 2012, Dr. Beaufrère became board certified in avian medicine both in Europe through the European College of Zoological Medicine (Avian) and in North America through the American Board of Veterinary Practitioners – Avian Practice.

Dr. Beaufrère's research and clinical interests include avian cardiovascular diseases, raptor orthopedics, psittacine internal medicine, and veterinary biostatistics.