

1-1-2000

Differentiation of gastrointestinal diseases of calves

C. B. Navarre

Auburn University College of Veterinary Medicine

E. B. Belknap

Auburn University College of Veterinary Medicine

S. E. Rowe

Auburn University College of Veterinary Medicine

Follow this and additional works at: https://digitalcommons.lsu.edu/animalsciences_pubs

Recommended Citation

Navarre, C., Belknap, E., & Rowe, S. (2000). Differentiation of gastrointestinal diseases of calves. *The Veterinary clinics of North America. Food animal practice*, 16 (1), 37-57. [https://doi.org/10.1016/S0749-0720\(15\)30136-5](https://doi.org/10.1016/S0749-0720(15)30136-5)

This Article is brought to you for free and open access by the School of Animal Sciences at LSU Digital Commons. It has been accepted for inclusion in Faculty Publications by an authorized administrator of LSU Digital Commons. For more information, please contact ir@lsu.edu.

DIFFERENTIATION OF GASTROINTESTINAL DISEASES OF CALVES

Christine B. Navarre, DVM, MS, Ellen B. Belknap, DVM, MS,
and Sara E. Rowe, DVM, MS

Bovine practitioners are commonly faced with gastrointestinal problems in calves. Although diarrhea is undoubtedly the most common problem, diseases of the forestomachs, abomasum, and intestines also occur. Being able to properly diagnose gastrointestinal problems is pivotal in developing proper preventive and treatment strategies. This article discusses the common gastrointestinal diseases, including diarrhea, of calves, with a focus on diagnosis and differentiation of these diseases. The article is divided into differentiation of the causes of abdominal distension, and the causes of diarrhea. Only the gastrointestinal causes of abdominal distension are discussed, with the focus placed on antemortem diagnosis. The reader is referred to other publications for treatment and prevention.

ABDOMINAL DISTENSION

As with all other disease investigations, a thorough history is essential in diagnosing the causes of abdominal distension. Especially important is the feeding history, because diet is a major contributor to forestomach diseases. The number and age of calves affected is also important.

From the Department of Large Animal Surgery and Medicine, Auburn University College of Veterinary Medicine (CBN, EBB); and the State of Alabama Veterinary Diagnostic Laboratory (SER), Auburn, Alabama

VETERINARY CLINICS OF NORTH AMERICA:
FOOD ANIMAL PRACTICE

A general physical examination, including body condition, hair coat condition, and evaluation of the cardiovascular and respiratory systems, combined with a good history, helps differentiate chronic from acute problems. A more thorough examination of the gastrointestinal system is then necessary. As with adult cattle, abdominal contour is important. Abdominal distension can be divided into left-sided, right-sided, and bilateral distension. This method of classification allows the clinician to narrow the list of differential diagnoses and appropriately focus diagnostic techniques. Abdominal palpation, auscultation, percussion, and succussion are needed to differentiate fluid versus gas distension. The consistency and presence or absence of the feces is also important. Rectal palpation is not possible in calves, which makes formulating a diagnosis more challenging.

Finally, diagnostic techniques such as rumen fluid analysis, abdominocentesis, radiography, ultrasonography, endoscopy, laparoscopy, and possibly exploratory surgery may be necessary. Clinicopathologic data rarely help in arriving at a diagnosis but may be valuable for prognosis and treatment. These diagnostics, combined with a careful history and physical examination, allow the practitioner to differentiate the causes of abdominal distension.

The reader is referred to the article on "Differentiation of Gastrointestinal Diseases of Adult Cattle" elsewhere in this issue for details of diagnostic techniques. In most cases, the techniques and interpretation of results are the same in calves as they are in adult cattle. It should be mentioned that peritoneal fluid analysis does differ slightly in calves. Calves may have lower eosinophil and higher mononuclear and nucleated peritoneal fluid cell counts as compared to cows.⁴ The technique for collection of peritoneal fluid is also different in calves. Calves should be adequately restrained either standing or in lateral recumbency, with sedation if necessary, and fluid collected from the ventral midline cranial to the umbilicus.⁴ Differences in interpretation of other techniques are discussed in the appropriate sections.

LEFT-SIDED ABDOMINAL DISTENSION

Left-sided abdominal distension is most commonly caused by diseases of the rumen, but left displaced abomasum and omental bursitis (discussed under abomasal ulcers) should also be considered. The rumen normally occupies the left side of the abdomen, and mild to moderate distension, especially gas distension, causes only left-sided distension. If a significant amount of feed material or fluid accumulates ventrally, however, the ventral sac distends and can occupy enough of the right side of the abdomen to cause bilateral ventral abdominal distension.

Recurrent Bloat

Recurrent bloat in calves is a chronic, intermittent accumulation of free gas in the rumen and is an indication of an underlying primary

problem. Depending on what the primary problem is, the abdominal distension can range from only gas distension of the left dorsal quadrant (Fig. 1) to left dorsal combined with bilateral ventral abdominal distension (Fig. 2). Figure 3 demonstrates one way of differentiating the following causes of recurrent bloat and left-sided abdominal distension. The primary problem must be diagnosed and treated before the recurrent bloat will subside. Although most of these problems have a poor prognosis, usually only one calf is affected despite uniform management of other calves in the herd.

Trichobezoars

Young calves that are fed diets lacking adequate amounts of fiber may lick their hair excessively, predisposing them to rumen trichobezoars.^{43, 48} Trichobezoars are rarely a problem in themselves but can occasionally cause obstructions and irritation predisposing to secondary rumen wall infections and recurrent bloat.^{24, 43, 46} They can some-

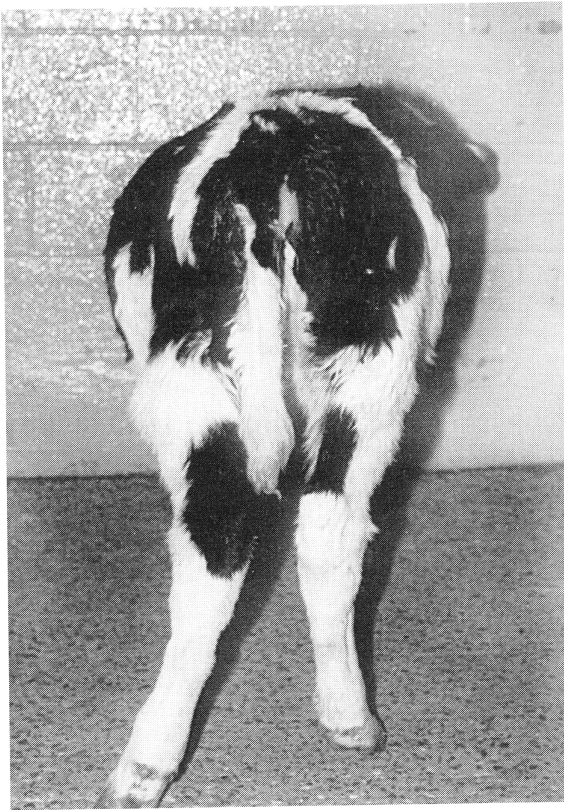

Figure 1. A calf with left-sided abdominal distension caused by gas bloat of the rumen.

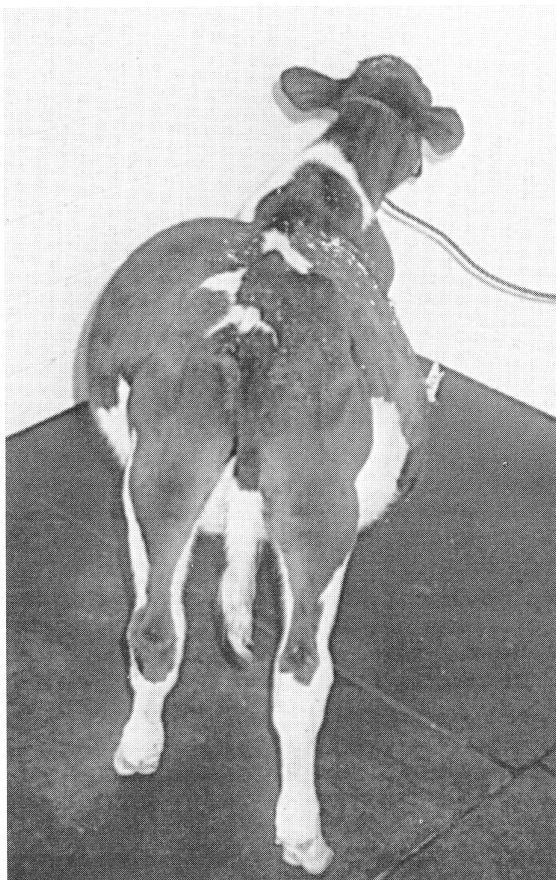


Figure 2. A calf with abdominal distension of the left dorsal and left and right ventral quadrants caused by severe fluid distension of the ventral rumen with dorsal rumen gas distension.

times be detected in the rumen by careful palpation through the abdominal wall or radiography.⁴⁶

Rumenitis

Mechanical (trichobezoars) and chemical (chronic rumen acidosis) irritation of the rumen can cause rumenitis and recurrent bloat. This irritation can then predispose to secondary bacterial (primarily *Fusobacterium necrophorum*) and fungal (*Mucor sp.*, *Rhizopus sp.*) infections of the rumen wall.^{24, 43} Primary viral infections of the rumen (infectious bovine rhinotracheitis virus, adenovirus, and bovine viral diarrhea virus) are uncommon but also can occur.⁴³ These bacterial, fungal, and viral infec-

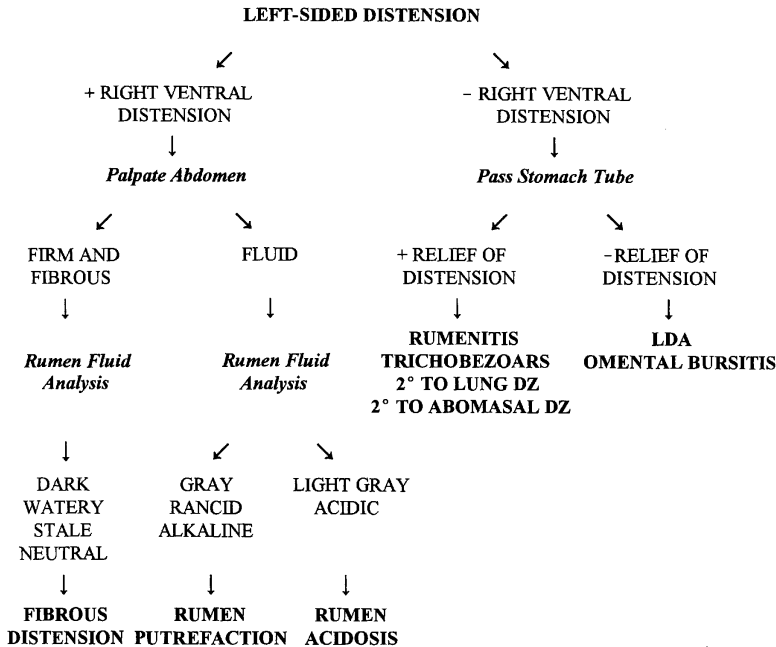


Figure 3. Differentiating the causes of left-sided abdominal distension in calves. DZ = disease; LDA = left displaced abomasum.

tions should be considered in a differential diagnosis of recurrent bloat. Antemortem diagnosis of these infectious causes of rumenitis can be difficult. Occasionally fungal organisms can be found on a stained rumen fluid smear, but most are diagnosed at necropsy.

Fibrous Distension of the Rumen

Poor development of the rumen microbial population and motility can result in recurrent bloat. This occurs when diets are high in poor quality fiber and lack adequate amounts of protein and energy. This leads to a lack of cellulolytic microflora, so roughages go undigested and begin to accumulate in the rumen.^{24, 43} These calves have poor growth rates and rough hair coats. Calves remain hungry and continue to eat roughage, in some cases overeating. The rumen becomes increasingly larger, causing abdominal distension of the left ventral quadrant, and if severe, the right ventral quadrant. If secondary recurrent bloat occurs, the left dorsal quadrant is also distended. The rumen contents are palpably firm ventrally. The feces vary from thin to pasty or dry, and undigested plant material may be noted.²⁴ Rumen fluid collected by orogastric tube or rumenocentesis reveals dark brown to black watery fluid that smells stale or like feces, has few to no protozoa, a neutral

pH, a prolonged methylene blue reduction, and shortened sedimentation rate.^{24, 30}

Chronic Rumen Acidosis

On the other end of the spectrum are calves fed high concentrate diets with little or no effective fiber, or calves that are chronically tube-fed milk.^{10, 21, 43} Excess production of butyrate and propionate and chronic rumen acidosis leads to the development of rumen hyperkeratosis/parakeratosis.^{30, 43} These calves have similar body contour, body condition, and hair coat condition as the previously described calves. They may crave fiber, lick their hair, and chew on wood. Feces are usually loose. Rumen fluid is light gray and acidic, and the methylene blue reduction time may be decreased.²⁴

Rumen Putrefaction

Sometimes called rumen drinkers, calves with chronic milk accumulation in the rumen develop rumen putrefaction. Milk accumulates in the rumen by escaping from the esophageal groove as it flows to the abomasum or by reflux from the abomasum.⁴³ Poor quality milk replacers (nonmilk protein replacers), spoiled or unpalatable milk replacers, bucket feeding, feeding milk or milk replacers cold, and illness can cause poor esophageal groove closure and accumulation of milk in the rumen.^{13, 30, 34} Normal weakening of the groove closure as calves get older can lead to problems in older veal calves.⁴⁸ Chronic tube feeding of milk also leads to accumulation of milk in the rumen as esophageal groove closure is not stimulated adequately.^{13, 21} Overfeeding of milk (>5% of body weight at one time), inhibition of abomasal motility (very acidic and hypertonic solutions, abomasal inflammation), and failure of curd formation (nonmilk protein replacers, alkaline solutions) can lead to abomasal reflux of milk into the rumen.^{10, 20, 30, 34, 63} With chronic milk accumulation in the rumen, proteolytic bacteria are selected for in the rumen, which leads to putrefactive decomposition of the milk and rancid rumen ingesta. Spoiled or contaminated feeds and poor hygiene in general can magnify the problem.^{24, 30, 43}

The nutritional benefits of milk are lost after putrefactive decomposition, and calves fail to grow properly. They have poor hair coats, may lick their hair excessively, and have decreased appetites.^{10, 31} The abdomen is distended ventrally on both sides with fluid and dorsally with gas on the left if recurrent bloat occurs. Rumen contractions are weak or absent. Auscultation during milk drinking and succussion reveals splashing and tinkling sounds.^{10, 31} The feces are usually pasty or claylike, but chronic diarrhea can occur.^{10, 43, 48} The rumen fluid smells rancid, is grayish-brown, and may contain curdled milk.¹⁰ The pH is usually alkaline, but may be acidic in calves less than 2 weeks old.³¹ Because chronic rumen acidosis usually precedes rumen putrefaction, hyperkeratosis/parakeratosis can be seen on necropsy.

Miscellaneous Causes of Bloat

Sudden ingestion of milk in calves that are eating solid feed can develop bloat. Because the abomasum contains some ingesta from solid feed, sudden ingestion of milk can overdistend the abomasum. This reflexly inhibits rumen motility and causes gas distension of the rumen.³⁰ Other abomasal diseases, such as abomasal ulcers, can cause the same reflex inhibition of rumen motility and subsequent bloat.²⁴

Pneumonia also can lead to recurrent bloat in calves.²³ Although interference with vagal nerve function is implicated in these cases, physical compression or obstruction of the esophagus from enlarged mediastinal lymph nodes, which prevents eructation, is probably the cause.

Left Displacement of the Abomasum

Left displacement of the abomasum (LDA) in calves can cause left-sided abdominal distension. The pathogenesis is not known, but dietary factors are suspected.²² Unlike right displacements and volvulus of the abomasum in calves (discussed later), which are acute accumulations of gas, LDAs usually develop more slowly.²² Approximately one half of the LDAs in one study were accompanied by abomasal ulcers, which may play a predisposing role in this condition.²² In calves, LDA is commonly accompanied by secondary gas distension of the rumen, unlike in adults, in which this rarely occurs.²² This can make differentiating rumen distension alone from rumen distension secondary to LDA difficult. Because a ping may be detected on auscultation and percussion with both conditions, fluid centesis of the organ in question may be necessary. Abomasal contents smell acidic, have an acidic pH, and have a chloride content of > 90 mEq/L as opposed to rumen contents, which normally have a more neutral pH and a chloride content of < 25 mEq/L.²⁵ Calves with chronic rumen acidosis or rumen putrefaction, however, also may have acidic rumen contents (see later discussion), and rumen chloride can be high in milk-fed calves, which can confuse the diagnosis.^{22, 31} Distinguishing the rumen from the abomasum with ultrasonography is also difficult if either organ is gas distended. Passage of a stomach tube to relieve gas distension can be suggestive of rumen distension. Rolling the calf from its right side over its back to its left side is diagnostic of an LDA if the ping disappears. In some cases, an exploratory celiotomy may be indicated for a definitive diagnosis.

RIGHT-SIDED ABDOMINAL DISTENSION

Right-sided abdominal distension in calves occurs primarily with diseases and conditions of the abomasum. Unlike the conditions leading to recurrent bloat, which are usually chronic, these conditions usually

present acutely and can be immediately life threatening. Peritonitis caused by a ruptured abomasal ulcer can be localized to the right abdomen and also cause right-side distension but are discussed under the causes of bilateral abdominal distension.

Acute Abomasal Tympany With Right Displacement and Volvulus

There are several apparent predisposing factors involved in the occurrence of abomasal tympany. The transitional feeding period of calves, when solid feed intake is increasing, but milk is still consumed, is when most cases occur.²² Overdistension of the abomasum from rapid consumption of large amounts of milk or milk replacer, an increase in gas-producing bacteria when nonmilk protein replacers are fed, and inflammation from abomasal ulcers may be some of the underlying causes.²² Once abomasal tympany develops, right displacement and possibly volvulus occurs.

Distension of the right dorsal abdominal quadrant occurs first (Fig. 4) and can progress to distension of the entire abdomen.^{22, 26, 47} Auscultation, percussion, and succussion of the area reveals a ping and splashing tinkling fluid sounds.^{22, 26, 29, 47} Colic and signs of circulatory shock are present. As would be expected, the more severe these signs, the more likely the condition has progressed to abomasal torsion. Fecal amount and consistency varies but may be dry or contain mucus or blood.^{22, 26, 29}

The other differential for right abdominal distension with a concurrent ping would be cecal dilation/torsion. In some cases, however, the small intestine can produce a ping if severely gas distended, and conditions of the small intestine, such as mesenteric torsion, volvulus, intussusception, and strangulation/incarceration should be considered.^{22, 47} Peritonitis secondary to a ruptured abomasal ulcer can also cause a ping if free gas accumulates in the peritoneal cavity.^{22, 47} Although radiography, ultrasonography, laparoscopy, and abdominocentesis may help, all of these conditions, with the exception of a ruptured abomasal ulcer, require immediate surgical correction. Therefore, an exploratory laparotomy for diagnosis and treatment is usually the best approach.²³ In a study of 51 cases of abdominal diseases in calves, exploratory surgery of medical cases did not adversely affect prognosis.⁵⁴

BILATERAL ABDOMINAL DISTENSION

Any disease that causes generalized peritonitis, ascites, or distension of the small intestine can cause bilateral abdominal distension. Most of these diseases involve the gastrointestinal tract, but diseases of other organ systems, uroperitoneum from a ruptured urachus or bladder for example, need to be considered in a differential diagnosis. Figure 5

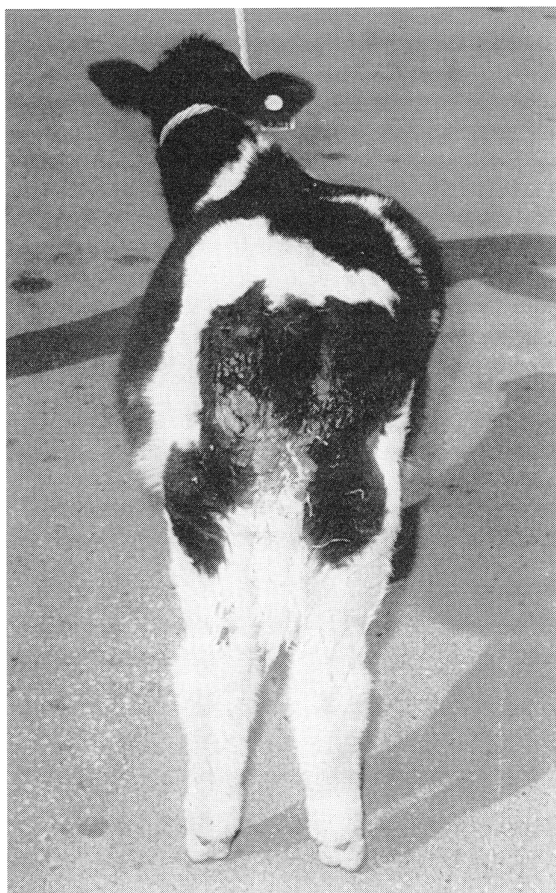

Figure 4. A calf with right-sided abdominal distension from a right volvulus of the abomasum.

demonstrates one way of differentiating the causes of bilateral abdominal distension.

Abomasal Ulcers

Most abomasal ulcers in calves are clinically inapparent.²³ When ulcers do cause clinically recognizable disease in calves, however, it can be severe. Three clinically recognizable forms occur: bleeding ulcers, deep ulcers with localized peritonitis, and perforating ulcers with generalized peritonitis. The last form is the most severe and also the most common.²³

There is no apparent breed or sex predilection, and calves of all

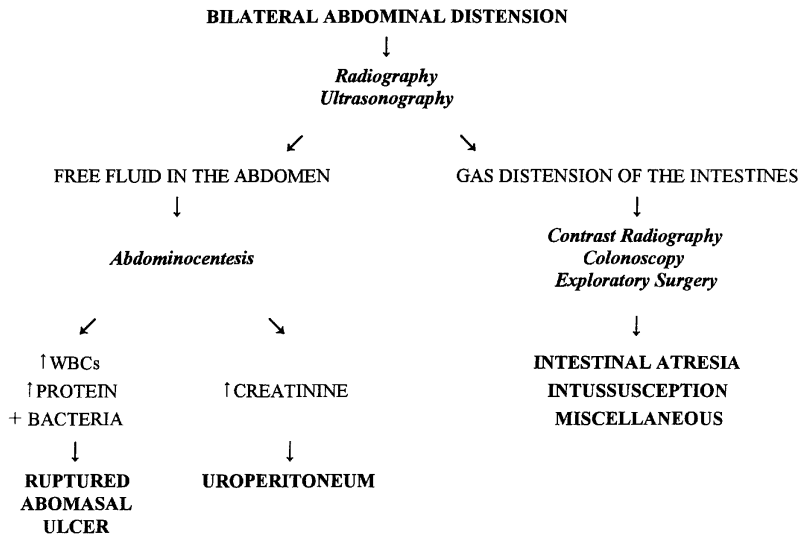


Figure 5. Differentiating the causes of bilateral abdominal distension in calves. WBCs = white blood cells.

ages can develop abomasal ulcers.²³ There is an increased incidence in the transitional feeding period as calves begin to take in increasing amounts of roughage and in fast growing calves.^{9, 23, 62, 76} Other factors implicated as predisposing causes are copper and vitamin E deficiencies, stress, and poor immune function.^{50, 62} Many infectious organisms have been recovered from abomasal ulcers in calves and may be involved in the pathophysiology of this disease, including *Clostridium septicum*, *Clostridium chauvoei*, *Clostridium perfringens* type A, *Salmonella*, and other bacteria and fungi.^{60, 61, 62, 66} Other investigators have failed to find these organisms in ulcers of calves.⁴¹ *Helicobacter pylori* has been implicated but has yet to be proven as a cause of abomasal ulcers in calves.⁴¹ It is difficult to determine the significance of these infectious organisms because, in some cases, it is not known if they are primary or secondary invaders of the gastric mucosa or opportunistic invaders after death.

Bleeding ulcers are uncommon in calves, but when they do occur melena and signs of anemia are the most common clinical signs. Both deep ulcers in which only the serosa remains intact and small perforating ulcers that occur very close to the abdominal wall can cause localized peritonitis with adhesion formation. In these cases, the animals may show signs of abdominal pain and mild inflammation and infection. These adhesions may be noted during exploratory surgery, where concurrent abomasal displacement is commonly diagnosed. Occasionally, these ulcers that are firmly attached to the abdominal wall erode into the abdominal musculature, causing cellulitis, fistulas, or both.²³

More severe perforating ulcers can cause generalized peritonitis. The course and severity of disease depends on where the perforation

occurs. Most perforating ulcers occur cranial to the pylorus and on the greater curvature of the abomasum.^{9, 23} Ulcers that perforate into the omental bursa can be walled off to form an abscess or can progress to severe omental bursitis. Most commonly, ulcers perforate into the abdominal cavity, causing generalized peritonitis.^{9, 23}

As would be expected with a disease with such a broad spectrum of outcomes, the clinical signs can vary significantly. Varying degrees of anorexia, depression, pyrexia, and signs of abdominal pain can be present.^{9, 23, 62} Bruxism is seen in a minority of cases.⁵⁴ The course of the disease may be acute or chronic, but peracute death, which is common in adult cattle, is uncommon in calves.²³ The exception to this may be in beef calves in which acute death without previous signs of illness has been reported.⁴⁰ Abdominal distension is common with severe perforating ulcers and occurs on the left, right, or bilaterally.^{23, 54, 62} Omental bursitis usually causes left-sided distension but can cause right-sided distension. Right-sided, or more commonly bilateral distension, occurs with generalized peritonitis. Pings and splashing sounds in the abdomen can occur and can be difficult to distinguish from the same sounds caused by other surgical diseases of the gastrointestinal tract. The abdomen is usually tense, and the animal resents abdominal palpation.

As alluded to, differentiating perforating abomasal ulcers from other severe abdominal diseases can be difficult. Because peritoneal fluid contaminated with abomasal fluid can be difficult to distinguish from normal fluid in the abomasum, abdominocentesis is helpful in only a minority of cases.²³ Ultrasonography may be helpful in distinguishing free fluid in the abdomen from fluid distension of an abdominal organ. Because emptying the abomasum of food and passing an endoscope is nearly impossible in ruminant animals, endoscopy is not helpful. If a diagnosis cannot be made by physical examination and abdominocentesis, laparoscopy or exploratory surgery may be indicated.

Intestinal Atresia

Intestinal atresia is a congenital abnormality that can occur in any segment of the intestinal tract, but atresia coli, followed by atresia ani, are the most common presentations. The causes of intestinal atresia, especially the inheritance of this defect, are controversial. If atresia proves to be a heritable condition, it appears to be a problem only in Holsteins.¹⁷ Rectal palpation of the amniotic vesicle before day 42 of gestation appears to increase the incidence of this disease.¹⁷

Clinical signs of intestinal atresia are gradual abdominal distension, with no fecal output, and subsequent anorexia and depression and possibly signs of colic. Most animals present in the first week of life.²⁷ Atresia ani can be recognized on physical examination. A lack of fecal output is important to distinguish this disease from other causes of the aforementioned signs. Occasionally calves with atresia coli will pass

some mucus. The Farber test was developed for use in human infants, and it has been used successfully to diagnose atresia in calves.⁴² During gestation, fetal skin cells are shed and swallowed and later passed as meconium. The meconium or mucous can be washed and centrifuged and the sediment stained with methylene blue. If squamous epithelial cells are detected, the intestinal tract is considered patent.

Radiographs are indicated for calves with these clinical signs. Multiple gas and fluid distended loops are suggestive of intestinal atresia (Fig. 6). A barium enema may define the atretic area if it involves the descending colon. Colonoscopy also may be diagnostic if the atretic segment is not beyond the length of the endoscope.^{27, 42} A definitive diagnosis may require exploratory surgery.⁴²

Intussusception

The major differential for intestinal atresia is an intestinal intussusception. In calves, intussusceptions of both the small and large intestines can occur, whereas in adult cattle, usually only the small intestine is involved.³² The presentation generally is more acute in calves than adults, and sudden death can occur. The clinical presentations of intesti-

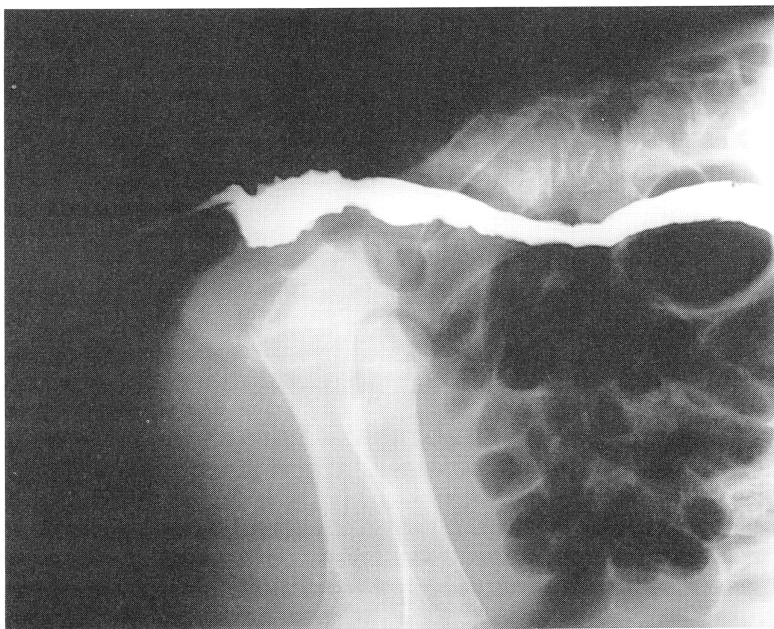


Figure 6. Lateral abdominal radiograph showing multiple gas distended loops of intestines in a calf with atresia coli. Barium was injected into the large colon through a catheter, but the atretic site is not identified.

nal atresia and intussusceptions are the same, except that intussusceptions can occur at any age, with a history of normal fecal production before the intussusception is usually present. Abdominal radiographs also look similar. Occasionally intussusceptions can be palpated through the abdominal wall or detected by ultrasonography, in which case a diagnosis is made.⁵ If, however, the intussusception cannot be detected, this condition cannot be ruled out. Exploratory surgery is indicated for a definitive diagnosis.

Miscellaneous Causes

There are many other diseases of the large and small intestines that must be considered in a differential diagnosis of bilateral abdominal distension. These include cecocolic dilation/volvulus/torsion, functional ileus, intraluminal foreign body obstruction, intestinal incarceration/strangulation, and meconium impaction.^{5, 18, 42} These conditions are uncommon in calves and can be differentiated best by exploratory surgery.

CALF DIARRHEA

Diarrhea in the neonatal calf is a complex, multifactorial disease involving the calf, the environment, nutrition, and infectious agents. Decades of research have been devoted to the study of the pathophysiology of infectious diarrhea of neonatal calves. Despite improvements in management practices, and prevention and treatment strategies, this disease is still the most common and costly disease affecting neonatal calves in the United States.^{72, 74}

Although some general preventive measures, such as improved sanitation, work no matter what the cause of diarrhea, specific control measures, such as vaccination, require definition of a specific cause. This section discusses the pathogens that cause diarrhea, with an emphasis on defining the specific pathogen(s) involved. Table 1 lists the causes of diarrhea in calves and samples required for diagnosis. The color and consistency of the feces and gross lesions can look similar no matter the cause,³³ thus laboratory identification of infectious agents and histology are key to establishing a diagnosis. Because autolysis and secondary bacterial invasion of the gut begin minutes after death, necropsy samples taken immediately from euthanized calves are best.⁵³ It is important to remember that mixed infections with two or more pathogens are more common than infections with single pathogens and that the pathogens that are a problem on a farm change from year to year.³³ In some cases, an underlying nutritional problem is combined with an infectious agent. Therefore, the practitioner must be careful to take a variety of samples to ensure all pathogens and predisposing factors involved are recognized and to continue to reevaluate the causes of diarrhea on a particular farm. Examination of several cases, especially focusing on acute cases,

Table 1. DIAGNOSTIC SAMPLES AND TESTING METHODS REQUIRED FOR DIFFERENTIATION OF THE MOST COMMON INFECTIOUS CAUSES OF CALF DIARRHEA

Causative Agent	Sample Required	Test Method
<i>Escherichia coli</i>	2–3 g feces	Culture and serotyping for K99
	Formalin fixed small intestine	Histopathology
Rotavirus	2–3 g feces or colonic contents	EM, ELISA, CF, PCR
	Formalin fixed tissues	Histopathology
	Frozen tissues	FA, IP
Coronavirus	2–3 g feces or colonic contents	EM, ELISA
	Formalin fixed tissues	Histopathology, IHC
<i>Cryptosporidiosis</i>	2–3 g feces	FA, fecal flotation
	Air-dried fecal smear	Acid-fast stain
	Formalin fixed tissues	Histopathology
<i>Salmonella</i>	2–3 g feces	Culture, PCR
	Formalin fixed tissues	Histopathology
	Frozen tissues	Culture
<i>Clostridium perfringens</i>	Frozen small intestinal contents and tissues	Culture, toxin identification
	Formalin fixed tissue	Histopathology
<i>Giardia</i>	Wet mount of feces	Iodine staining
	Feces	ELISA, FA

Data from references 7, 8, 12, 16, 28, 56, 59, and 70.

EM = electron microscopy; ELISA = enzyme-linked immunosorbent assay; IHC = immunohistochemistry; CF = complement fixation; PCR = polymerase chain reaction; FA = fluorescent antibody; IP = immunoperoxidase.

is important. Although examination of antemortem fecal samples can be diagnostic, laboratory testing of tissue samples may yield better results.⁶⁷

Major Infectious Causes of Diarrhea in Neonatal Calves

There are five major pathogens that cause diarrhea in neonatal calves: enterotoxigenic *Escherichia coli*, rotavirus, coronavirus, *Cryptosporidium*, and *Salmonella* spp. The relative prevalence of these infectious agents varies greatly among studies. This is most likely the result of differences in location, season, diagnostic techniques, and other factors. Some trends, however, can be identified. Rotavirus is the most common cause of diarrhea in neonatal calves. Coronavirus and enterotoxigenic *E. coli* (ETEC), however, have higher mortality rates than rotavirus, therefore their economic impact is greater.^{2, 69, 71}

Enterotoxigenic E. coli

Enterotoxigenic *E. coli* uses two virulence factors to cause disease. The first virulence factor is the ability to attach and colonize the intestinal

villi, which is accomplished by fimbria or pili. The most important fimbria in calves is K99.⁷¹ The K99 fimbrial antigen can be recognized in the laboratory and is important in diagnosing this disease as a cause of diarrhea in calves. Because there are many nonpathogenic *E. coli* that are normal gut inhabitants, simply culturing this organism from the gut is usually insignificant. Serotyping for the K99 fimbrial antigen is also needed to make a diagnosis of ETEC. Once the organism is attached to the villi, the second virulence factor, enterotoxin, is produced. It is the enterotoxin that actually interferes with the normal physiology of the gut, which leads to diarrhea.³

As a result of age-related resistance most likely related to blocking of fimbrial attachment to the gut, ETEC occurs mainly in calves less than 1 week old (Fig. 7).^{65, 77} Because ETEC causes a secretory diarrhea, bicarbonate loss in the diarrhea leads to severe acidosis, and calves quickly become dehydrated and recumbent.^{3, 71} This leads to high mortality rates if calves are not treated promptly. Diagnosis is based on fecal culture and serotyping for the K99 fimbrial antigen.⁷⁷ Occasionally the bacteria do not express the fimbrial antigens in the culture, and thus ETEC cannot be ruled out if the culture is K99 negative.⁶⁷ Histologic evidence of colonization can support a diagnosis.^{3, 77}

Rotavirus and Coronavirus

Rotavirus and coronavirus produce similar lesions. Both infect villus tip cells.³⁸ Rotavirus appears to be a more widespread problem, but coronavirus leads to more severe diarrhea for two reasons. First, coronavirus destroys a greater portion of each villus tip than does rotavirus. Second, whereas rotavirus only infects the proximal half of the small intestine, coronavirus infects the same portions of the small intestine and the large intestine.^{8, 38, 67} The result of either infection is villus atrophy and malabsorptive diarrhea.^{6, 15, 44}

Rotavirus typically affects calves 5 to 14 days of age, and coronavirus usually occurs in calves 5 to 30 days of age.^{38, 44} Both can occur in the first few days of life, and rotavirus has been reported in calves up to 2 to 3 months of age.^{14, 73} The upper age limit of coronavirus is unclear and may not exist considering the association of this organism with

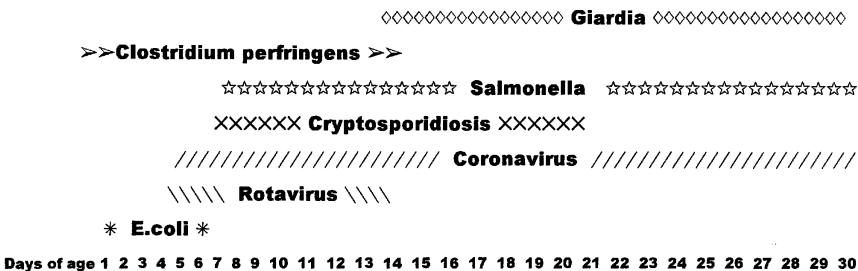


Figure 7. Ages at which diarrhea occurs in calves infected with the agents shown.

winter dysentery in adult cattle.⁶⁸ These two organisms can be differentiated by electron microscopy of fecal or colonic samples or by immunologic techniques on feces or tissue sections.³⁸ Because these organisms are sloughed with the villus tip cells they infect during infection, or the viral antigens are complexed with the calf's antibody, tissue samples from acutely infected animals are best.^{33, 67}

Cryptosporidiosis

Cryptosporidia parvum is a protozoa that causes malabsorptive diarrhea similar to rotavirus and coronavirus. It infects the villus tip cells of the distal small intestine and large intestine. Unlike other protozoal infections, like coccidiosis, *Cryptosporidia* do not require fecal excretion for sporulation.⁵¹ They can sporulate in the gut and become immediately infectious to other villus tip cells without ever leaving the gut.⁵¹ This method of autoinfection leads to very severe disease, which can be sustained for long periods. Relapses are also common, and this organism is common in mixed infections.⁵¹

Cryptosporidia cause diarrhea in calves 1 to 3 weeks old.⁵¹ Acid-fast staining of air dried fecal smears is a quick and easy method of diagnosis. Examination under 40X to 100X reveal round protozoa that have taken up the red color of the carbol fuchsin portions of the stain on a green background. Although they can be diagnosed by fecal flotation, their small size (4–6 μm) makes this method very difficult and subject to false-negative results.^{19, 59} Immunologic techniques and a polymerase chain reaction (PCR) technique have been developed to improve detection limits over flotation and acid-fast staining techniques.^{59, 75} *Cryptosporidia* also can be identified with histology.⁵¹ Cryptosporidiosis is a zoonotic disease, and people can easily become infected from handling infected calves.^{49, 58}

Salmonellosis

Salmonella cause diarrhea in calves 7 days of age and older. There are more than 2000 serotypes of *Salmonella sp* and all can potentially cause diarrhea in calves.⁴⁴ *Salmonella* produce enterotoxins, are invasive, and cause severe inflammatory disease and necrosis of the lining of the small and large intestines.⁴⁴ Diarrhea is more likely to contain blood in salmonellosis.⁵⁷ This is also a zoonotic disease.⁵⁷ Diagnosis is based on culture of feces or tissues and histologic examination of the bowel.³⁶ More sensitive PCR techniques for identifying *Salmonella spp.* in feces are being developed.¹⁶

Other Infectious Causes of Diarrhea in Neonatal Calves

C. perfringens

C. perfringens types A, B, C, and D can all cause diarrhea in calves, but type C is most common.²⁸ Diarrhea occurs in calves less than 2

weeks of age, but sudden death before clinical signs of enteritis are seen is more likely.^{37, 73} The production of enterotoxins causes necrosis of the small intestine and hemorrhagic diarrhea.²⁸ Clostridial organisms can be cultured from intestinal tissue samples, but the significance of a positive culture can be difficult to interpret, as these organisms can be present in the gut normally and then proliferate following death. Histologic examination of sections of the gut can be helpful. Identification of the toxins in intestinal contents is required for a definitive diagnosis.²⁸

Giardia

Giardia has been isolated from 2- to 4-week-old calves with diarrhea. It infects the duodenum and proximal jejunum but causes little damage, and the pathophysiologic mechanisms of induction of diarrhea by *Giardia* are not clear.⁵⁹ As with cryptosporidiosis, giardiasis can cause acute or chronic diarrhea.^{45, 59} Iodine stained wet mounts of feces or tissue is the classic method of diagnosing giardiasis, but more sensitive immunologic techniques are now available.^{45, 59} As this is another zoonotic disease, calves that are shedding this organism should be handled carefully.¹¹

Miscellaneous Infectious Causes of Calf Diarrhea

Other types of *E. coli* other than the enterotoxigenic type, such as enterohemorrhagic (EHEC), enteropathogenic (EPEC), and enteroinvasive (EIEC) types have been isolated from calves with diarrhea.³⁹ These calves range in age from 2 days to 4 months, but most are less than 3 weeks of age.^{35, 39, 77} Unlike ETEC that usually causes no or minimal gross pathology, the EHEC, EPEC, and EIEC produce verotoxins that destroy the villi of the small and large intestines, leading to hemorrhagic diarrhea. These *E. coli* are not K99 positive. Culture and serotyping of these organisms from feces and tissue samples with typical histopathologic lesions is diagnostic. Although ETEC is not zoonotic, EHEC, EPEC, and EIEC are potentially zoonotic.

There are other pathogens that are implicated as causes of diarrhea in calves. These include *Campylobacter*, adenovirus, parvovirus, calicivirus, bredavirus, enterovirus, and astrovirus.^{38, 53, 73} As with the infectious organisms associated with abomasal ulcers, it is difficult to determine the significance of some of these organisms.

Nutritional Diarrhea

Infectious agents are not the only cause of diarrhea in calves. Nutritional problems can cause diarrhea, but these problems are overshadowed in the literature because the resulting diarrhea is usually mild and subsides without treatment. The most common cause of nutritional diarrhea in dairy calves is feeding large quantities of milk with pro-

longed time intervals between feedings or feeding poor quality milk replacers.^{53, 64} In beef calves, sudden increases in the dam's milk production from nutritional changes is thought to cause nutritional diarrhea.¹

Calves with infectious diarrhea that develop maldigestion/malabsorption can have secondary nutritional diarrhea from loss of the ability to digest carbohydrates such as lactose and xylose.^{52, 53, 64} Diarrhea due to primary lactase deficiency also has been reported.⁵⁵ Calves on poor quality milk replacers can also develop an overgrowth of normal enteric *E. coli* that causes diarrhea.⁶⁴

Causes of Diarrhea in Older Calves

Coccidiosis and bovine viral diarrhea virus (BVDV) should be considered in older calves with diarrhea. Coccidiosis causes bloody diarrhea usually in calves older than 30 days of age. In severe cases, the disease becomes protracted due to necrosis of the mucosal lining. Even if these animals are treated appropriately, the diarrhea continues until the intestinal mucosa heals, which can take several days to weeks. It can be easily diagnosed from a direct smear or flotation of feces in the acute stages. In the chronic stages, most of the organisms have been shed, and very low numbers are seen on fecal examination. Because normal cattle can also shed low numbers, interpretation of fecal examinations in the chronic stages of coccidiosis can be difficult. In these cases, other diseases such as nematode infestations and BVDV should be considered (see "Differentiation of Gastrointestinal Diseases in Adult Cattle" elsewhere in this issue for discussion of BVDV).

SUMMARY

With a complete history, careful physical examination, and targeted diagnostics, the practitioner can differentiate the causes of gastrointestinal diseases in calves. The authors hope that this article helps the practitioner in this regard. Armed with a diagnosis, he or she can then proceed with proper treatment and prevention, which is the ultimate goal.

ACKNOWLEDGMENTS

The authors thank Lisa Makarchuk, Eric Johnson, and Larry Moore for their help with the figures. Thanks also goes to Gatz Riddell, DVM, MS, for reviewing the article and to Rachel Eddleman for her assistance in gathering references.

References

1. Andrews AH: Health and disease. In Calf Management and Disease Notes. Hertfordshire, Nynwood Arts, 1983

2. Acres SD, Saunders JR, Radostits OM: Acute undifferentiated neonatal diarrhea of beef calves: The prevalence of enterotoxigenic *E. coli*, reo-like (rota) virus and other enteropathogens in cow-calf herds. *Can Vet J* 18:113-121, 1977
3. Acres SD: Enterotoxigenic *Escherichia coli* infections in newborn calves: A review. *J Dairy Sci* 68:229-256, 1985
4. Anderson DE, Cornwell D, Anderson LS, et al: Comparative analyses of peritoneal fluid from calves and adult cattle. *Am J Vet Res* 56:973-976, 1995
5. Anderson DE, St.Jean G: Intussusception. In Howard JL, Smith RA (eds): *Current Veterinary Therapy Food Animal Practice*, ed 4. Philadelphia, WB Saunders, 1999, pp 537-538
6. Babiuk LA, Sabara M, Hudson GR: Rotavirus and coronavirus infections in animals. *Progress in Veterinary Microbiology and Immunology* 1:80-120, 1985
7. Benefield DA, Stotz IJ, Nelson EA, et al: Comparison of a commercial enzyme-linked immunosorbent assay with electron microscopy, fluorescent antibody, and virus isolation for the detection of bovine and porcine rotavirus. *Am J Vet Res* 45:1998-2002, 1984
8. Bezek D: Rotavirus enteritis in food animals. *Compendium on Continuing Education for the Practicing Veterinarian* 16:391-405, 1994
9. Breukink HJ, Kuiper R: Clinical consequences of abomasal ulceration in cattle. In *Pathologie de la caillette place des anti-inflammatoires chez les bovins*, Societe Francaise de Buiatrie, Toulouse, France, 1993, pp 109-119
10. Breukink HJ, Wensing TH, Weeren-Keverling-Buisman A, et al: Consequences of failure of the reticular groove reflex in veal calves fed milk replacer. *Vet Q* 10:126-135, 1988
11. Buret A, DenHollander N, Wallis PM, et al: Zoonotic potential of giardiasis in domestic ruminants. *J Infect Dis* 162:231-237, 1990
12. Carter GR, Cole JR: *Diagnostic Procedures in Veterinary Bacteriology and Mycology*, ed 5. San Diego, Academic Press, 1990
13. Chapman HW, Butler DG, Newell M: The route of liquids administered to calves by esophageal feeder. *Can J Vet Res* 50:84-87, 1986
14. Clark KJ, Tamborello TJ, Xu Z, et al: An unusual group-A rotavirus associated with an epidemic of diarrhea among three-month-old calves. *J Am Vet Med Assoc* 208:552-554, 1996
15. Clark MA: Bovine coronavirus. *British Veterinary Journal* 149:51-70, 1993
16. Cohen ND, Martin LJ, Simpson B, et al: Comparison of polymerase chain reaction and microbiological culture for detection of salmonellae in equine feces and environmental samples. *Am J Vet Res* 57:780-786, 1996
17. Constable PD, Huhn JC, Morin DE, et al: Atresia coli in calves: Etiopathogenesis and surgical management. *Bovine Practice* 33:70-73, 1999
18. Constable PD, Rings M, Hull BL, et al: Atresia coli in calves: 26 cases (1977-1987). *J Am Vet Med Assoc* 195:118-123, 1989
19. Corwin RM: Cryptosporidiosis: A coccidiosis of calves. *Compendium on Continuing Education for the Practicing Veterinarian* 14:1005-1007, 1992
20. Dirksen G: Forestomachs. In Rosenberger G (ed): *Clinical Examination of Cattle*. Berlin Hamburg, Paul Parey, 1979, pp 197-220
21. Dirksen G, Baur T: Force-feeding and rumen acidosis in young calves. *Bovine Practice* 25:29-32, 1990
22. Dirksen GU: Tympany, displacement and torsion of the abomasum in calves: Pathogenesis, diagnosis and treatment. *Bovine Practice* 28:120-126, 1994
23. Dirksen GU: Ulceration, dilation and incarceration of the abomasum in calves: Clinical investigations and experiences. *Bovine Practice* 28:127-135, 1994
24. Dirksen GU, Garry FB: Diseases of the forestomachs in calves-part I. *Compendium on Continuing Education for the Practicing Veterinarian* 9:F140-F145, 1987
25. Dirksen GU, Garry FB: Diseases of the forestomachs in calves-part II. *Compendium on Continuing Education for the Practicing Veterinarian* 9:F173-F179, 1987
26. Doll K: Tympany and torsion of the abomasum in calves. *Bovine Practice* 26:96-99, 1991
27. Dreyfuss DJ, Tulleners EP: Intestinal atresia in calves: 22 cases (1978-1988). *J Am Vet Med Assoc* 195:508-513, 1989
28. Fleming S: Enterotoxemia in neonatal calves. *Vet Clin North Am: Food Anim Pract* 1:509-514, 1985

29. Frazee LS: Torsion of the abomasum in a one month old calf. *Can Vet J* 25:293-295, 1984
30. Garry FB: Indigestion in ruminants. In Smith BP (ed): *Large Animal Internal Medicine*, ed 2. St. Louis, CV Mosby, 1996, pp 824-828
31. Garry FB: Rumen putrefaction. In Howard JL, Smith RA (eds): *Current Veterinary Therapy Food Animal Practice*, ed 4. Philadelphia, WB Saunders, 1999, pp 510-512
32. Guard C: Obstructive intestinal diseases. In Smith BP (ed): *Large Animal Internal Medicine*, ed 2. St. Louis, CV Mosby, 1996, pp 880-881
33. Heath SE: Neonatal diarrhea in calves: Diagnosis and intervention in problem herds. *Compendium on Continuing Education for the Practicing Veterinarian* 14:995-1002, 1992
34. Hofflund S: Diseases due to digestive disorders, hygiene of nursing, weaning, and artificial feeding: V. Digestive disorders of hygiene in the feeding of calves. In Eriksson K (ed): *Control of Losses in Young Farm Animals, OEEC-REPORT, Project No. 345*, 1957, pp 113-140
35. Hollund RE: Some infectious causes of diarrhea in young farm animals. *Clin Microbiol Rev* 3:345-375, 1990
36. House JD, Smith BP: Current strategies for managing salmonella infections in cattle. *Vet Med* 93:756-764, 1998
37. Hunt E: Diarrheal diseases of neonatal calves. In Howard JL, Smith RA (eds): *Current Veterinary Therapy Food Animal Practice*, ed 4. Philadelphia, WB Saunders Co., 1999, pp 56-62
38. Janke BH: Protecting calves from viral diarrhea. *Veterinary Medicine* 84:803-810, 1989
39. Janke BH: Attaching and effacing *Escherichia coli* infections in calves, pigs, lambs, and dogs. *J Vet Diagn Invest* 1:6-11, 1989
40. Jelinski MD, Janzen ED, Hoar B, et al: A field investigation of fatal abomasal ulcers in western Canadian beef calves. *Agri-Pract* 16:16-18, 1995
41. Jelinski MD, Ribble CS, Chirino-Trejo M, et al: The relationship between the presence of *Helicobacter pylori*, *Clostridium perfringens* type A, *Campylobacter* sp., or fungi and fatal abomasal ulcers in unweaned beef calves. *Can Vet J* 36:379-382, 1995
42. Johnson R, Ames NK, Coy C: Congenital intestinal atresia of calves. *J Am Vet Med Assoc* 182:1387-1389, 1983
43. Jubb KVF, Kennedy PC, Palmer N: In *Pathology of Domestic Animals*, ed 4, vol 2. Orlando, Academic Press, 1993
44. Kersting K: Enteric pathogens of young calves. *Bovine Practice* 32:39-42, 1998
45. Kirkpatrick CE: Giardiasis in large animals. *Compendium on Continuing Education for the Practicing Veterinarian* 11:80-84, 1989
46. Kumar A, Tanwar RK, Gahlot TK, et al: Trichophytobezoars in a neonatal calf. *Mod Vet Pract* 63:382, 1982
47. Kumper H: A new treatment for abomasal bloat in calves. *Bovine Practice* 29:80-82, 1995
48. Leek BF: Digestion in the ruminant stomach. In Swenson MJ, Reece WO (eds): *Duke's Physiology of Domestic Animals*, ed 11. Ithaca, Cornell University Press, 1993
49. Levine JF, Levy MG, Walder RL, et al: Cryptosporidiosis in veterinary students. *J Am Vet Med Assoc* 193:1413-1414, 1988
50. Lilley CW, Hamr DW, Johnson JL: Linking copper and bacteria with abomasal ulcers in beef calves. *Vet Med* 80:85-88, 1985
51. Moore JA, Blagburn BL, Lindsay DS: Cryptosporidiosis in animals including humans. *Compendium on Continuing Education for the Practicing Veterinarian* 10:275-285, 1988
52. Nappert G, Hamilton D, Petrie L, et al: Determination of lactose and xylose malabsorption in preruminant diarrheic calves. *Can J Vet Res* 57:152-158, 1993
53. Naylor JM: Neonatal ruminant diarrhea. In Smith BP (ed): *Large Animal Internal Medicine*, ed 2. St. Louis, CV Mosby, 1996, pp 396-417
54. Naylor JM, Bailey JV: A retrospective study of 51 cases of abdominal problems in the calf: Etiology, diagnosis and prognosis. *Can Vet J* 28:657-662, 1987
55. Olchoway TWJ, Linnabery RD, Andrews FM, et al: Lactose intolerance in a calf. *J Vet Intern Med* 7:12-15, 1993
56. Quinn PJ, Carter ME, Markey BK, et al: *Clinical Veterinary Microbiology*. London, Wolfe Publishing, 1994

57. Peltzer KD: Salmonellosis. *J Am Vet Med Assoc* 195:456-463, 1989
58. Reif JS, Wimmer L, Smith JA, et al: Human cryptosporidiosis associated with an epizootic in calves. *Am J Pub Health* 79:1528-1530, 1989
59. Rings DM, Rings MB: Managing *Cryptosporidium* and *Giardia* infections in domestic ruminants. *Veterinary Medicine* 91:1125-1131, 1996
60. Roeder BL, Chengappa MM, Nagaraja TG, et al: Experimental induction of abdominal tympany, abomasitis, and abomasal ulceration by intraruminal inoculation of *Clostridium perfringens* type A in neonatal calves. *Am J Vet Res* 49:201-207, 1998
61. Roeder BL, Chengappa MM, Nagaraja TG, et al: Isolation of *Clostridium perfringens* from neonatal calves with ruminal and abomasal tympany, abomasitis, and abomasal ulceration. *J Am Vet Med Assoc* 190:1550-1555, 1987
62. Roeder BL: Abomasal ulcer disease in calves. In *Proceedings of the 8th Annual American College of Veterinary Internal Medicine Forum*, Washington, DC, 1990, pp 739-742
63. Roy JHB: The digestive system of the calf. In *The Calf*, ed 4. Boston, Butterworth, 1980
64. Roy JHB: Diseases of young calves. In *The Calf*, ed 4. Boston, Butterworth, 1980
65. Runnels PL, Moon HW, Schneider RA: Development of resistance with host age to adhesion of K99⁺ *Escherichia coli* to isolated intestinal epithelial cells. *Infect Immun* 28:298, 1980
66. Saunders G: Diagnosing braxy in calves and lambs. *Veterinary Medicine* 81:1050-1052, 1986
67. Schultheiss P: Diarrheal disease in calves. *Large Animal Vet* 47:24-28, 1992
68. Smith DR, Fedorka-Clay PJ, Mohan R, et al: Evaluation of cow-level risk factors for the development of winter dysentery in dairy cattle. *Am J Vet Res* 59:986-1002, 1998
69. Snodgrass DR, Terzolo HR, Sherwood D, et al: Aetiology of diarrhoea in young calves. *Vet Rec* 119:31-34, 1986
70. Timoney JF, Gillespie JH, Scott FW, et al: In *Hagan and Bruner's Microbiology and Infectious Diseases of Domestic Animals*, ed 8. Ithaca, Comstock Publishing, 1988
71. Tzipori S: The relative importance of enteric pathogens affecting neonates of domestic animals. *Advances in Veterinary Science and Comparative Medicine* 29:103-158, 1985
72. Toombs RE, Grotelueschen DM, Glock RD, et al: Postnatal calf losses in beef herds: Causes and epidemiological characteristics. *Large Anim Practice* 19:16-24, 1998
73. Torres A: The pathogenesis and clinical management of neonatal diarrhea. In *Proceedings of a Symposium on Bovine Neonatal Diarrhea*, Las Vegas, 1988, pp 5-14
74. Virtala AK, Mechor GD, Grohn YT, et al: Morbidity from nonrespiratory diseases and mortality in dairy heifers during the first three months of life. *J Am Vet Med Assoc* 208:2043-2046, 1996
75. Webster KA, Smith HV, Dawson L, et al: Detection of *Cryptosporidium parvum* oocysts in faeces: Comparison of conventional coproscopical methods and the polymerase chain reaction. *Vet Parasitol* 61:5-13, 1996
76. Wensing T, Breukink HJ, VanDijk S: The effect of feeding pellets of different types of roughage on the incidence of lesions in the abomasum of veal calves. *Vet Res Commun* 10:195-202, 1986
77. Zeman DH, Thomson JU, Francis DH: Diagnosis, treatment, and management of enteric colibacillosis. *Veterinary Medicine* 84:794-802, 1989

Address reprint requests to

Christine B. Navarre, DVM, MS
 Department of Large Animal Surgery and Medicine
 College of Veterinary Medicine
 Auburn University
 Auburn, AL 36849