

1-1-2000

Differentiation of gastrointestinal diseases in adult cattle.

E. B. Belknap

Auburn University College of Veterinary Medicine

C. B. Navarre

Auburn University College of Veterinary Medicine

Follow this and additional works at: https://digitalcommons.lsu.edu/animalsciences_pubs

Recommended Citation

Belknap, E., & Navarre, C. (2000). Differentiation of gastrointestinal diseases in adult cattle.. *The Veterinary clinics of North America. Food animal practice*, 16 (1), 59-86. [https://doi.org/10.1016/S0749-0720\(15\)30137-7](https://doi.org/10.1016/S0749-0720(15)30137-7)

This Article is brought to you for free and open access by the School of Animal Sciences at LSU Digital Commons. It has been accepted for inclusion in Faculty Publications by an authorized administrator of LSU Digital Commons. For more information, please contact ir@lsu.edu.

DIFFERENTIATION OF GASTROINTESTINAL DISEASES IN ADULT CATTLE

Ellen B. Belknap, DVM, MS, and Christine B. Navarre, DVM, MS

A significant proportion of the cases that veterinarians are confronted with in food animal practice are gastrointestinal disorders. In this article some general diagnostic techniques are reviewed and then specific gastrointestinal disorders of adult cattle are grouped by signs of abdominal distention, anterior abdominal pain, and diarrhea. Although there is some overlap of conditions, the authors believe this is a logical way to approach gastrointestinal disturbances of adult cattle.

GENERAL ASSESSMENT

Forestomach Motility

Assessment of forestomach motility is an important part of the diagnostic evaluation of any bovine case. Determination of whether one is presented with a primary indigestion as a result of dysfunction of the rumen, reticulum, or omasum (forestomachs) or whether a secondary indigestion is present as a sequelae to other gastrointestinal or systemic disease is imperative for adequate treatment and determination of prognosis. Forestomach motility disorders result in abdominal distention, rumen stasis, and/or failure of reticulorumen transit of ingesta.

Normal reticulorumen motility is characterized by a biphasic contraction of the reticulum forcing ingesta dorsal and caudal into the

From the Department of Large Animal Surgery and Medicine, Auburn University College of Veterinary Medicine, Auburn, Alabama

VETERINARY CLINICS OF NORTH AMERICA:
FOOD ANIMAL PRACTICE

rumen followed by contraction of the dorsal rumen sac forcing ingesta into the relaxed ventral sac of the rumen. Subsequent contraction of the ventral and caudodorsal sacs propels ingesta forward into the reticulum and cranial sac of the rumen.^{18, 48} Normal crescendo-decrescendo contractions are auscultated two to three times every 2 minutes.⁴⁸ Strength and frequency should be evaluated. It is important also to view the contraction cycle in the left paralumbar fossa and to palpate the rumen. The normal rumen should feel doughy dorsally with fluid located ventrally. Ballottement of the rumen helps to assess the consistency of the contents. When abnormal motility or consistency of rumen contents are detected, evaluation of rumen contents should be performed.

Rumen Fluid Analysis

Rumen fluid analysis is a relatively easy procedure that enables one to evaluate the physiologic state of the rumen (Table 1) and to differentiate between many conditions of the bovine gastrointestinal tract. Collection of rumen fluid from the ventral sac may be done with either a specialized rumen fluid collection tube (Dirksen, Jorgensen Laboratory, Loveland, CO) or weighted stomach tube⁶⁷ or by rumenocentesis. Rumenocentesis is more often used for herd diagnostics and small (≤ 10.0 mL) samples.⁵⁷

Table 1. NORMAL VALUES FOR RUMEN FLUID ANALYSIS

Test	Result	Interpretation
Color	Green	Normal-pasture
	Yellow brown	Normal-silage
	Green brown	Normal-concentrate
	Milky to brown	Grain engorgement
Odor	Aromatic	Normal
	Sour or acid	Grain engorgement
pH	5.5-7.5	Normal
	<5.5	Grain engorgement
	>7.0	Inactive rumen
	>8.0	Urea toxicity
Protozoa	Mixed sizes & species	Normal
	No large entodiniomorphs	Mild indigestion
	No entodiniomorphs	Severe indigestion
	No protozoa	Rumen acidosis
Methylene blue	3-6 minutes	Normal
	<3 minutes	Grain engorgement
	>6 minutes	Inactive rumen
Sediment activity time	4-8 minutes	Normal
	Absent or rapid	Inappetance
	Prolonged	Frothy bloat
Gram stain	Gram - > gram +	Normal
	Gram + > gram -	Grain engorgement
Rumen chloride	<25-30 mEq/L	Normal
	>30 mEq/L	Abomasal reflux

Odor and color are subjective assessments that should be made as soon as possible after collection of the fluid. The normal color may vary from gray to green to brownish-yellow depending on the diet.⁶⁹ The odor is characteristically related to the condition of the rumen contents and may be sour if associated with carbohydrate engorgement or putrid if the rumen flora and fauna are inactive or dead.

The pH of the fluid should be read quickly, as exposure of the rumen fluid to air results in the loss of CO₂ and an increase in pH.²³ Normal pH varies from 5.5 to 7.0, with lower values predominating as the concentration of grain in the ration increases.¹ If the sample was obtained with a stomach tube, the foremost (50–60 mL) part of the sample should be discarded because of saliva contamination. The risk of peritonitis, although small, is present when obtaining a sample through rumenocentesis, and these samples generally have had lower pH values than similar samples collected by an orogastric tube but are probably inherently more accurate.⁴⁹

Direct microscopic visualization of protozoa and bacteria should be performed. By placing one drop of rumen fluid on a clean microscope slide and viewing at least 10 different fields, protozoal counts can be assessed as either none, few, moderate, or abundant. Protozoal counts are variable and not as important as the number and viability of holotrichs and entodiniomorphs. Holotrichs have cilia all around or on both ends of their bodies, whereas entodiniomorphs have cilia only on their aboral end (Fig. 1). The large entodiniomorphs are the most fragile of

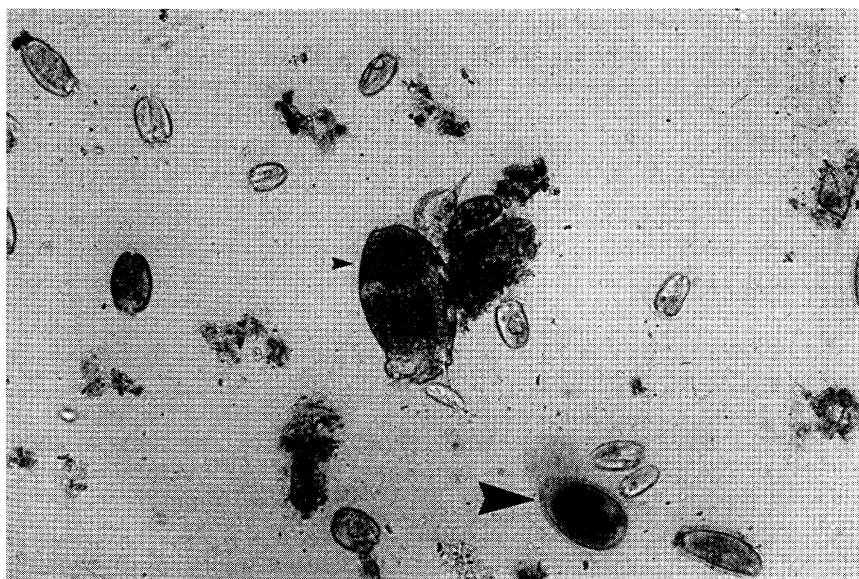


Figure 1. Rumen fluid with protozoa. Holotrichs (*large arrowhead*). Entodiniomorphs (*small arrowhead*).

the protozoal species, whereas the holotrichs are the most hardy. All protozoa die at a pH \leq 5.0. Staining with Lugol's inactivates the protozoa and allows carbohydrate storage to be observed. Lack of dark staining indicates no carbohydrate storage. Smears of rumen fluid may be air-dried or heat-fixed and stained to determine the proportion of gram-negative to gram-positive bacteria. Gram-negative species generally predominate.¹ Rumen fluid with an overgrowth of gram-positive bacteria would be observed with rumen acidosis, whereas excessive reflux of abomasal fluid would still allow for gram-negative bacteria to predominate.

Fluid may be put into 10-mL glass collection tubes for evaluation of sediment activity time (SAT) and methylene blue reduction (MBR). The SAT refers to the time (normally 4 to 8 minutes depending on ration and time after feeding) required for fine particles in the rumen fluid to settle out and the large fibrous particles to float to the surface and foam to appear on the surface as a result of ingesta decomposition. The SAT is generally decreased with inactivity of the rumen microbial population from inappetence, rumen acidosis, and low nutritional value feed.²² The MBR is an indirect method to assess the redox potential of the rumen microbial fermentation. One part of 0.03% methylene blue is mixed with 20 parts rumen fluid. A second tube of rumen fluid acts as a color control. At room temperature, the time to decolorization of the test sample to the control sample color is measured. The time for decoloration is inversely proportional to microbial activity with times greater than 6 minutes considered prolonged, 3 to 6 minutes normal for a predominately hay diet with some grain, and 3 minutes or less normal for mixed hay and grain diets.²³

Rumen fluid chloride levels may be measured from filtered fluid samples, with values greater than 30 mEq/L indicative of abomasal reflux caused by an abomasal or proximal small intestinal obstruction. The addition or contamination with up to 20% saliva, which has chloride concentrations similar to rumen fluid, does not appear to dramatically affect the chloride concentration.²³

Abdominocentesis

Collection and evaluation of peritoneal fluid is helpful in diagnosing and establishing a prognosis in many gastrointestinal disorders. The authors prefer a four-quadrant method of abdominocentesis, because of the bovine species' ability to wall off and localize infections in their abdomen. The caudal quadrants are located in the caudoventral abdominal wall medial to the fold of the flank. The cranial quadrants are at sites approximately 5 cm caudal to the xyphoid and 5 cm on either side of the midline.⁵¹ This technique is most easily accomplished by shaving and aseptically preparing the quadrants. Tail restraint is used for the procedure, as an 18-gauge 1.5-inch needle is used to collect the sample after quick insertion through the abdominal wall (Fig. 2). Others have

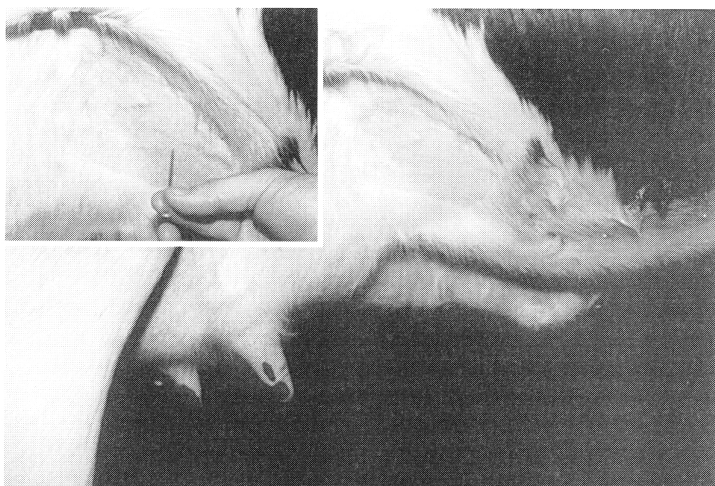


Figure 2. Area to perform abdominocentesis in the right rear quadrant. Insert displays attempted insertion of 18 G needle.

described use of a trocar and cannula.⁸⁹ Volume of fluid collected may range from 0 to 5 mL in normal nonpregnant cattle, with greater values in cattle in late gestation and postparturition. Sufficient fluid is obtained in more than 80% of cases.^{2, 51} Normal values for bovine peritoneal fluid are reported (Table 2).

ABDOMINAL DISTENTION

Distention of the abdomen may be observed from the rear and/or a lateral view of the animal. It is important to view cattle from both sites and determine the general body contour, the degree of symmetry from side to side, and when viewed laterally, to ascertain if the distention is primarily in the paralumbar fossa or extends cranially under the ribs

Table 2. NORMAL VALUES FOR BOVINE PERITONEAL FLUID

Parameter	Result
Odor	None
Color	Colorless-yellow (pinkish late gestation)
Volume	0–5 mL (increased late gestation, postparturition)
Turbidity	Clear—slightly turbid
Total protein	≤3.0 g/dL
Nucleated cell counts	≤10,000
Cytology	Approximately 1:1 neutrophils:mononuclear, variable eosinophils
Specific gravity	<1.018

or ventrally. In addition, one may be able to define specific distended viscera in the paralumbar fossa. Normally, a typical adult cow would have a oval to slightly pear-shaped body contour when viewed from the rear (Fig. 3). Ventral distention is greater with pregnancy and advanced age, particularly on the right side.

Simple Bloat or Rumen Tympany

Obvious left-sided distention when viewed from the rear or side results from rumen tympany or bloat. When viewed from the rear (Fig. 3A), the distention occupies the left upper and lower quadrants. An area of tympanic resonance may be discernible over the left paralumbar fossa, and because of the greater tension on the gas pocket, gaseous pings are generally higher-pitched than those with frothy bloat. Confirmation of rumen distention and consistency is by transrectal palpation, and determination of the type of rumen fill is by passing a stomach tube into the rumen. Rumen tympany is a common occurrence and in the acute stage is usually caused by carbohydrate engorgement (discussed later in this article) or another acute digestive disorder.

Frothy bloat, also known as legume bloat, is the more common form of bloat in most practices and is due to consumption of plants with a high soluble protein concentration. Other than legumes, ryegrass, wheat and other winter annuals, and high concentrate diets and/or slime-producing bacteria in cattle on feed may cause frothy bloat.^{43, 67} The characteristic frothiness is caused by the inadequate coalescence of gas

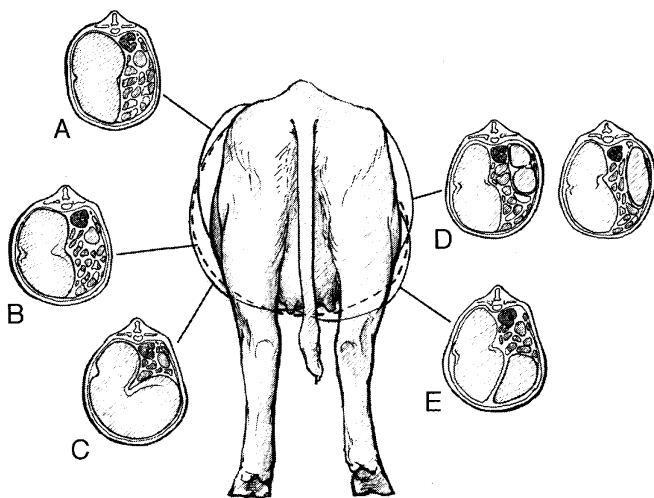


Figure 3. View from rear of cow indicating change of abdominal contour for rumen tympany or free gas bloat (A), frothy bloat (B), vagus indigestion (C), right-sided distention due to cecal volvulus or RTA (D), and abomasal impaction (E).

bubbles in the rumen contents.⁴³ Eructation of the foam is not achieved by the covering of the cardia with fluid and froth, inhibiting reflex opening. Diagnosis is achieved by identification of gas or froth after passage of a stomach tube.

Secondary bloat may be observed due to weak rumen motility and the inability to move the gas layer and clear the cardia subsequent to systemic disease.^{52, 86} Reticulorumen hypomotility may be present in inappetent and febrile cattle.⁴⁸ Occlusion of the esophagus by turnips, sugar beets, apples, or plastic causes bloat and, in some cases of complete obstruction, secondary ptyalism because of the inability to swallow saliva. Other causes of esophageal obstruction causing bloat include pharyngeal paralysis (rabies, listeriosis, botulism) or spasm (tetanus), lesions of the esophageal wall, or compression of the esophagus by mediastinal masses.²⁸

Rumen Lactic Acidosis

History, clinical signs, and rumen fluid evaluation are imperative to the diagnosis of this condition. The history is important to differentiate from metabolic and neurologic diseases that may mimic the clinical presentation. The history of access to large amounts of unaccustomed feeds rich in highly fermentable carbohydrates or poor adaptation to a high concentrate ration in one or more cows may suggest acute ruminal acidosis. Clinical signs vary with the type and quantity of feed ingested and the amount of time elapsed. Common signs include anorexia, depression, bruxism, weakness and dehydration, and loss of normal ruminal layering in the initial phase.⁵⁴ Reticulorumen motility subsides because of an increase in nondissociated volatile fatty acids,²¹ the rumen becomes distended with fluid, and feces become grayish, loose, foul-smelling, and foamy or blood tinged. Due to the increase in carbohydrate breakdown products, the rumen osmolality increases dramatically, contributing to an increased extracellular fluid influx into the rumen exacerbating the dehydration.⁸⁴ Central nervous system derangements caused by severe metabolic acidosis may be observed if the condition is not treated. Rumen fluid pH decreases to 4.5 or less, with decreased protozoa, increased large gram-positive rod bacteria, and decreased sedimentation and flotation rate.⁸⁴ These animals demonstrate a significant metabolic acidemia. Chronic ruminal acidosis leads to rumenitis and laminitis.⁵⁴

Rumenitis

Mechanical or chemical damage to the rumen mucosa may lead to rumenitis. Rumenitis most often occurs as a sequelae to carbohydrate engorgement. Mycotic rumenitis may be diagnosed in cattle that have had rumen acidosis, oral antibiotic treatment, or sepsis.⁸³ Diagnosis of

mycotic rumenitis is based on histopathologic observation of fungal hyphae in rumen wall samples. Rumen fluid may often contain fungal hyphae due to food contaminants. Visualization of the damaged rumen mucosa, fluid rumen contents, inappetance, and decreased rumen motility would lead to a presumptive diagnosis.

Vagus Indigestion

The syndrome of vagus indigestion is a term applied to a number of clinical presentations thought to result from damage to or inflammatory changes in the branches of the vagus nerve as it courses through the thoracic cavity, perireticular area, or the pyloric region.⁶³ Damage appears more common to the ventral vagus nerve than the dorsal vagus, although in some cases, no lesions of the vagus nerve or its branches are identified.¹⁸ Inflammatory lesions have been identified at areas of tension receptors in the reticulorumen wall, which may also account for altered reticulorumen activity.^{35, 82} The most common clinical features of this subacute or chronic syndrome are weight loss, decreased milk production, inappetance, decreased fecal output, and abdominal distention.⁸⁸ Because of the failure of the selective retention of particles in the reticulorumen, resulting feces in these cattle have an increased amount of large particles as compared to healthy cattle.⁸⁸ Depending on the specific site of vagus involvement, the presentations may vary. The syndrome has been classified as one of four types: I—failure of eructation; type II—omasal transport failure; type III—pyloric outflow obstruction; and type IV—indigestion of late gestation.²⁹ Most would classify vagus indigestion as either cranial or caudal functional stenosis.^{12, 31} Realistically, a stenotic lesion is not present. Common causes of vagus indigestion include chronic pneumonia, pleuritis, lymphadenopathy, peritonitis, mechanical obstruction of the reticulomasal orifice, traumatic reticulopericarditis, abomasal volvulus, and abomasal ulcers.²⁹ Dilation and enlargement of the reticuloomasal orifice has been thought to be indicative of vagus indigestion but has not been supported in other studies.

Failure of Eructation

Mechanical interference owing to lymphadenopathy after pneumonia may lead to signs of bloat. Fibropapillomas, granulomas usually caused by *Actinomyces spp* or *Actinobacillus lignierii*, and neoplasms at the cardia may cause mechanical interference with eructation or regurgitation and lead to signs of vagus indigestion.^{6, 63} The animal's condition generally improves with removal of gas but deteriorates as the condition recurs. These conditions are most readily diagnosed by a rumenotomy.

Anterior Functional Stenosis (Omasal Transport Failure)

Omasal transport failure may result from impairment of the process by which the omasum allows for movement of ingesta from the reticulum through the omasal canal into the abomasum. Lesions identified and believed to cause this condition include perireticular or large liver abscesses, traumatic reticuloperitonitis, toxic rumenitis, and neoplasms.⁶³ Proposed mechanisms include interference with the vagus nerve, which disrupts normal tension-receptor activity and causes a mechanical obstruction, or pain inhibiting normal motility.³¹ In addition to common signs for vagus indigestion, bradycardia (≤ 60 beats/min), weak hypermotile rumen contractions, and signs of cranial abdominal pain have been reported.⁶¹ An L-shaped rumen is created as the rumen enlarges with the dorsal sac expanding to the right of midline and the ventral sac enlarging to fill most of the right ventral quadrant of the abdomen⁶³ (Fig. 3C). Rectal palpation is helpful in diagnosing the rumen enlargement and occupation of the right ventral abdominal quadrant. Auscultation of rumen contractions is difficult because of the change in consistency of the rumen contents owing to excess fluid. In addition, ballottement results in appreciation of more fluid content because of the continued accumulation of water and saliva. As there is failure of the water to move aborally and be absorbed, the animal may become dehydrated. Cranial abdominal radiography or ultrasound may be helpful in identifying perireticular foreign bodies or gas accumulation.^{11, 59} If abscesses are present, clinicopathologic data of hyperproteinemia, hypergammaglobulinemia, and elevated white blood cell count and total protein in the peritoneal fluid may be supportive. Left-sided exploratory surgery and rumenotomy may be diagnostic for lesions of the cranial abdomen and therapeutic for removal of foreign bodies and/or drainage of abscesses.

Posterior Functional Stenosis (Pyloric Stenosis)

It is thought that as the consistency of the rumen contents changes to a homogenous pasty mass with a high viscosity caused by disturbances in particle separation processes, the flow of ingesta through the pylorus is inhibited.⁶⁶ Contents of the abomasum change from liquid to pasty, abomasal outflow decreases, and the abomasum becomes distended with digesta. Abomasal reflux into the rumen causes rumen fluid chloride levels to be greater than 30 mEq/L and distention of the omasum and possibly the rumen (Fig. 4). Abdominal distention (papple-shaped) is present on one or both sides (Fig. 3E), with reduced fecal output and accompanying hypovolemia, hypochloremia, hypokalemia, and metabolic alkalosis. Many have elevated total protein and fibrinogen levels. Cows are generally depressed and appear clinically dehydrated and have normal or increased (normal 60-80) heart rates and reduced or absent rumen motility.¹² A definitive diagnosis may be made by laparot-

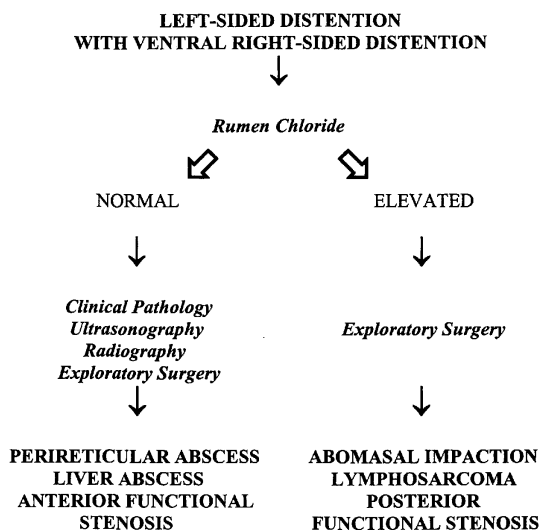


Figure 4. Differentiating causes of bilateral abdominal distention.

omy and identification of a grossly distended nondisplaced abomasum and forestomach. Administration of metoclopramide may result in resolution of clinical signs and support the diagnosis. A similar condition may be encountered in cattle with the adult multicentric form of lymphosarcoma and involvement of the pylorus. Vagus indigestion secondary to right-sided volvulus may occur through either neurogenic or ischemic causes and, generally, abomasal distention becomes evident 2 to 4 days after surgery. Late gestation cows may be more predisposed to this condition,⁸⁵ possibly because of compression of the abomasum or intestine. Diagnosis of this form of indigestion is by exclusion of other causes and a positive response postparturition or after cesarean section.

Abomasal Impaction

Impaction of the abomasum with sand or poor quality feedstuffs may be diagnosed in cattle with a history of progressive abdominal distention primarily in the lower right and upper left as viewed from the rear (Fig. 3E), loss of appetite, weight loss, dehydration, and decreased feces over time. Multiple animals may be affected, usually during the winter months when poor-quality, coarse roughage is fed.^{40, 56} More commonly, this type of obstruction is observed in late gestation beef cattle.^{7, 40} Clinical signs are similar to those described for vagus indigestion (see Fig. 4). Ballottement of the lower right flank area may reveal a firm enlarged abomasum. Transrectal palpation may identify an enlarged rumen and scant or absent feces. Clinicopathologic data in

some are supportive of an abomasal obstruction with a hypochloremic, hypokalemic metabolic alkalosis.⁷ In the latter stages, the animal is weak and recumbent and has a metabolic acidosis.⁴⁰ A definitive diagnosis is achieved by an exploratory laparotomy.

Left-Sided Pings

Areas of tympanitic resonance caused by a gas-fluid interface, gaseous organ distention, or free air in the abdomen may be detected by simultaneous auscultation and percussion of multiple points along and on either side of a line from the left tuber coxae to the point of the left elbow. By placing the stethoscope on the abdominal wall, the adjacent area may be percussed by snapping the finger against the wall. Simultaneous auscultation and succussion of the the abdomen is accomplished by ausculting over an area of increased resonance or ping while using the fist of the opposite hand to repeatedly push deep into the lower abdomen (Fig. 5) and create splashing of fluid trapped within a viscus. On the left side of the abdomen, the main considerations for a ping include a left displaced abomasum, rumen tympany, pneumoperitoneum, an abscess adhered to the left body wall, or rumen collapse/void syndrome.³⁹ Multiple pings may be detected. Passage of a stomach tube may help to eliminate or change a rumen ping, whereas occasionally




Figure 5. Succussion of the bovine abdomen to identify fluid-filled viscus.

blowing into stomach tube with another person auscultating will determine if the ping is rumen in origin.

Left-Displaced Abomasum

Left-displaced abomasum (LDA) is a common condition in dairy cattle and is occasionally seen in beef cattle. The condition occurs as the abomasum becomes anatomically displaced from its normal position on the right side of the abdomen and becomes trapped and gas distended on the left side. An LDA may be visualized as it extends caudally to the 13th rib as a half-moon distention in the left paralumbar fossa with the rest of the paralumbar fossa being sunken in appearance.⁶⁴ In the early stages of the displacement or after hauling in a trailer, pings may be auscultated in the ventral portion of the abdomen, but the more common site would be more dorsally over the 8th to 13th ribs (Fig. 6). Generally, these pings are diagnostic for LDA and no further diagnostics are necessary. With large LDAs, the area of pinging may occupy the majority of the left abdomen. Most LDAs are not palpable transrectally, but the dorsal sac of the rumen may feel displaced medially. In some instances, when multiple pings are auscultated, a stomach tube may be passed to relieve gas from the rumen and thus differentiate abomasal from rumen pings. Obstruction of the abomasum, whether on the left or right, results in accumulation of HCL in abomasum and backflow of this into the rumen may cause an increase greater than 30 mEq/L of Cl⁻ in the rumen fluid.⁸¹ The pH of the rumen fluid is not decreased as cattle that are anorectic generally have elevated pH levels because of continued

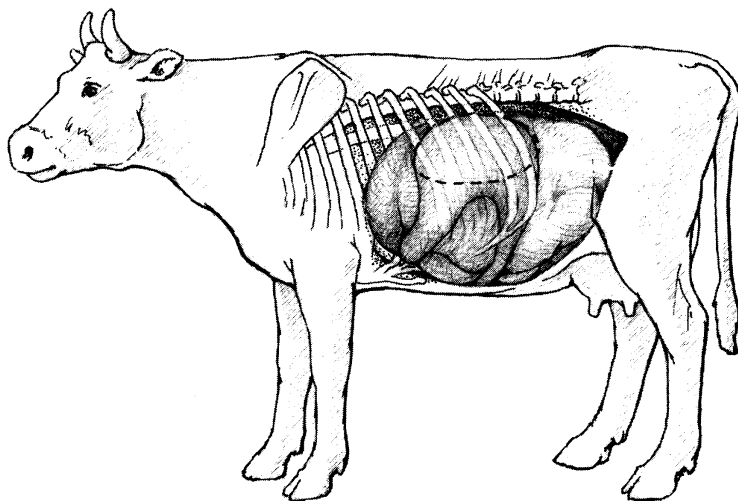


Figure 6. Left displaced abomasum with area of ping indicated by broken line.

saliva buffering of rumen fluid.³⁶ The typical chemistry profile for a cow with an LDA includes a mild to moderate metabolic alkalosis with hypochloremia and hypokalemia. Urine may be alkalotic or a paradoxical aciduria may be observed.⁵⁵

Other Causes for Left-Sided Pings

A rumen collapse syndrome has been described that results in a ping over the left paralumbar fossa and extends dorsally over the transverse processes of the lumbar vertebrae (Fig. 7). The abdomen is not distended and on transrectal examination the dorsal sac of the rumen is felt to be collapsed into the left ventral quadrant of the abdomen.⁶² This condition is presumed to be caused by prolonged anorexia secondary to a primary inflammatory disease or acute and dramatic reduction in feed intake in a high producing dairy cow.

Pneumoperitoneum may result in a left- and right-sided ping and is generally not accompanied by abdominal distention. Transrectal palpation is diagnostic for this condition.

Right-Sided Pings

Simultaneous auscultation and percussion using the same landmarks as on the left side should be used to detect right-sided pings. Succussion is more helpful on the right side than on the left side in differentiating between types of pings. Many organs may be responsible

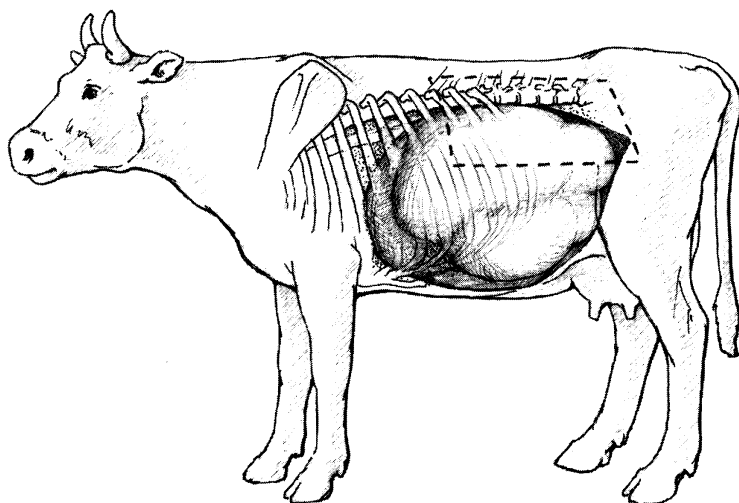


Figure 7. Area of ping for pneumoperitoneum and rumen collapse.

for pings auscultated on the right side of the abdomen. Pneumorectum, created by tenesmus or prior rectal palpation, may create an area of increased resonance on the right side of the abdomen. These findings in conjunction with the rest of the physical examination findings and transrectal palpation may enable a diagnosis to be made. The importance of a thorough transrectal examination of the right abdomen cannot be overemphasized. In some cases, clinical pathology data and/or an exploratory laparotomy may be necessary to achieve the diagnosis.

Right Displaced Abomasum, Abomasal Volvulus

The abomasum is the most common source for right-sided pings in cattle.⁷⁷ A right-displaced abomasum (RDA) is diagnosed by defining a ping from the 13th rib cranially to the 9th rib (Fig. 8) and sometimes visualizing abomasal distention caudal to the last rib. A right-sided abomasal volvulus (RTA) generally is much larger, and tympanitic resonance is appreciable over a greater area (Fig. 9). The RTA can be visualized in the paralumbar fossa and, therefore, palpable per rectum with appreciable right-sided abdominal distention when viewed from the rear (see Fig. 3D). With an RDA, the abomasum is occasionally palpable per rectum. Owing to the nature of the condition, an RTA has more severe clinical signs including dehydration, tachycardia, and greater abdominal distention. Because the obstructions generally are more complete as opposed to LDAs, rumen chloride levels are more consistently elevated.⁸¹ Initially with an RDA and an acute RTA, a hypochloremic, hypokalemic

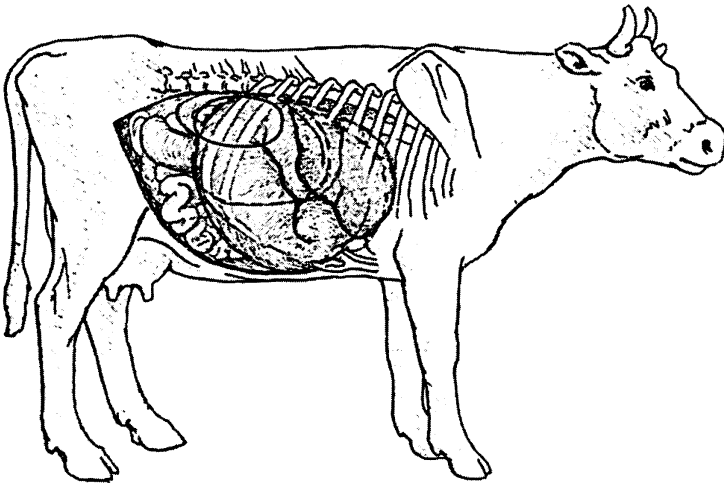


Figure 8. Right displaced abomasum when viewed from the side. *Dashed line* indicates the area of ping.

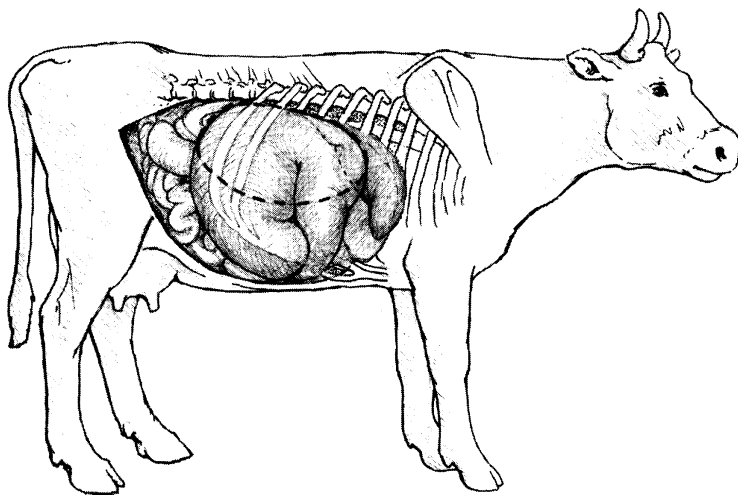


Figure 9. Abomasal volvulus (RTA) when viewed from the side. *Dashed line indicates the area of ping.*

metabolic alkalosis may be identified. If the condition becomes more long-standing, viability of the abomasal musculature is compromised, and a metabolic acidosis may result.

Cecal Dilatation/Volvulus

Cattle with cecal dilatation may be asymptomatic, and the condition may be an incidental finding per rectum but may progress to a cecal volvulus, necessitating surgery. Cecal dilatation or volvulus creates a ping in the right paralumbar fossa and caudal quadrant, which may extend cranially and ventrally, depending upon the amount of distention (Fig. 10). In many instances, cecal distention is observed in the paralumbar fossa when viewed from the side. When viewed from the rear, marked distention of the right paralumbar fossa is observed (see Fig. 3D). Succussion elicits splashing sounds within the distended cecum. Transrectal palpation is generally diagnostic for a cecal volvulus when the apex of the cecum or the distended revolutions are palpated. Distended loops of proximal colon and, occasionally, distended loops of small intestine may also be palpable per rectum. Signs of colic, although relatively rare in cattle compared to horses, may be observed with cecal volvulus and include kicking at the abdomen, treading with the rear feet, lying down or standing and stretching out, and possibly an anxious or apprehensive attitude. In addition, these cases generally are tachycardic, tachypenic, and dehydrated with scant or no feces. Most cases have normal clinicopathologic data, but with continued obstruction at the

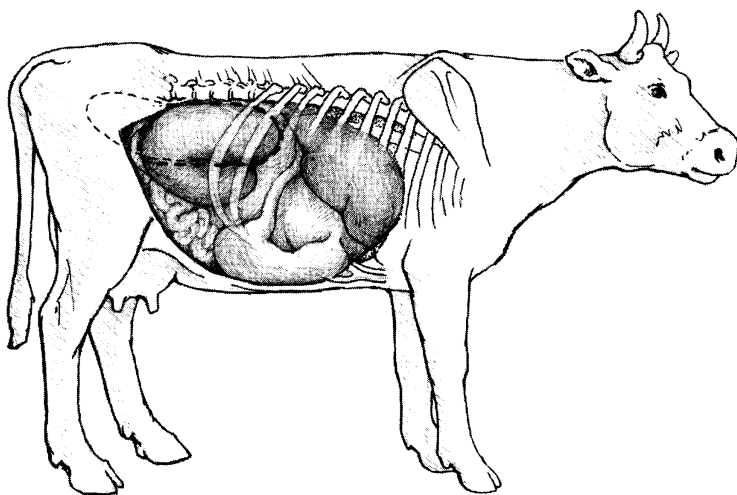


Figure 10. Anatomic location of cecal volvulus. *Dashed line* represents ping area.

ileocecocolic orifice, a hypochloremic, hypokalemic metabolic alkalosis may develop.³²

Proximal Colon Distention

On the right side of the abdomen it is quite common to detect an area of resonance caused by distention of the proximal colon in the right paralumbar fossa, which may extend cranially two to three rib spaces (not as far cranially as an RDA) (see Fig. 8). These pings are not consistently identified, do not result in distention of the paralumbar fossa, and succussion of the area generally does not reveal fluid splashing as would an RDA/RTA.⁶⁵ It is important to differentiate these pings from abomasal or cecal pings, as a ping of the proximal colon as surgical intervention is not warranted.

Intussusception

Intussusception in cattle is characterized by an acute onset of anorexia, decreased feces, dehydration, decreased milk production, and signs of abdominal pain. After the first day, signs of discomfort are not as pronounced and the animal becomes more lethargic and depressed.⁷⁵ The most common site of the intussusception is the jejunum, and although it does occur in adult cattle, the condition does appear to have an age predisposition for young calves.¹⁹ Abdominal distention is not appreciable in the early stages but becomes pear-shaped as the condition

progresses and later becomes greatly distended with a round contour when viewed from the rear (Fig. 11A and B). Inconsistently, multiple small pings may be auscultated in and adjacent to the right paralumbar fossa (Fig. 11C). Succussion and auscultation indicate fluid and gas within the intestine. A diagnosis may be achieved by transrectal palpation of multiple, dilated, turgid small intestine, and in some instances, the actual intussusception. In some cases, the small intestines are not only in the right abdominal cavity but in the left abdominal cavity and into the pelvic canal as well. Transrectal palpation of cows in midgestation to late gestation with an intussusception may reveal a dorsocaudally displaced uterus with distended small intestine not palpable.⁷⁶ Feces become scant and mucoid with melena or hematochezia present. Hyponatremia, hypochloremia, hypocalcemia, azotemia, and hyperglycemia were identified in analysis of 57 case records.¹⁹ Abdominocentesis yields a large volume of fluid with an elevated protein and nucleated white cell count, with severity corresponding to the duration of the disease process.

Segmental volvulus of the jejunoileum and volvulus of small and large intestine around the mesenteric root may also cause signs of severe colic, but these cases deteriorate more rapidly than intussusception cases

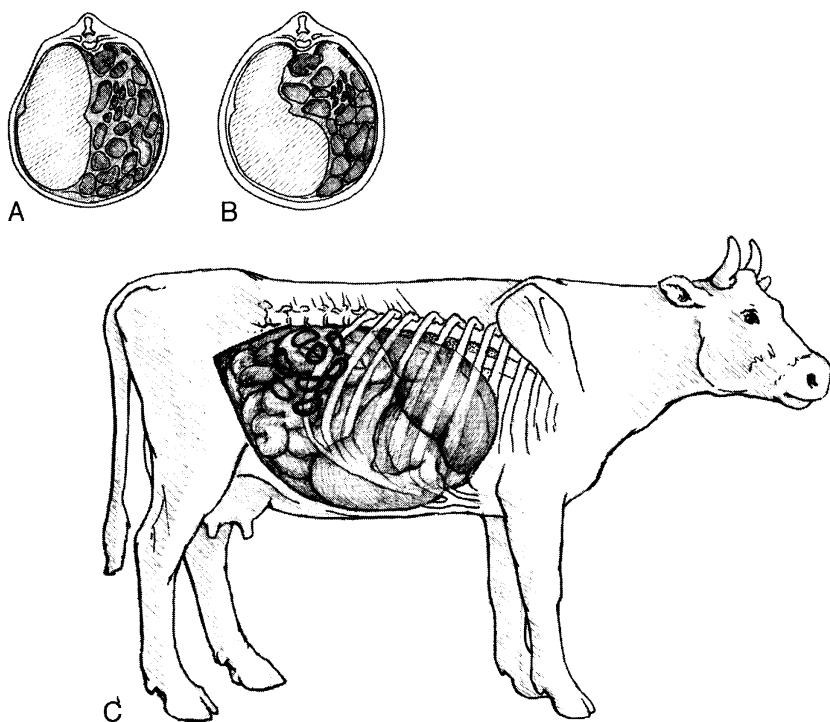


Figure 11. Areas of ping associated with an intussusception. View from the rear with an acute intussusception (A) and late intussusception (B), and viewed from the side (C).

if surgical intervention is not instituted. Incarceration or entrapment of jejunum or ileum has been reported because of persistent urachal remnant, a persistent round ligament, and mesenteric rents.^{5, 26, 34}

Other Causes for Right-Sided Pings

Pneumorectum, pneumoperitoneum, enlarged ventral sac of rumen caused by vagal indigestion, and rarely, physometra may result in areas of tympanic resonance on the right upper quadrant. Of these, only pneumoperitoneum and vagal indigestion result in abdominal distention. Differentiation of these pings from other right-sided pings requiring surgery is important and most easily accomplished by rectal examination.

ANTERIOR ABDOMINAL PAIN

Cattle in pain may display an expiratory grunt, appear reluctant to move, stand with elbows abducted and their back arched, have tachycardia, grunt when pinched over the withers, and display bruxism.⁴² Forceful movement with the knee or upward pressure with a bar or pole over the xyphoid area or anterior abdomen elicits additional grunts or a kick response. Auscultation over the trachea may be necessary to hear subtle grunts. It is important to differentiate thoracic pain from abdominal pain, although in some instances, both may be present.

Traumatic Reticuloperitonitis

The most common cause of anterior abdominal pain in cattle is traumatic reticulitis/reticuloperitonitis caused by penetration of a foreign body (most often wire and nails) through the reticular wall resulting in septic reticulitis and peritonitis.⁴² An acute onset of anorexia, decreased milk production, decreased rumen motility with or without rumen distention, cranial abdominal pain, and mild pyrexia characterize acute traumatic reticuloperitonitis.²⁴ If these areas are also penetrated, subsequent pericarditis, myocarditis, thoracic, hepatic, or perireticular abscesses may result. With more chronic cases, decreases may be observed in appetite, fecal output, and milk production, with persistent but less intense signs of anterior abdominal pain. A complete blood count may demonstrate an elevated white blood cell count, with a neutrophilia and a left shift, and hyperfibrinogenemia.

Standing radiography of the reticular region is considered to be a sensitive indicator of traumatic reticuloperitonitis,^{33, 59} however, according to one study it does not always indicate if the foreign body is penetrating.²⁵ Unfortunately, the forelimb and fluid in the reticulum, pleural space, or pericardium may interfere with achieving the diagnosis. If the foreign body is seen to be fully attached to a magnet, it is unlikely

to be perforating the reticulum.³³ Ultrasonography of the reticulum may be helpful for defining its appearance and perireticular structures but not for assessing reticular contents.¹¹ In some cases, a left-sided laparotomy (+ / - rumenotomy) are necessary for a diagnosis.

Abomasal Ulcers

With abomasal ulcers in cattle, there is generally a history of a change in diet or stress associated with parturition, hauling, or high milk production. Feedlot cattle fattened on corn based rations had a higher incidence of abomasal erosions than those cattle not fed corn in their ration.⁴⁰ Common clinical signs include melena, anorexia, decreased milk production, anemia, and concurrent signs of anterior abdominal pain. Abomasal ulcers may be classified as one of the following: Type I, nonperforating ulcers; type II, ulcer causing severe blood loss; type III, perforating with acute, localized peritonitis; and type IV, perforating ulcer with diffuse peritonitis.⁷⁸ Approximately 50% of cattle with abomasal ulcers have type I.⁷² Most cows with abomasal ulcers have concurrent problems including LDA, lymphosarcoma, metritis, and mastitis.^{13, 58} Pneumoperitoneum, fever, anterior abdominal pain, and abnormal abdominocentesis may lead to the presumptive diagnosis of a perforated ulcer. Testing for fecal occult blood has been demonstrated to be a more sensitive test than the presence of melena.⁷² The diagnosis of abomasal ulcer with minimal bleeding is difficult and is made by elimination of other diseases, a positive fecal occult blood or presence of melena, and negative abdominocentesis.⁴⁵

DIARRHEA

Viral Causes

Bovine Viral Diarrhea Virus

Despite much research, bovine viral diarrhea virus (BVDV) continues to present itself as a challenging infectious disease. Many strains of BVDV exist and, based on genomic differences, BVDV can be further classified as either genotype I or II.⁶⁰ Two biotypes of BVDV exist based on the cytopathogenicity in cell culture: cytopathic (CP) and noncytopathic (NCP). Infection of cattle with either or both biotypes may induce a variety of clinical presentations affecting multiple organ systems.⁴

Acute BVDV in immunocompetent cattle may cause diarrhea. Most BVDV infections are subclinical, but when clinical signs of BVDV occur, anorexia, oculonasal discharge, diarrhea, pyrexia, and hemorrhage may be observed. Herd outbreaks may occur. Diagnosis is made by virus isolation from tissue samples, serum, or buffy coat, or seroconversion to BVDV. It is important that acute and convalescent serology are requested for antibody levels to both type I and II BVDV.

Calves that were infected in utero with a NCP BVDV before their immune system was capable of mounting an immune response against a foreign antigen may be born immunotolerant to BVDV and persistently infected with the NCP BVDV. These animals may experience acute or chronic mucosal disease (MD) if the NCP mutates to a CP strain or if the animal is infected with a closely related CP BVDV.¹⁰ MD in most animals occurs at less than 2 years of age. Clinical signs of acute MD are characterized by pyrexia, oral, nasal, interdigital, and gastrointestinal ulcerations, and after 2 to 3 days, profuse, watery, foul-smelling diarrhea. Mortality is generally near 100%, but an occasional animal does survive and presents as an emaciated, unthrifty animal, with continual or intermittent diarrhea and erosive skin lesions, and eventually dies of debilitation. Because these animals are persistently infected and continually shedding virus, either whole blood, serum, or tissue samples may be submitted for virus isolation. A CP and a NCP BVDV may be isolated.¹⁰

Winter Dysentery

Winter dysentery is a problem in adult cattle, generally in housed dairy cattle in the winter, characterized by an acute onset of tan to dark hemorrhagic diarrhea accompanied by decreased milk production and varying degrees of inappetence and depression. Within 2 to 3 days, the clinical signs resolve in the individual animal, and within 2 weeks, the herd outbreak is over. Although morbidity rates may be high, mortality is rare.⁴¹ Previously, the disease was thought to be caused by *Campylobacter jejuni*.¹⁴ Coronavirus may play a role in the etiology of winter dysentery as it has been detected in feces by fluorescent antibody, electron microscopy, and by an ELISA used for the detection of the coronavirus antigen.^{27, 30, 70} Paired serum samples may be submitted to detect antibodies to coronavirus. Diagnosis is generally by exclusion of other causes of epizootics of diarrhea.

Other Viruses

A torovirus and a group B rotavirus have also been identified from feces of adult cattle with diarrhea.^{50, 70} Malignant catarrhal fever is generally fatal in cattle and causes pyrexia, oral erosions, mucopurulent nasal discharge, corneal opacity, lymphadenopathy, and diarrhea. Diagnosis for the causative agent, ovine herpesvirus-2, is by submission of whole blood or fixed lung, liver, lymph node, or kidney for PCR. Not all laboratories perform this test.

Bacterial Causes

Salmonella

The most common signs of *Salmonella* infection are pyrexia (40–41°C) and diarrhea that may be watery to mucoid with blood and fibrin

and fetid smelling.⁷¹ Septicemia, death, and abortions may also occur. Increased incidence of salmonellosis appears to be associated with intense management practices as on large farms, crowded conditions, and high-protein diets⁷⁴ as well as host (age, immune status) and *Salmonella* serotype factors. More than 2200 *Salmonella* serotypes have been described, with *Salmonella dublin*, *Salmonella typhimurim*, and *Salmonella newport* being some of the most common isolated from cattle. Of these, only *S. dublin* is host-adapted in cattle and can result in a long-term carrier state.⁵³ Diagnosis is by submission of 5 to 10 grams of feces for culture. Depending on the laboratory, serotype, serogroups, and/or phage type may be determined to further classify the organism for epidemiologic purposes.⁵³

Mycobacterium paratuberculosis (Johne's Disease)

Although cattle are most commonly infected as calves, clinical signs of infection with *Mycobacterium paratuberculosis* (Johne's disease) are generally observed in adult cattle (Fig. 12). The organism causes diffuse granulomatous changes in the distal ileum resulting in a protein-losing enteropathy. The most common clinical signs include diarrhea (in early stages may be intermittent), weight loss, and decreased milk production, with maintenance of appetite. Clinicopathologic data may demonstrate an anemia of chronic disease and hypoproteinemia. Diagnosis of the causative organism is by either fecal culture (100% specificity) that can take from 12 to 16 weeks depending on the culturing methods, serology, histopathology, or PCR of feces/tissues. Radiometric fecal culturing methods may reduce the time by approximately one half.¹⁷ The DNA probe (IDEXX Laboratories, Westbrook, ME) detects the IS900 insertion sequence in *M. paratuberculosis* and results are available in 3 days. The test, although very specific, is less sensitive than the fecal culture and more expensive.⁸⁷ An agar gel immunodiffusion (AGID) test and an ELISA are offered for detection of antibodies to *M. paratuberculosis*. A positive AGID or ELISA test in an animal showing clinical signs of Johne's disease is fairly reliable as the tests are more than 99% specific.⁷⁹ Because the organism is slow growing, the ability to diagnose antibodies to *M. paratuberculosis* is limited in the early stages of infection and increases as the disease progresses. For herd surveillance, the ELISA test is more economical, approximately 99% specific with varied sensitivity depending upon the prevalence of Johne's in the herd, but more sensitive than the AGID test.¹⁶ A complement fixation test is used by some laboratories with titers to *M. paratuberculosis* $\geq 1:32$ considered positive. As animals in the terminal stages of the disease may be anergic, negative serology results in animals demonstrating clinical signs of Johne's disease should be confirmed by intestinal biopsy, fecal culture, or both. With Johne's disease, the intestine is thickened with a corrugated appearance and regional lymph nodes are enlarged and edematous. Histopathology, culture, or PCR of the distal ileum or ileocecal lymph nodes may be used to confirm a diagnosis. In certain laboratories, identification

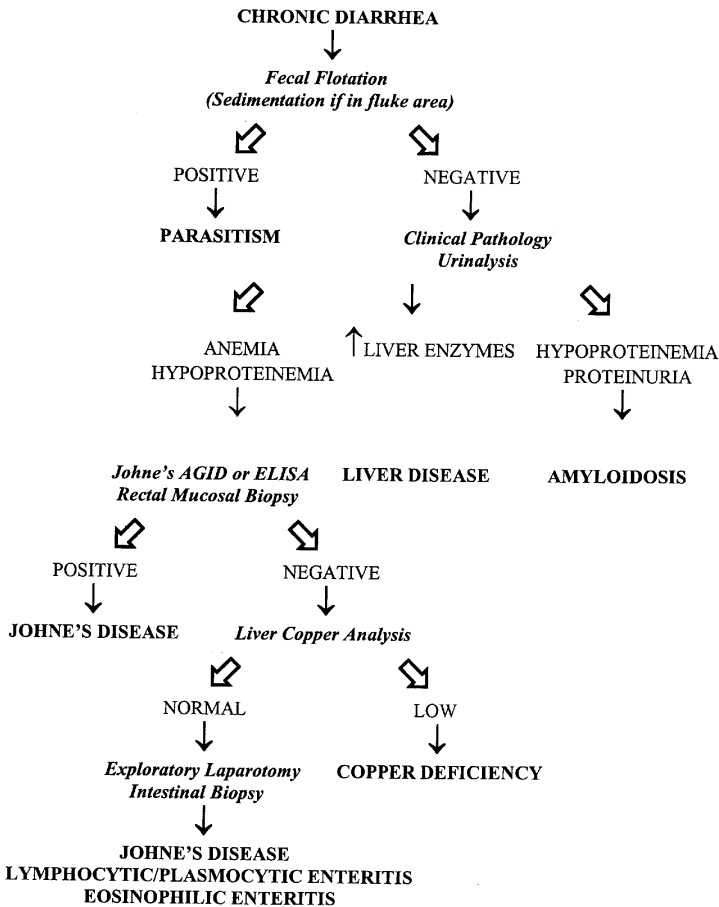


Figure 12. Differentiating causes of diarrhea in adult cattle. AGID = agar gel immunodiffusion; ELISA = enzyme-linked immunosorbent assay.

of acid-fast organisms from rectal scrapings or feces are used diagnostically for animals with clinical signs of Johne's disease.

Toxic Causes

Many toxic causes for diarrhea have been identified. Oak (*Quercus sp*) bud or acorn toxicity is characterized by anorexia, depression, edema, decreased rumen motility, and constipation followed by hemorrhagic diarrhea in cattle.⁸⁰ Azotemia, hyponatremia, hyperkalemia, hyperphosphatemia, and hypocalcemia, with a metabolic acidosis may be observed in the acute cases. With the peracute form, animals may be found dead. Significant lesions at necropsy include hydrothorax, hydropericardium,

perirenal and subcutaneous edema, and ulcerative lesions throughout the gastrointestinal tract.⁷³ Diagnosis is achieved by a history of access to the young leaves or buds in the spring or acorns in the fall with the accompanying clinical signs.

Although other signs of hepatic disease or vasculitis may be observed, mycotoxins (aflatoxins), inorganic arsenic, and pyrrolizidine alkaloids (*Senecio*, *Crotalaria*, *Amsinkia*) cause diarrhea.⁹

Nutritional Causes

Copper deficiency should be considered in cattle with chronic diarrhea (see Fig. 12). This condition may present as an individual or herd problem. Elevated molybdenum in the diet may induce a copper deficiency even with adequate copper levels in the feed or pasture. Interactions also occur with iron and sulfur, and less commonly with zinc and cadmium, indicating a need to evaluate all when diagnosing what appears to be a dietary imbalance of copper.⁴⁴ Coexisting clinical signs may include hair color and quality changes, anemia, and lameness in young calves. The liver is the main storage area of copper and after this storage supply is depleted (<40 mg/kg), blood copper concentration decreases. With herd problems, a large number of livers must be biopsied to obtain a reasonable estimate of herd copper status, thus, some would prefer to measure blood copper, assuming liver supplies are depleted.³⁸ Response to copper sulfate supplementation of the salt/mineral mix or oxidized copper wire particles administered to affected animals may be diagnostic.

Cobalt deficiency may cause diarrhea and may increase susceptibility to *Ostertagia ostertagi* infestation. With any dietary change, cattle may experience a transient diarrhea, although with ruminal acidosis (discussed previously) the animals display other clinical signs. Administration of cathartics (MgO, MgSO₄) for cases of indigestion or excess magnesium in the feed because of a mixing error results in diarrhea, either in an individual animal or a herd, respectively.

The use of high-nitrogen fertilizers (chicken manure) or fescue-type pasture predisposes to abdominal fat necrosis.⁶⁸ This condition, while not common, should be considered with cases displaying anorexia, gastrointestinal obstruction, constipation, diarrhea, and weight loss. Diagnosis is either by rectal palpation of firm masses or by laparotomy.⁴⁶

Parasite Causes

Gastrointestinal nematode infestations can be an important cause of diarrhea in certain areas of the country (see Fig. 12). Of the nematodes infesting cattle, *O. ostertagi* is the most important.²⁰ It is one of the only nematode species that can cause diarrhea in adult cattle, as resistance to this parasite takes longer to become established.²⁰ Clinical signs of chronic diarrhea, weight loss, and variable appetite are common in parasitized animals.

Direct fecal smears are of no value in diagnosis of nematode infestations, but quantitative fecal flotation techniques are quick and easy diagnostic tools. Their results, however, can be misleading for several reasons. First, most flotation methods were designed for sheep and goats, which are more commonly infected with nematode parasites that are more fecund than *Ostertagia*. These methods may not be sensitive enough to pick up the low numbers of parasite eggs shed by cattle.^{8, 20, 37} The technique recommended for cattle is the modified Wisconsin technique.⁸ Second, clinically normal animals can shed nematode eggs in their feces, which makes interpretation of positive results difficult. Third, cattle with type II ostertagiasis may have negative fecal examinations. Type II ostertagiasis occurs when large numbers of arrested larva suddenly emerge when climate conditions are favorable. Because there are no adults present, fecal examinations are negative. In these cases, measurement of serum pepsinogen, which rises during type II ostertagiasis, may be helpful.³ Diagnosis based on response to treatment is common but can also be misleading. Cattle that undergo type II disease can have such severe abomasal damage that the abomasum heals with significant scarring. These animals have poor digestive function and will continue to have chronic diarrhea despite treatment with effective anthelmintics.

Fluke infestations can cause chronic diarrhea in geographic areas where the aquatic snail intermediate host can survive. Fluke eggs are not found with fecal flotation methods, and diagnosis requires special sedimentation techniques. These tests also can be misleading, because low numbers of eggs are passed by species with patent infections, and no eggs are passed by species that do not produce patent infections. Response to treatment can also be misleading, as flukicides are really only effective against the adult stages, and damage can be so severe that treatment is too late.⁹⁰

Miscellaneous Causes

Infiltrative or inflammatory bowel disease may result in chronic diarrhea in cattle (see Fig. 12). Diagnostics should be pursued as some conditions are responsive to appropriate treatment. Eosinophilic enteritis has been diagnosed by intestinal biopsy in cattle with chronic diarrhea and weight loss.¹⁵ Amyloidosis in cattle is rare but should be considered for chronic diarrhea in cattle with generalized edema, hypoproteinemia, azotemia, and proteinuria (see Fig. 12).⁴⁷ With marked proteinuria and other urinary parameters within normal limits, a presumptive diagnosis of amyloidosis may be made. Definitive diagnosis of the disease is by renal biopsy and identification of extracellular amyloid deposition.⁴⁷ Enlarged mesenteric lymph nodes and thickened edematous small intestine were significant findings in these cattle.

Other less common causes of chronic diarrhea to consider are chronic peritonitis, thrombosis of the caudal vena cava, heart failure,

neoplasia, and ascites from any cause.⁶⁸ Cases of gastrointestinal obstruction generally have diarrhea, which resolves within 3 to 4 days after the obstruction is corrected.

SUMMARY

Many of the common gastrointestinal disorders of adult cattle may be diagnosed by a careful physical examination, whereas other disturbances require the use of diagnostic testing. It is important to differentiate the causes of gastrointestinal disturbances to make better treatment decisions and have a clearer prognosis for the specific animal or herd of cattle.

ACKNOWLEDGMENTS

The authors wish to thank Lisa Makarchuk for her help with the figures, Rachel Eddleman for technical assistance, and Gatz Riddell, DVM, MS, for his review of this article.

References

1. Alonso AN: Diagnostic analysis of rumen fluid. *Vet Clin North Am Food Anim Pract* 1:363, 1979
2. Anderson DE, Cornwell D, St-Jean G, et al: Comparison of peritoneal fluid analysis before and after exploratory celiotomy and omentopexy in cattle. *Am J Vet Res* 55:1633, 1994
3. Baker DG, Bruss ML, Gershwin LJ: Abomasal interstitial fluid-to-blood concentration gradient of pepsinogen in calves with type-1 and type-2 ostertagiosis. *Am J Vet Res* 54:1294, 1993
4. Baker JC: The clinical manifestations of bovine viral diarrhea infection. *Vet Clin North Am Food Anim Pract* 10:425, 1994
5. Baxter GM, Darien BJ, Wallace CE: Persistent urachal remnant causing intestinal strangulation in a cow. *J Am Vet Med Assoc* 191:555, 1987
6. Bertone AL, Roth LR, O'Krepky J: Forestomach neoplasia in cattle. *Compendium on Continuing Education for the Practicing Veterinarian* 7:S85, 1985
7. Blikslager AT, Bristol DG, Hunt EL: Abomasal impaction in cattle. *Compendium on Continuing Education for the Practicing Veterinarian* 15:1571, 1993
8. Bliss DH, Kvasnicka WG: The fecal examination: A missing link in food animal practice. *Compendium on Continuing Education for the Practicing Veterinarian* 19:S112, 1997
9. Blood DC, Radostits OM: Diseases caused by chemical agents. In Blood DC, Radostits OM (eds): *Veterinary Medicine*, Philadelphia, Bailliere Tindall, 1990, p 1239
10. Bolin SR: The pathogenesis of mucosal disease. *Vet Clin North Am Food Anim Pract* 11:489, 1995
11. Braun U, Gotz M: Ultrasonography of the reticulum in cows. *Am J Vet Res* 55:325, 1994
12. Braun U, Kaegi B, Steiner A: Clinical, haematological and biochemical findings and the results of treatment in cattle with acute functional pyloric stenosis. *Vet Rec* 126:107, 1990
13. Cable CS, Rebhun WC, Fubini S, et al: Concurrent abomasal displacement and perforating ulceration in cattle: 21 cases. *J Am Vet Med Assoc* 212:1442, 1998
14. Campbell SG, Cookingham CA: The enigma of winter dysentery. *Cornell Vet* 68:423, 1978

15. Cebra ML, Cebra CK, Garry FB, et al: Idiopathic eosinophilic enteritis in four cattle. *J Am Vet Med Assoc* 212:258, 1998
16. Collins MT: Diagnosis of paratuberculosis. *Vet Clin North Am Food Anim Pract* 12:357, 1996
17. Collins MT, Kenefick KB, Sockett DC, et al: Enhanced radiometric detection of *Mycobacterium paratuberculosis* by using filter-concentrated bovine fecal specimens. *J Clin Microbiol* 28:2514, 1990
18. Constable PD, Hoffsis GF, Rings DM: The reticulorumen: Normal and abnormal motor function. Part II. Secondary contraction cycles, rumination, and esophageal groove closure. *Compendium on Continuing Education for the Practicing Veterinarian* 12:1169, 1990
19. Constable PD, St. Jean G, Hull BL, et al: Intussusception in cattle: 336 cases (1964–1993). *J Am Vet Med Assoc* 210:531, 1997
20. Craig TM: Deworm in winter, spring, summer, or fall? Developing successful internal parasite control programs. *Compendium on Continuing Education for the Practicing Veterinarian* 19:S112, 1997
21. Crichlow EC, Chaplin RK: Ruminal lactic acidosis: Relationship of forestomach motility to nondissociated volatile fatty acids levels. *Am J Vet Res* 46:1908, 1985
22. Dirksen G: Forestomachs. In Rosenberg G (ed): *Clinical examination of cattle*. Berlin, Verlag Paul Parey, 1979, p 197
23. Dirksen G, Smith MC: Acquisition and analysis of bovine rumen fluid. *Bovine Practice* 22:108, 1987
24. Ducharme NG: Surgical considerations in the treatment of traumatic reticuloperitonitis. *Compendium on Continuing Education for the Practicing Veterinarian* 5:S213, 1983
25. Ducharme NG, Dill SG, Rendana VT: Reticulography of the cow in dorsal recumbency: An aid in the diagnosis and treatment of traumatic reticuloperitonitis. *J Am Vet Med Assoc* 182:585, 1999
26. Ducharme NG, Smith DF, Koch DB: Small intestinal obstruction caused by a persistent round ligament of the liver in a cow. *J Am Vet Med Assoc* 180:1234, 1982
27. Durham PJK, Hassard LE, Armstrong KR: Coronavirus-associated diarrhea (winter dysentery) in adult cattle. *Can Vet J* 30:825, 1989
28. Espinasse J, Kuiper R, Schelcher F: Pathophysiology of the bovine stomach. *Bovine Practice* 26:105, 1991
29. Ferrante PL, Whitlock RH: Chronic (Vagus) indigestion in cattle. *Compendium on Continuing Education for the Practicing Veterinarian* 3:S231, 1981
30. Fleetwood AJ, Edwards S, Foxell PW, et al: Winter dysentery in adult dairy cattle. *Vet Rec* 125:553, 1989
31. Fubini SL: Failure of omasal transport attributable to perireticular abscess formation in cattle: 29 cases (1980–1986). *J Am Vet Med Assoc* 194:811, 1989
32. Fubini SL: Surgery of the bovine large intestine. *Vet Clin North Am Food Anim Pract* 6:461, 1990
33. Fubini SL, Yeager AE, Mohammed HO, et al: Accuracy of radiography of the reticulum for predicting surgical findings in adult dairy cattle with traumatic reticuloperitonitis: 123 cases (1981–1987). *J Am Vet Med Assoc* 197:1060, 1990
34. Garber JL, Madison JB: Signs of abdominal pain caused by disruption of the small intestinal mesentery in three postparturient cows. *J Am Vet Med Assoc* 198:864, 1991
35. Garry F: Managing forestomach problems caused by motor disease. *Vet Med* 85:651, 1990
36. Garry FB: Clinical signs and differential diagnosis of indigestion. In Smith BP (ed): *Large Animal Internal Medicine*, St. Louis, Mosby, 1996, p 843
37. Gasbarre LC, Leighton EA, Bryant D: Reliability of a single fecal egg per gram determination as a measure of individual and herd values for trichostrongyle nematodes of cattle. *Am J Vet Res* 57:168, 1996
38. Gay CC, Parish SM: Copper deficiency in cattle. In *Proceedings of the 16th American College of Veterinary Medicine Forum* 1998, San Diego, CA, p 260
39. Grymer J, Ames NK: Bovine abdominal pings: Clinical examination and differential diagnosis. *Compendium on Continuing Education for the Practicing Veterinarian* 3:S311, 1981

40. Guard C: Abomasal impaction. *In* Smith BP (ed): Large Animal Internal Medicine, St. Louis, Mosby, 1996, p 878
41. Guard C: Winter dysentery. *In* Smith BP (ed): Large Animal Internal Medicine, St. Louis, Mosby, 1996, p 892
42. Henninger RW, Mullooney PC: Anterior abdominal pain. *Compendium on Continuing Education for the Practicing Veterinarian* 6:S453, 1984
43. Howarth RE, Cheng KJ, Majak W, et al: Ruminant bloat. *In* Milligan LP, Grovum WL, Dobson A (eds): Control of Digestion and Metabolism in Ruminants. Englewood Cliffs, NJ, Prentice-Hall, 1986, p 516
44. Humphries WR, Phillipppo M, Young BW, et al: The influence of dietary iron and molybdenum on copper metabolism in calves. *Br J Nutr* 49:77, 1983
45. Jensen R, Spraker TR, Glock RD, et al: Abomasal erosions in feedlot cattle. *Am J Vet Res* 53:110, 1992
46. Johnson R, Ames NK, Dunstan R: Abdominal fat necrosis in a heifer. *Compendium on Continuing Education for the Practicing Veterinarian* 7:S103, 1985
47. Johnson R, Jamison K: Amyloidosis in six dairy cows. *J Am Vet Med Assoc* 185:1538, 1984
48. Kasari TR: Medical management of common physiologic and metabolic abnormalities in anorectic cattle. *Vet Med* 9:898, 1994
49. Keefe GP, Ogilvie TH: Comparison of oro-ruminal probe and rumenocentesis for prediction of rumen pH in dairy cattle. *Proceedings of the American Association of Bovine Practitioners* 30:168-169, 1997
50. Koopmans MM-SL, Schukken YH: Association of diarrhea in cattle with torovirus infections on farms. *Am J Vet Res* 52:1769, 1991
51. Kopcha M, Schultze AE: Peritoneal fluid: part II. Abdominocentesis in cattle and interpretation of noneoplastic samples. *Compendium on Continuing Education for the Practicing Veterinarian* 13:703, 1999
52. Leek BF: Reticulo-ruminal function and dysfunction. *Bet Rec* 84:238, 1969
53. McDonough PL: Salmonellosis: diagnostic approach to disease control and epidemiology in the bovine animal. *In* Proceedings of the 27th Annual American Association of Bovine Practitioners Convention 1995, Pittsburgh, PA, 27:61
54. McGuirk SM: Ruminant acidosis. *In* Proceedings of the 12th American College of Veterinary Medicine Forum 1994, San Francisco, CA, pp 689-691
55. McGuirk SM, Butler DG: Metabolic alkalosis with paradoxical aciduria in cattle. *J Am Vet Med Assoc* 177:551, 1980
56. Mitchell KJ: Dietary abomasal impaction in a herd of dairy replacement heifers. *J Am Vet Med Assoc* 198:1408, 1991
57. Nordlund KV, Garrett EF, Oetzel GR: Herd-based rumenocentesis: A clinical approach to the diagnosis of subacute rumen acidosis. *Compendium on Continuing Education for the Practicing Veterinarian* 548, 1999
58. Palmer JE, Whitlock RH: Bleeding abomasal ulcers in adult dairy cattle. *J Am Vet Med Assoc* 183:448, 1983
59. Partington BP, Biller DS: Radiography of the bovine cranioventral abdomen. *Vet Radiol* 32:155, 1991
60. Pellerin C, van den Hurk J, Lecomte J, et al: Identification of a new group of bovine viral diarrhea virus strains associated with severe outbreaks and high mortalities. *Virology* 203:260, 1994
61. Rebhun WC: Vagus indigestion in cattle. *J Am Vet Med Assoc* 176:506, 1980
62. Rebhun WC: Rumen collapse in cattle. *Cornell Vet* 77:244, 1987
63. Rebhun WC: Vagus indigestion in cattle: Clinical features, causes, treatments, and long term follow up of 112 cases. *Compendium of Continuing Education for the Practicing Veterinarian* 10:387, 1988
64. Rebhun WC: Differentiating the causes of left abdominal tympanitic resonance in dairy cattle. *Vet Med* 11:1126, 1991b
65. Rebhun WC: Right abdominal tympanitic resonance in dairy cattle: Identifying the causes. *Vet Med* 11:1135, 1991a
66. Rehage J, Kaske M, Stockhofe-Zurwieden N, et al: Evaluation of the pathogenesis of

- vagus indigestion in cows with traumatic reticuloperitonitis. *J Am Vet Med Assoc* 207:1607, 1995
67. Roussel AJ: Ruminant fluid sampling and analysis. *In* Proceedings of the North American Veterinary Conference, 1994, Orlando, FL, pp 689-690
 68. Roussel AJ, Whitlock RH: Chronic diarrhea in cattle: Differential diagnosis. *Compendium on Continuing Education for the Practicing Veterinarian* 12:423, 1990
 69. Roussel AJ: Rumen analysis as a diagnostic tool. *In* Proceedings of the 10th Annual American College of Veterinary Medicine Forum, 1988, pp 165-168
 70. Saif LJ, Brock KV, Redman DR, et al: Winter dysentery in dairy herds: Electron microscopic and serological evidence for an association with coronavirus infection. *Vet Rec* 128:449, 1991
 71. Scott P: Management of a salmonellosis outbreak in a cattle herd. *In* Practice 17-20, 1994
 72. Smith DF, Munson L, Erb HN: Predictive values for clinical signs of abomasal ulcer disease in adult dairy cattle. *Prev Vet Med* 3:573, 1986
 73. Smith BP: Oak (Acorn) toxicosis. *In* Smith BP (ed): Large Animal Internal Medicine, St. Louis, Mosby, 1996, p 890
 74. Smith BP: Salmonellosis in ruminants. *In* Smith BP (ed): Large Animal Internal Medicine, St. Louis, Mosby, 1996, p 894
 75. Smith DF: Intussusception in adult cattle. *Compendium on Continuing Education for the Practicing Veterinarian* 11:S49, 1980
 76. Smith DF: Bovine intestinal surgery: part V. *Mod Vet Pract* 66:405, 1985
 77. Smith DF, Erb HN, Kalaher KM, et al: The identification of structures and conditions responsible for right side tympanitic resonance (ping) in adult cattle. *Cornell Vet* 72:180, 1982
 78. Smith DF, Munson L, Erb HN: Abomasal ulcer disease in adult dairy cattle. *Cornell Vet* 73:213, 1983
 79. Sockett DC, Conrd TA, Thomas CB, et al: Evaluation of four serological tests for bovine paratuberculosis. *J Clin Microbiol* 30:1134, 1992
 80. Spier SJ, Smith BP, Seawright AA, et al: Oak toxicosis in cattle in northern California: Clinical and pathologic findings. *J Am Vet Med Assoc* 191:958, 1987
 81. St.Jean G: Decision making in bovine abdominal surgery. *Vet Clin North Am Food Admin Pract* 6:335, 1990
 82. Stockhofe-Zurwieden N, Rehage J, Yalsin E: Morphological investigations of the forestomach in cows suffering from Hoflund syndrome. *Vet Rec* 1:127, 1999
 83. Sweeney RM, Divers TJ, Gillette DM, et al: Mycotic omasitis and rumenitis as sequelae to sepsis in dairy cattle: Six cases (1979-1986). *J Am Vet Med Assoc* 194:552, 1989
 84. Underwood WJ: Rumen lactic acidosis: part II. Clinical signs, diagnosis, treatment, and prevention. *Compendium on Continuing Education for the Practicing Veterinarian* 14:1265, 1999
 85. Van Metre DC, Fecteau G, House JK, et al: Indigestion of late pregnancy in a cow. *J Am Vet Med Assoc* 206:625, 1995
 86. van Miert ASJPAM: Fever, anorexia and forestomach hypomotility in ruminants. *Vet Res Commun* 11:407, 1987
 87. Whipple DL, Kapke PA, Andersen PR: Comparison of a commercial DNA probe test and three cultivation procedures for detection of *Mycobacterium paratuberculosis*. *J Vet Diagn Invest* 4:23, 1992
 88. Whitlock RH: Failure of omasal transport: Fact or fiction. *In* Proceedings of the 14th American College of Veterinary Medicine Forum, 1996, San Antonio, TX, pp 482-484
 89. Wilson AD, Hirsch VM, Osborne AD: Abdominocentesis in cattle: Technique and criteria for diagnosis of peritonitis. *Can Vet J* 26:74, 1985
 90. Zajac A: If your deworming program isn't working, it might be a fluke. *In* Proceedings of the North American Veterinary Conference 1994, Orlando, FL, p 719

Address reprint requests to

Ellen B. Belknap, DVM, MS
 Department of Large Animal Surgery and Medicine
 McAdory Hall
 Auburn University
 Auburn, AL 36849