

12-2014

## **Functional Morphology of the Connective Tissue of the Clavicular System of the Domestic Cat, *Felis catus***

Amanda N. Cooper

Follow this and additional works at: [https://digitalcommons.lsu.edu/honors\\_etd](https://digitalcommons.lsu.edu/honors_etd)



Part of the [Biology Commons](#)

---

**Functional Morphology of the Connective Tissue of the  
Clavicular System of the Domestic Cat, *Felis catus***

by

Amanda N. Cooper

Undergraduate Honors Thesis

Directed by

Dr. Dominique G. Homberger

Department of Biological Sciences

Louisiana State University and Agricultural & Mechanical College

Baton Rouge, LA 70803

December 2014

## Abstract

In her studies of the clavicular fascial system of the domestic cat, *Felis catus*, Osborn (2013) stated that connective tissue forming the superficial lamina of the clavicular fascial system surrounds muscle fiber fascicles of the *M. pectoralis superficialis* and traverses the entire muscle from its cranial border to its caudal border to anchor itself to the cutaneous fascia of the base of the tail. This study builds on Osborn's (2013) work and proposes a model that explains how the connective tissue fibers are oriented with respect to the fascicles of the *M. cleidobrachialis*. Connective tissue fibers form a three-dimensional latticework that comprises vertical and horizontal components. The latter are interleaved between layers of muscle fascicles and comprise three sets of parallel-fibered connective tissue sheets: One set is oriented perpendicularly to the muscle fascicles, and the other two sets are oriented crosswise and diagonally at approximately 45° with respect to the muscle fascicles. Some of the diagonal connective tissue fibers curve, thicken, align themselves with the muscle fascicles near the clavicular ligament, and pass between the overlying muscle fascicles, thereby forming the vertical component of the connective tissue latticework. This study contributes to a better understanding of the detailed fiber architecture and biomechanical role of the connective tissue surrounding the muscle fibers and fascicles.

## Introduction

The clavicle of the domestic cat, *Felis catus*, has historically been dismissed as an evolutionary remnant with no functional purpose (*e.g.*, Trotter, 1885). This small, easily overlooked bone is part of the clavicular ligament, is embedded within the pectoral musculature in the broad sense, and serves as an attachment site for the *M. cleidomastoideus* and for parts of the *M. cleidobrachialis* and *M. clavotrapezius* (*sive M. cleidocervicalis*) (Homberger and Walker, 2004). As part of an investigation of the morphological and functional macroevolutionary changes necessary for the transition from quadrupedalism to bipedalism, Osborn (2013) sought to understand why the clavicle of the cat is so small compared to its robust human counterpart. In doing so, she made an intriguing discovery: The clavicular ligament plays an integral role in the head suspension of the cat.

The existence of the clavicular ligament was documented almost 170 years ago by Straus-Dürckheim (1845). It originates from the anterior surface of the sternum and inserts on the acromion process of the scapula. This ligament ossifies at the location where the greatest amount of force is applied to it by the additional *M. cleidomastoideus*, thereby forming the structure that is conventionally known as the clavicle (Dr. Dominique G. Homberger, personal communication). Osborn (2013) discovered that the forces necessary to bring about the ossification of the ligament arise from the cranial pull of the contracting *M. cleidomastoideus*, which is, in turn, resisted by the caudal reaction force of the clavicular fascial system. This balanced force regime allows the cat to lower its head when the left and right *Mm. cleidomastoidei* contract.

Although components of the clavicular fascial system have been described previously (Straus-Dürckheim, 1845; Mivart, 1881; Sandstrom and Saltzman, 1944), Osborn (2013) was the first to provide an in-depth description paired with an integrated functional interpretation. The

clavicular fascial system consists of two main parts: The superficial and deep laminae, which originate caudo-ventrally from the clavicular ligament. The superficial lamina inserts along the entire sternum and passes caudally through the *M. pectoralis superficialis*. The deep lamina is more complex, comprising four portions. According to Osborn (2013), the sternal portion serves to anchor the clavicle to the body of the sternum and to the caudal angle of the scapula. The medial scapular portion is superficial to the *M. subscapularis* and the *M. teres major*, and it also connects the clavicle to the caudal angle of the scapula. The lateral scapular portion extends from the clavicle to the scapular spine and spinous process of the first thoracic vertebra. The humeral portion coalesces with the antebrachial fascia of the arm.

Although Osborn's (2013) study of the clavicular fascial system is unprecedented in its comprehensiveness, much remains to be learned about the connective tissue, specifically with regard to the manner in which it attaches to muscle (Dr. Dominique G. Homberger, personal communication). The superficial lamina of the clavicular fascial system branches into layers referred to as lamellae by Osborn (2013) as it enters the cranial border of the *M. pectoralis superficialis*, and these lamellae extend between the muscle fascicles, the smallest units of muscle that are visible without magnification (Homberger and Walker, 2004). Osborn (2013) does not explain how the connective tissue is oriented with regard to the muscle fascicles, stating only that it possesses parallel collagen fibers that encompass the muscle fascicles as a "meshwork". The goal of this study is to build upon Osborn's conceptual framework of the organization of connective tissue among muscle fascicles by offering a more thorough analysis of the structural and mechanical roles of the connective tissue that is associated with the *M. cleidobrachialis*.

## Materials and Methods

One cat specimen (ID number F13G2) was originally obtained from the National Agricultural Supply Company (NASCO, Fort Atkinson, WI) and has been in the collection of Dr. Dominique G. Homberger as part of the Comparative Anatomy Teaching Lab. The cat was preserved originally in a solution of 3.7% formaldehyde and propylene glycol by NASCO and stored briefly in a 1% 2-phenoxyethanol solution in order to soften the tissues. It was then stored in a 4% formalin solution. The skin was removed, and the muscles of the left side were dissected by the author in collaboration with her lab partner in the fall semester of 2013 as part of the laboratory component of the comparative anatomy course (BIOL 3152) taught by Dr. Homberger.

For the current project, the specimen was dissected under a Wild M3 (Heerbrugg, Switzerland) stereomicroscope at magnifications of 6.4x, 16x, and 40x. The light source was a Volpi Intralux 6000 (Auburn, NY) light box, which was connected to the stereomicroscope *via* a fiber optic cable with an adjustable polarized ring light. Stainless steel watchmaker forceps from VWR International (Radnor, PA), which were sharpened at 40x magnification with a novaculite whetstone from Dan's Whetstone Company (Pearcy, AR), were used to dissect the specimen.

The dissection involved the removal of the most superficial layer of fascia in order to mobilize individual muscle fascicles. Beginning at the medial borders of the *M. cleidobrachialis* and *M. clavotrapezius*, the muscle fascicles were bisected and reflected one at a time so that the underlying fascia layer could be observed, a technique that was also used by Osborn (2013). The origin of some fascicles of the *M. cleidobrachialis* from the clavicular ligament was severed so that these muscle fascicles could be reflected in order to examine the connection of deeper fascicles to the clavicular ligament, which was hidden by the more superficial fascicles. The connection of the superficial fascicles to the clavicular ligament could not be observed because

the tendons of the muscle fascicles broke before they could be traced to the deep clavicular ligament, unlike the tendons of the deeper fascicles, which were more level with the clavicular ligament.

Images of the various steps of the dissection were taken at magnifications of 6.3x, 20x, 25x, or 30x using a Leica MZ6 (Heerbrugg, Switzerland) stereomicroscope and a SPOT Insight FireWire camera from Diagnostic Instruments (Sterling Heights, MI). The specimen was illuminated in a dark room with a Volpi Intralux 6000 (Auburn, NY) light box to which two fiber optic cables with polarizers were attached. Another polarizer, which served as an analyzer, was attached to the objective lens. The stereomicroscope, the camera, the fiber optic cables, and the specimen were placed on a Micro-g isolation table from Technical Manufacturing Corporation (Reabody, MA), which used nitrogen to stabilize the platform. The Micro-g table was essential for preventing vibrations in the building from causing blurred images or variations in the illumination of the specimen. As preparation for some photographs, the specimen was stained with a 5% Lugol's iodine solution. By binding to the glycogen of the muscle cells, the iodine stained the muscle fascicles red-brown and the connective tissue yellow, thereby creating a greater contrast between the muscle fascicles and the connective tissue fibers (Bock and Shear, 1972).

Images were previewed in real time and processed with Image-Pro software from Media Cybernetics (Bethesda, MD). They were captured either by taking a snapshot or with the Extended Depth of Field (EDF) method, wherein a series of images were taken with the InFocus software program (Infocus Corporation, Portland, OR) and then combined with Image-Pro to create an image in which all elements are in focus. In order to accomplish this, the camera was first focused on the lowest point of the specimen, which was entered into the InFocus software as

a minimum value, and then focused on the highest point of the specimen, which was entered as a maximum value. The resultant sequence of photographs was then integrated in Image-Pro.

In order to add a scale to the images, each image was retaken with a metric ruler placed near the region of interest at the same magnification at which the original image was taken. The size of individual structures was also assessed by calibrating the tick marks of a graticule located in one of the oculars of the stereomicroscope with a high-precision glass scale (Wild, Heerbrugg, Switzerland) that was placed on the specimen near the region of interest. When viewed under the microscope, the etched tick marks of the precision glass scale (spaced 0.01 mm apart) were manually lined up with the tick marks of the ocular graticule to determine the actual distance between the ocular graticule tick marks at particular magnifications.

For final processing of the images, a scale was added, and individual structures were labeled with Adobe Illustrator (San Jose, CA). In one image, the connective tissue fibers were traced with colored lines in Illustrator in order to highlight the collagen fiber bundles. Fully labeled, the finalized images were then opened in Adobe Photoshop (San Jose, CA), where they were saved as TIFF files. The images were resized with PaintShop Pro (Corel Corporation, Ottawa, Ontario) or Photoshop and pasted into Microsoft Word (Microsoft Corporation, Redmond, WA). The figure captions were written in Microsoft Word.

In addition, diagrams of the structures seen during the dissection were created to supplement the mesoscopic images. The diagrams were scanned and cropped, and unnecessary lines or smudges were removed *via* the Paint Brush tool in PaintShopPro. The retouched images were then labelled or had supplemental lines inserted (as was the case with the diagram in Fig. 4, where the added lines represent connective tissue fibers) in Adobe Illustrator. The images were resized in PaintShopPro or Photoshop and inserted into Microsoft Word, with figure captions added in Microsoft Word.



## Results

The *M. cleidobrachialis* and the *M. clavotrapezius* of the cat originate from the clavicular ligament, which attaches its ossified portion (*i.e.*, the clavicle) to the sternum and the acromion process of the scapula. The *M. cleidobrachialis* inserts on the ulna, and the *M. clavotrapezius* inserts on the nuchal crest of the skull. Hence, the clavicular ligament establishes the border between the *M. cleidobrachialis* and the *M. clavotrapezius* (Fig. 1). These two muscles are traditionally conceptualized as the *M. brachiocephalicus* (Homberger and Walker, 2004), which is, however, more accurately used only for the superficial muscle fascicles that are continuous from the nuchal crest to the ulna and pass over the clavicular ligament without attaching to it.

The medial portion of the clavicular ligament was seen as a band of uniform width that was composed of distinct, tough connective tissue fiber bundles. It was oriented obliquely from caudo-medial to cranio-lateral and passed externally to the ossified clavicle. It comprised two parallel bands, and the cranio-lateral band bifurcated to create a total of three visible bands. The fascicles of the *M. cleidobrachialis* were attached to the caudo-medial band of the clavicular ligament *via* short tendons that curved cranio-medially and joined the clavicular ligament (Figs. 2 and 3).

The *M. cleidobrachialis* and the *M. clavotrapezius* are parallel-fibered. Although they are not arranged in clearly defined layers, the fascicles of both muscles consist of rows that can be reflected as a group. Therefore, the muscle fascicles can be described as superficial or deep with respect to one another. In both muscles, connective tissue fibers surround each muscle fascicle (Fig. 4), thereby interconnecting individual muscle fascicles to one another and to connective tissue layers.

This three-dimensional lattice comprises two parts (Fig. 4): (1) A network of connective tissue fibers between layers of muscle fascicles composed of one set of perpendicular fibers and

two sets of diagonal fibers; and (2) connective tissue fibers originating from this network and travelling between layers of muscle fascicles. One set of the connective tissue fibers of the network between the layers of muscle fascicles was oriented almost perpendicularly relative to the muscle fascicles (traced in green lines in Fig. 5A). Other connective tissue fibers within this network were oriented diagonally at approximately 45° with respect to the muscle fascicles (traced in yellow and blue in Fig. 5B). Some of these diagonal connective tissue fibers became tougher, thicker, and more like ligaments (traced in yellow in Fig. 5B) and changed their orientation to a more parallel alignment with respect to the muscle fascicles as they approached the clavicular ligament. The connective tissue ligaments were 100 µm thick and comprised multiple smaller collagen fiber bundles approximately 10 µm thick, which had coalesced to form the ligaments.

In the *M. clavotrapezius*, these parallel ligaments were traced from the external surface of deep muscle fascicles to the internal surface of overlying muscle fascicles (Fig. 6A). The collagen fiber bundles of the ligaments spread out again upon reaching the internal surface of the overlying muscle fascicles. One ligament fanned out into collagen fiber bundles that passed between two superficial fascicles of the *M. clavotrapezius* (Fig. 6B).

## Discussion

The clavicular ligament of specimen F13G12 most closely resembles the descriptions by Straus-Dürckheim (1845) and Mivart (1881), who stated that the ossified clavicle is contained within a ligament that inserts medially onto the anterior portion of the sternum and laterally onto the acromion process of the scapula. Osborn (2013) found that the clavicular ligament is not an isolated structure, but instead a part of the clavicular fascial system. She stated that the medial attachment of the ligament to the sternum forms the cranial border of the sternal portion of the deep lamina of the clavicular fascial system.

Osborn (2013) did not describe the clavicular ligament in its entirety, however, because of her particular research question. Because she wished to conceptualize the fasciae that serve to resist the cranial force of the contracting *M. cleidomastoideus*, Osborn (2013) focused on the underside of the *M. cleidobrachialis*, where the clavicular fascial system can be traced most effectively. My own study, however, sought to understand the organization of the connective tissue within the muscle. Therefore, I approached the *M. cleidobrachialis* from its surface, thereby being able to reveal the superficial portion of the clavicular ligament.

None of the earlier studies described how the fascicles of the *M. cleidobrachialis* originate from the clavicular ligament. The present study emphasizes that the muscle fascicles do not attach directly to the ossified clavicle, but to the clavicular ligament, which passes superficially to the clavicle.

This study also provides evidence for the mechanism of ossification of the clavicle within the clavicular ligament as a result of the forces generated by the contraction of the muscles that originate from the ligament. The fact that the lateral portion of the *M. cleidobrachialis* is composed of fewer muscle fascicles is consistent with their origin from the portion of the clavicular ligament that does not ossify due to a smaller force acting on it. The portion of the *M. cleidobrachialis* that originates from the ossified portion of the clavicular ligament comprises more layers of muscle fascicles, thereby generating a greater force that contributes to the ossification of the clavicular ligament.

The three-dimensional latticework of connective tissue fibers holds the muscle fascicles together. The orientation of the muscle fascicles within the *M. cleidobrachialis* and the *M. clavotrapezius* allows the muscle fascicles to be conceptualized as being organized in horizontal rows and vertical layers. Osborn (2013) hinted at the complex structural organization of the connective tissue by stating that the connective tissue fibers form a meshwork around the muscle

fascicles. This study has augmented Osborn's (2013) observations by describing in greater detail how the connective tissue fibers are organized to anchor the muscle fascicles both horizontally and vertically.

Because the muscle fascicles of the *M. cleidobrachialis* originate from the clavicular ligament *via* curving tendons (as opposed to tendons that are perpendicular to the ligament), a medial force vector is created when the fascicles contract. The perpendicular connective tissue fibers and the sets of connective tissue fibers that are oriented at 45° with respect to the longitudinal axis of the muscle fascicles hold the rows of fascicles together so that they are not pulled apart. The vertically oriented connective tissue fibers that arise from these horizontal connective tissue networks serve to connect layers of superficial and deep muscle fascicles to one another. These connective tissue fibers likely travel superficially beyond the muscle fascicles, where they adhere the muscle to the superficial fascia and to the dermis of the skin. Without these vertical connective tissue fibers, an action as ordinary as pulling on the skin would cause the rows of muscle fascicles to separate.

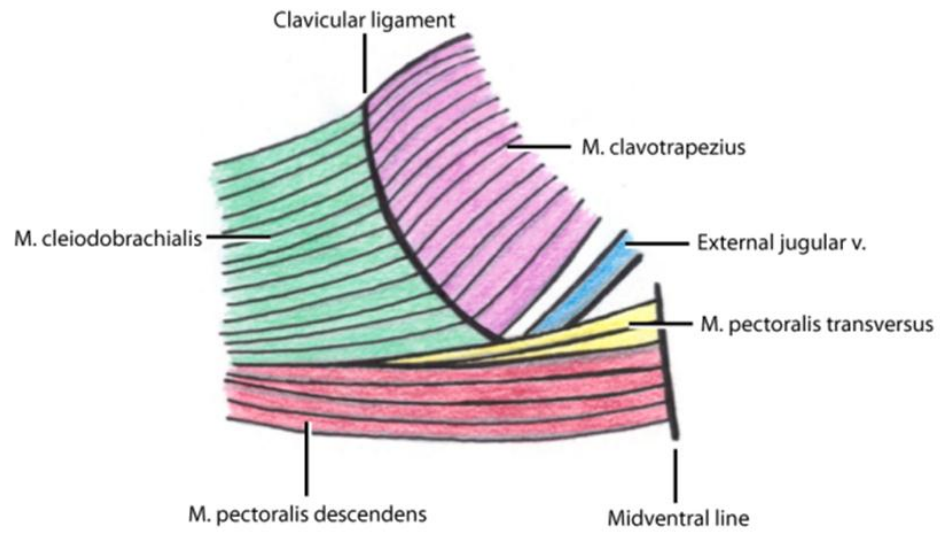
### **Acknowledgements**

I would like to thank Dr. Dominique Homberger for her mentorship, for helping me to develop my ideas, and for her supervision of this project, which would not have been possible without her instruction. Dr. Amanda Cozic provided technical assistance, and I am thankful that she and Bradley Wood made time for my questions. Sigrid Hamilton helped me by procuring references and other documents. Monique Matherne aided in the removal of the skin of the cat and the muscle dissection in the fall of 2013 as part of BIOL 3152. I also thank my committee members, Dr. Hermann Bragulla and Dr. Kyle Harms, for serving on my Honors Thesis Committee.

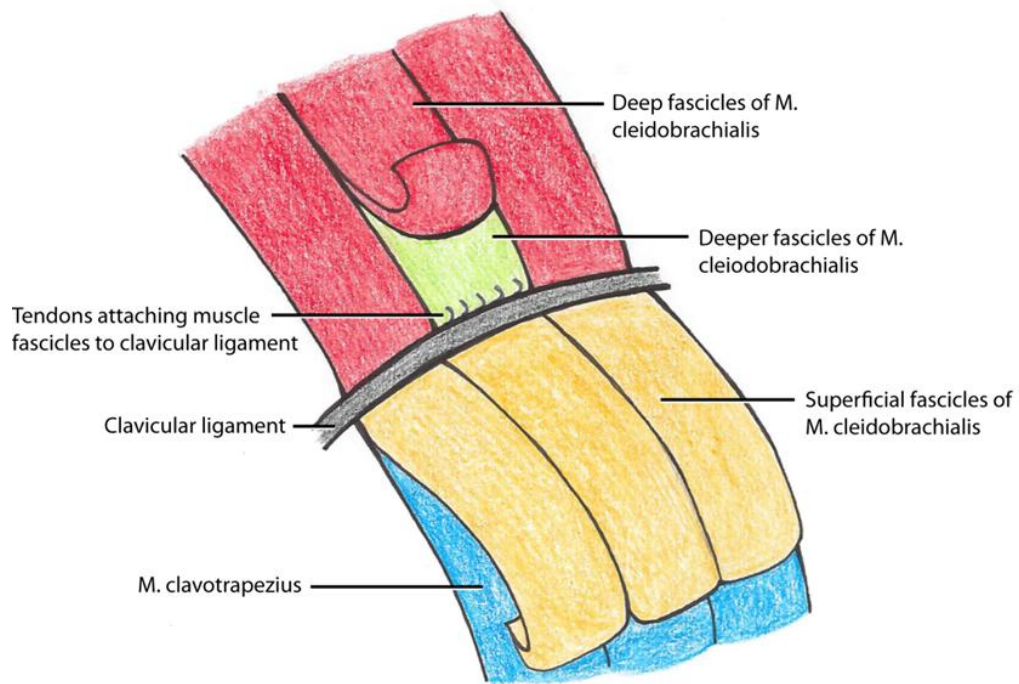
## Literature Cited

- Bock, W.J. and Shear, C.R. 1972. A staining method for gross dissection of vertebrate muscles. *Anatomischer Anzeiger*, 130: 222-227.
- Homberger, D.G. and Walker, W.F. 2004. *Vertebrate Dissection*. 9<sup>th</sup> Ed. Belmont, CA: Brooks/Cole-Thomson Learning.
- Mivart, St. G. 1881. *The Cat: An Introduction to the Study of Backboned Animals, Especially Mammals*. London: John Murray. Retrieved on Dec. 2, 2014 from <https://archive.org/stream/a5929989000mivauoft#page/n0/mode/2up>
- Osborn, M.L. 2013. *The Shoulder Suspension of Bipedal Humans and the Head Suspension of Quadrupedal Cats: A Reconstruction of Macroevolutionary Changes of Complex Systems Based on Natural Experiments, Comparative Anatomy, and Biomechanical Analyses of Extant Organisms*. Ph.D. Dissertation, Department of Biological Sciences, Louisiana State University, Baton Rouge. Retrieved on Dec. 2, 2014 from <http://etd.lsu.edu/docs/available/etd-04112013-203731/unrestricted/Osborn-diss-130417.pdf>
- Sandstrom, C.J. and Saltzman, A. 1944. A comparative study of the clavicular ligaments of the rat, rabbit, cat, and dog. *The Anatomical Record*, 89 (1): 23-32.
- Straus-Dürckheim, H. 1845. *Anatomie Descriptive et Comparative Du Chat, Type des Mammifères en Général et des Carnivores en Particulier*. Paris, France: Chez l'auteur.
- Trotter, S. 1885. The significance of the "collar bone" in the Mammalia. *The American Naturalist*, 19: 1172-1177.

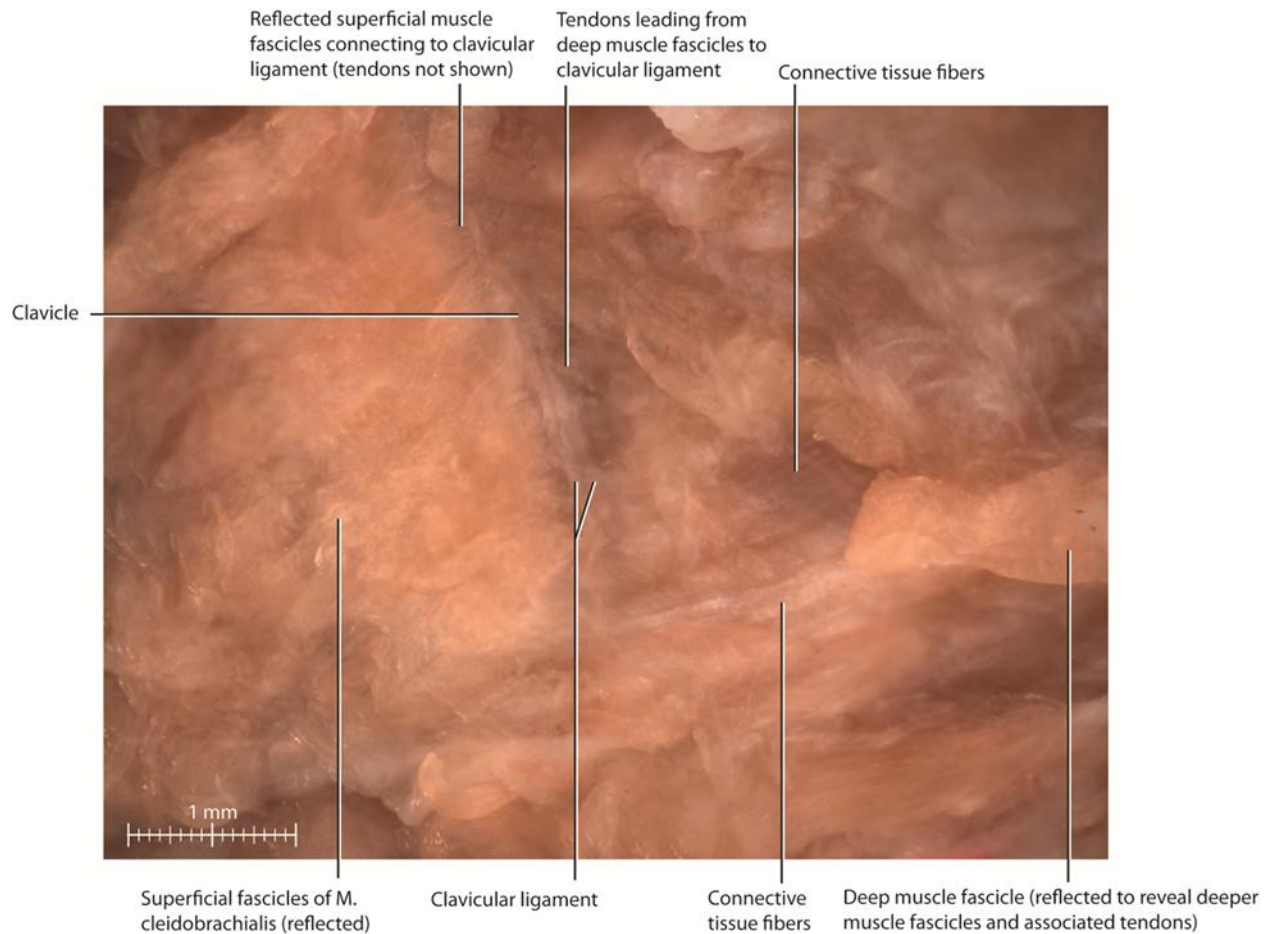
## Figures



**Fig. 1:** Diagram showing the orientation of the *M. cleidobrachialis* and the *M. clavotrapezius* with respect to the clavicular ligament of the domestic cat (*Felis catus*).

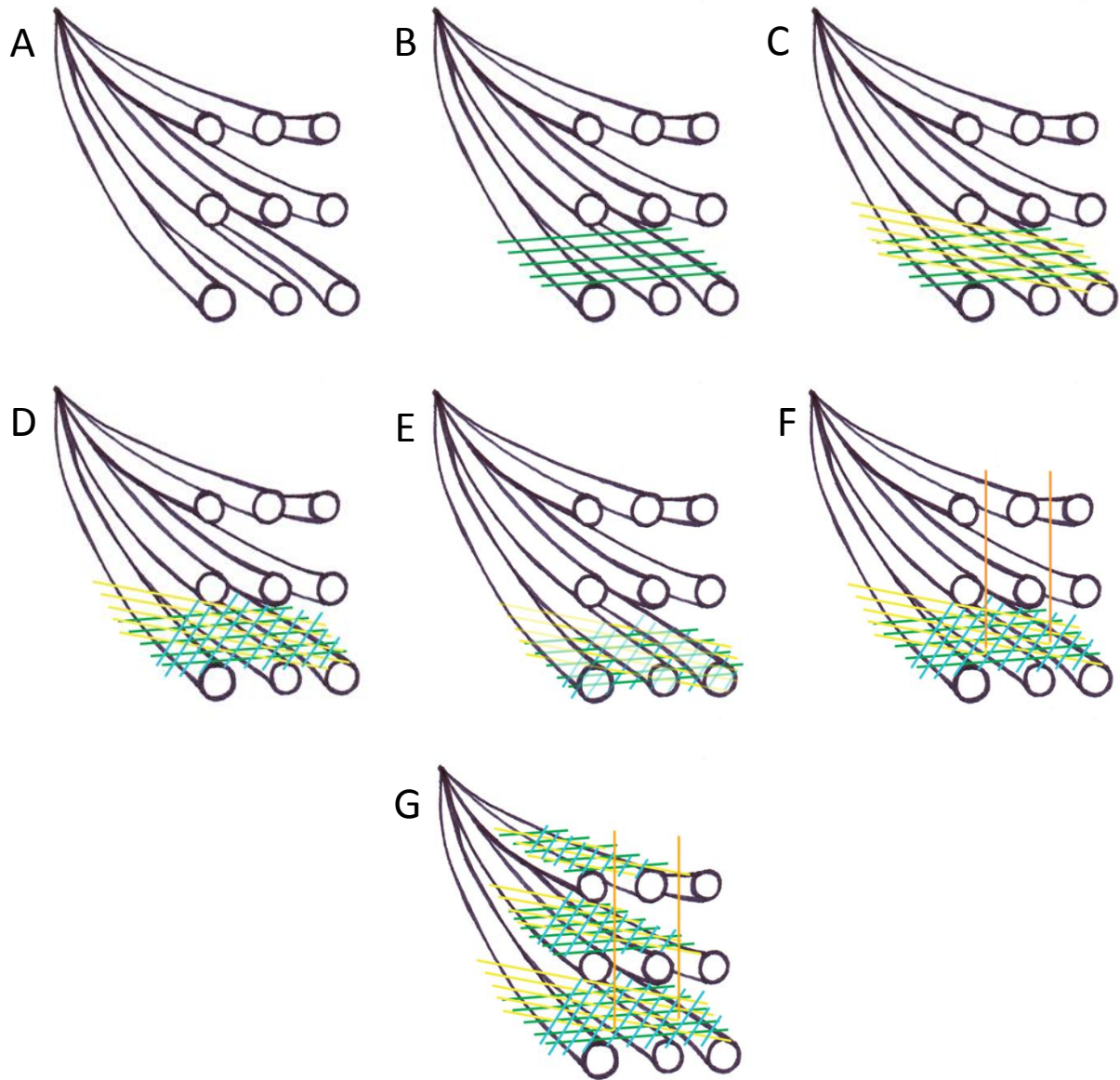


**Fig. 2:** Diagram showing how the fascicles of the right *M. cleidobrachialis* of the domestic cat (*Felis catus*) were reflected in order to examine the attachments of the deeper muscle fascicles to the clavicular ligament *via* tendons. Medial is on the left, and cranial is down.

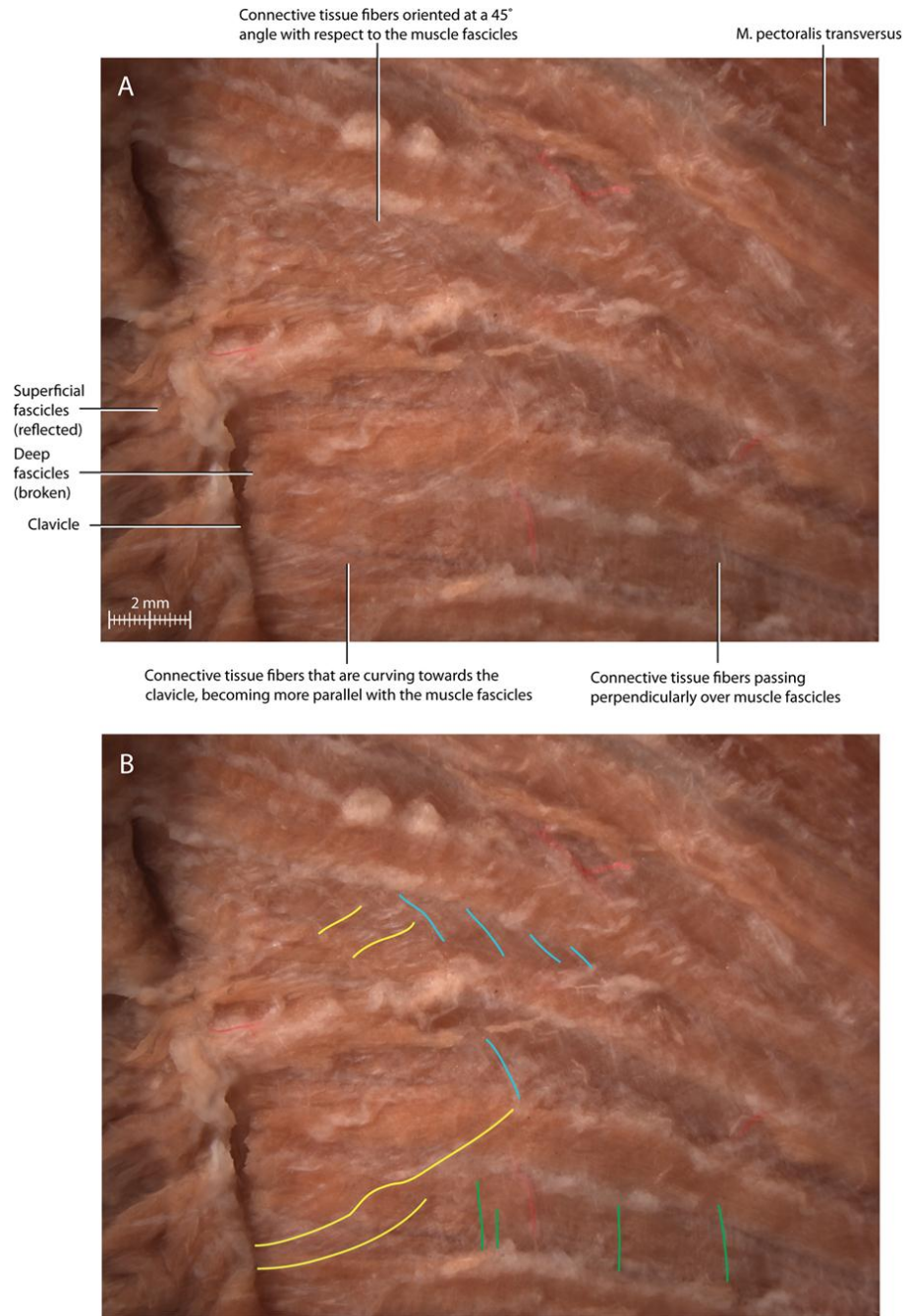


**Fig. 3:** External view of the fascicles of the right *M. cleidobrachialis* and part of the clavicular ligament of the domestic cat (*Felis catus*). A set of muscle fascicles was reflected to reveal a portion of the clavicular ligament. A deeper set of fascicles was reflected to reveal the next deeper set of muscle fascicles that were attached to the clavicular ligament by tendons. The image was taken at 20x magnification with an exposure time of 900 ms. An EDF image was created from 9 frames spaced 350  $\mu$ m apart with a total thickness of 2.631 mm.

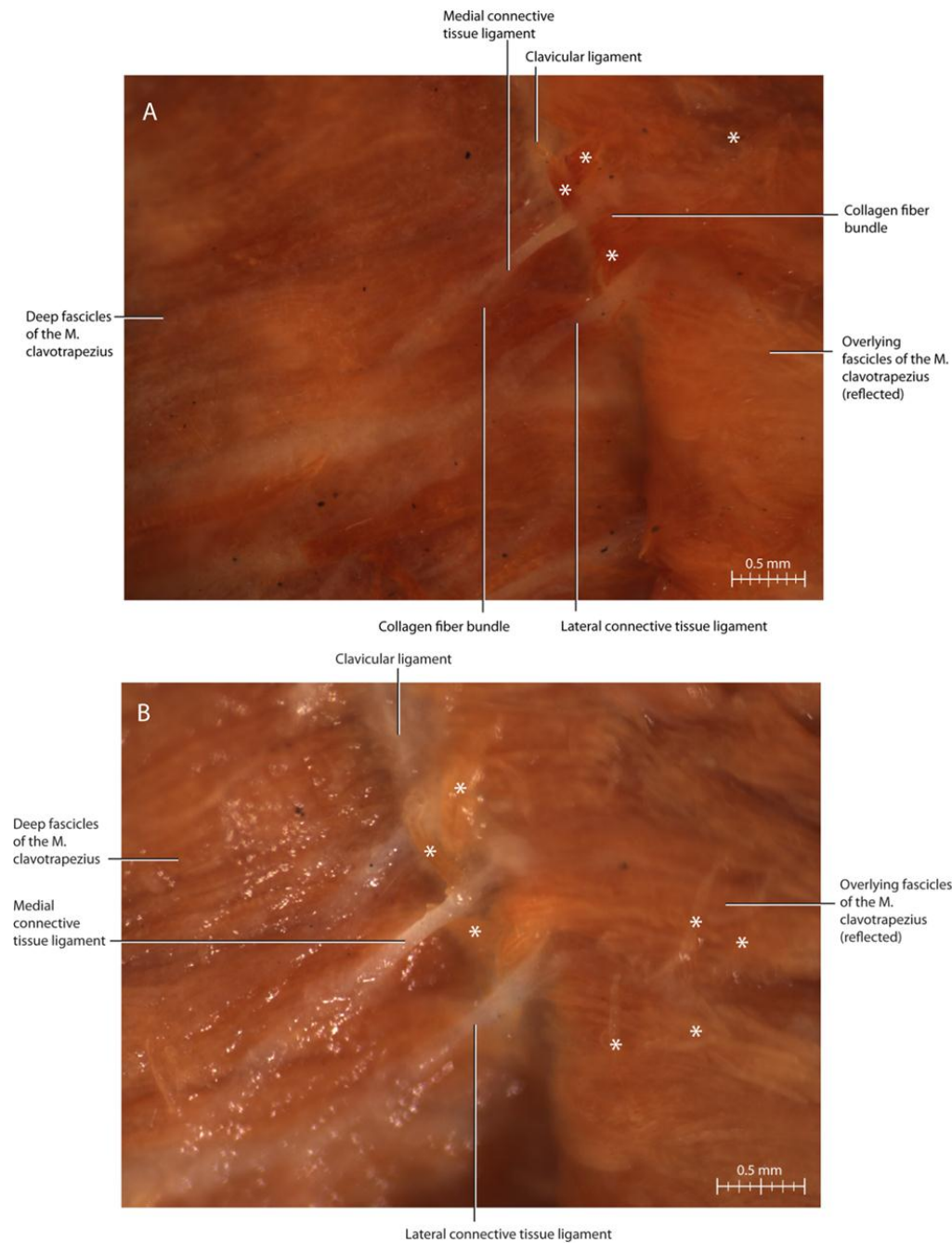




**Fig. 4:** Diagram showing the three-dimensional latticework of the connective tissue fibers with respect to the fascicles of the *M. cleidobrachialis* of the domestic cat (*Felis catus*). **(A)** The muscle fascicles without any connective tissue fibers. **(B)** One set of connective tissue fibers (green) is oriented perpendicularly with respect to the muscle fascicles. **(C)** One set of connective tissue fibers (yellow) is oriented at a 45° angle with respect to the longitudinal axis of the muscle fascicles. **(D)** Another set of connective tissue fibers (blue) is oriented at a 45° angle with respect to the muscle fascicles, forming the horizontal network of connective tissue fibers. **(E)** The underside of the muscle fascicles is covered by a connective tissue network as well. **(F)** Some connective tissue fibers (orange) travel upwards between two overlying fascicles. **(G)** An integrated view showing how each row of muscle fascicles is covered by a connective tissue network.



**Fig. 5:** External view of the right *M. cleidobrachialis* of the domestic cat (*Felis catus*) after reflection of some superficial muscle fascicles to show the orientation of fibers forming the connective tissue network between layers of muscle fascicles. The image was taken at 6.3x magnification with an exposure time of 1.2 s; the EDF image was created from 20 frames spaced 500  $\mu\text{m}$  apart with a total thickness of 9.337 mm. Cranial is on the left side. **(A)** One set of connective tissue fibers is oriented perpendicularly relative to the muscle fascicles, and two diagonal sets are oriented at about 45° with respect to them. One of these sets aligns itself with the muscle fascicles near the clavicular ligament. **(B)** Same image as in (A) but with connective tissue fibers traced in color. Colors: Green = perpendicular connective tissue fibers; blue = diagonal connective tissue fibers; yellow = diagonal connective tissue fibers.



**Fig. 6:** External view of the right *M. clavotrapezius* of the domestic cat (*Felis catus*) showing the formation of the connective tissue ligaments from smaller, curving collagen fiber bundles, which re-emerge from the ligaments to spread out onto the internal surface of the overlying fascicles. The specimen was stained with iodine, and the black spots are iodine crystals. Cranial is on the left side. (A) The collagen fiber bundles of the medial tendon appear to be continuous with the connective tissue lining the underside of the muscle fascicle. The image was taken at 25x magnification with an exposure time of 1.3 s. The EDF image was created from 4 frames spaced 500  $\mu\text{m}$  apart with a total thickness of 1.280 mm. (B) The collagen fiber bundles of the lateral tendon pass between two overlying fascicles. The image was taken at 32x magnification with an exposure time of 1.8 s. Symbols: \* = torn and displaced muscle fibers.